SonoPath
Clinical Sonography & Telecytology
EDUCATIONAL TELECONSULTATION SERVICES™
1-800-838-4268 info@sonopath.com SonoPath.com

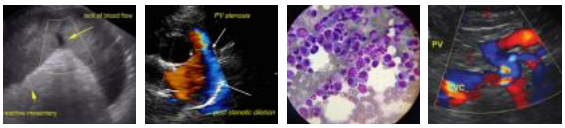

ANIMAL SOUNDS NW
MOBILE VETERINARY ULTRASOUND
IMAGING PERFORMED BY
AnimalSoundsNW.com 541-357-9423

PATIENT

Avery Hart

SPECIES

Canine

BREED

Blue Heeler

SEX

Spayed Female

AGE

12 Weeks

WEIGHT

17.8 Pounds

INTERPRETED BY

Eric Lindquist, DMV, DABVP, Cert. IVUSS

HOSPITAL NAME

Santa Clara AH

REFERRING VET

Dr. Zulauf

INVOICE NUMBER

16544

DATE

7/8/22

PRESENTING CLINICAL SIGNS

History: They were previously diagnosed with as a hermaphrodite and spayed at another clinic. I will send the records for this Pt presented for urinary incontinence on 6/14/22 and diagnosed with a UTI by UA and treated with antibiotics. Pt presented again for continued urinary incontinence and the new UA doesn't show any sign of infection

Abnormal PE/Chem/CBC/UA Results: AUS - large tubular, fluid fill structure in abdomen. It was sampled during previous visit and clear fluid was obtained. r/o hydrometra, ectopic ureter, etc

ULTRASONOGRAPHIC EXAMINATION OF THE ABDOMEN

Urinary System

The **urinary bladder**, trigone, and pelvic urethra presented normal thicknesses and normal tone. The ureters were not visible which is normal. No uroliths or sediment were visualized, and anechoic urine was present. No evidence of inflammatory or neoplastic changes were noted. Ureteral papillae were normal.

The **right kidney** was normal in size and contour with trace pyelectasia. The right kidney measured 7.76 cm

*A separate kidney was imaged, however, appears to be in improper position or a separate angle taken to the right kidney. An adjacent tubular structure was noted, occupying the caudal abdomen and entering into the pelvis between the bladder and the colon was noted. Concern for ectopic ureter and ectopic left renal placement. I cannot completely rule out the possibility of residual uterine tubular dilation.

Adrenal Glands

Both **adrenal glands** were visualized and recognized as having normal shape, size, position and echogenicity for this breed. The phrenic vasculature, glandular echogenicity and detail were unremarkable. Capsule, cortex, and medullary definition were normal for this age patient. The right adrenal gland measured 1.83 cm x 0.8 cm at the caudal pole and 0.69 cm at the cranial pole.

Spleen

The **spleen** presented a smooth homogeneous parenchyma hyperechoic to liver and renal cortical parenchyma. The capsule was smooth without noticeable expansion or deviation from within the spleen or adjacent pathology. The splenic vasculature demonstrated normal volume without signs of congestion or thrombosis. No sonographic evidence of acute or chronic inflammatory, neoplastic, or infarctual changes were noted.

Liver

The **liver** images submitted revealed subjectively normal liver size, contour, and structure. Parenchymal echogenicity was naturally coarse and hypoechoic to the spleen. Vascular and biliary tracts were of normal volume with no evidence of congestion. The gallbladder presented acceptably thin walls with primarily anechoic content. The cystic and common bile ducts were normal. No pathological hepatic lymphadenopathy was evident. No overt structural evidence of inflammatory, infiltrative or regenerative pathology was evident.

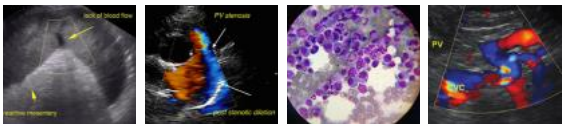

PATIENT

Avery Hart

SPECIES

Canine

BREED

Blue Heeler

SEX

Spayed Female

AGE

12 Weeks

WEIGHT

17.8 Pounds

INTERPRETED BY

Eric Lindquist, DMV, DABVP, Cert. IVUSS

HOSPITAL NAME

Santa Clara AH

REFERRING VET

Dr. Zulauf

INVOICE NUMBER

16544

DATE

7/8/22

Gastrointestinal

Examination of the **gastrointestinal tract** revealed a stomach and intestine free of stasis, of normal wall thickness, acceptable curvilinear mural detail, and peristaltic activity. Small and large intestine demonstrated normal luminal chyme and stool consistency respectively. No obstructive or overt infiltrative disease was noted. No associated abnormal lymphatic activity was noted.

Pancreas

The base and limbs of the **pancreas** were observed to be largely isoechoic to surrounding omental fat. Pancreatic duct and capsular contour were acceptably normal and parenchyma respected normal curvilinear patterns. No overt evidence of active inflammatory or neoplastic disease was noted.

ULTRASONOGRAPHIC FINDINGS

- A separate kidney was imaged, however, appears to be in improper position or a separate angle taken to the right kidney. An adjacent tubular structure was noted, occupying the caudal abdomen and entering into the pelvis between the bladder and the colon was noted. Concern for ectopic ureter and ectopic left renal placement. I cannot completely rule out the possibility of residual uterine tubular dilation.

INTERPRETATION OF THE FINDINGS & FURTHER RECOMMENDATIONS

I recommend CT with contrast in this patient for further surgical planning or IVP to further define the urinary tract. It is possible that the second kidney that I'm evaluating is the right kidney and left renal aplasia may be an issue. VD abdominal radiographs are recommended to ensure that both kidneys are present.

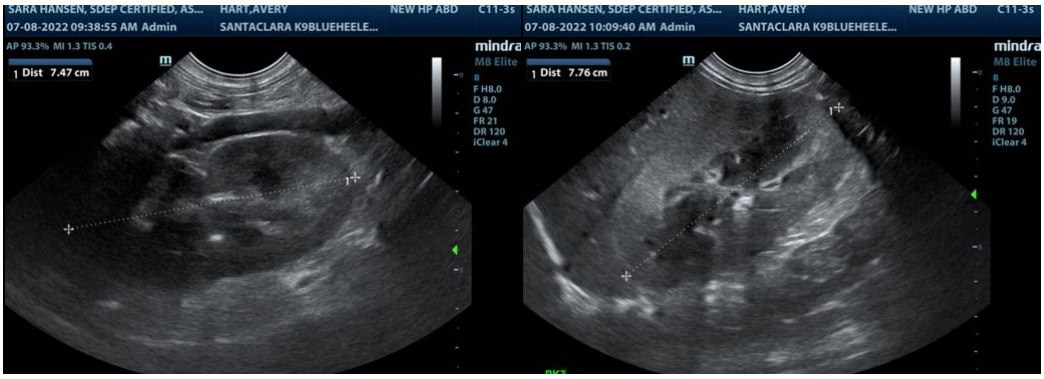

SonoPath
Clinical Sonography & Telecytology

EDUCATIONAL TELECONSULTATION SERVICES™
1-800-838-4268 info@sonopath.com SonoPath.com

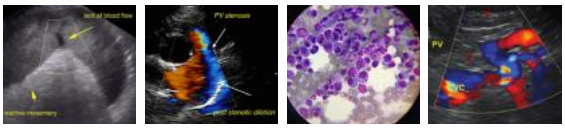

ANIMAL SOUNDS NW
MOBILE VETERINARY ULTRASOUND

IMAGING PERFORMED BY
AnimalSoundsNW.com 541-357-9423

PATIENT

Avery Hart

SPECIES

Canine

BREED

Blue Heeler

SEX

Spayed Female

AGE

12 Weeks

WEIGHT

17.8 Pounds

INTERPRETED BY

Eric Lindquist, DMV, DABVP, Cert. IVUSS

HOSPITAL NAME

Santa Clara AH

REFERRING VET

Dr. Zulauf

INVOICE NUMBER

16544

DATE

7/8/22

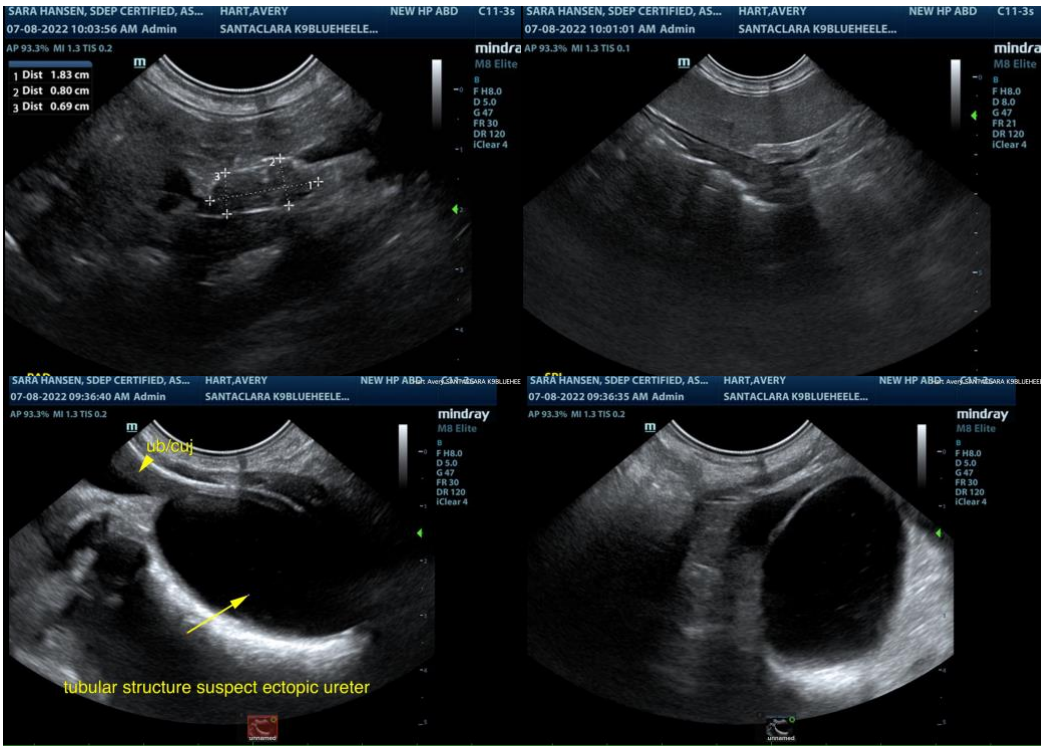

The information and recommendations provided are based on the images presented by the referring veterinarian. No evaluation can be communicated regarding pathology that was not visible in the image/video clips provided.

Thank you for this referral. If the clinical or image interpretation does not parallel your findings or if I can be of any further assistance please contact me.

Eric Lindquist, DMV, DABVP, Cert. IVUSS, CEO of SonoPath.com
Eric.Lindquist@SonoPath.com