



PATIENT PRESENTING CLINICAL SIGNS

Zoey Madsen History: recheck from yesterday

SPECIES ULTRASONOGRAPHIC EXAMINATION OF THE ABDOMEN

Canine

Gastrointestinal

BREED

Poodle Mix

The stomach was empty in this patient. No further residual foreign matter was noted. The small intestine was empty with normal curvilinear patterns present. The transverse colon was full.

SEX

Spayed female

ULTRASONOGRAPHIC FINDINGS

Normalized GI tract with full transverse colon.

AGE

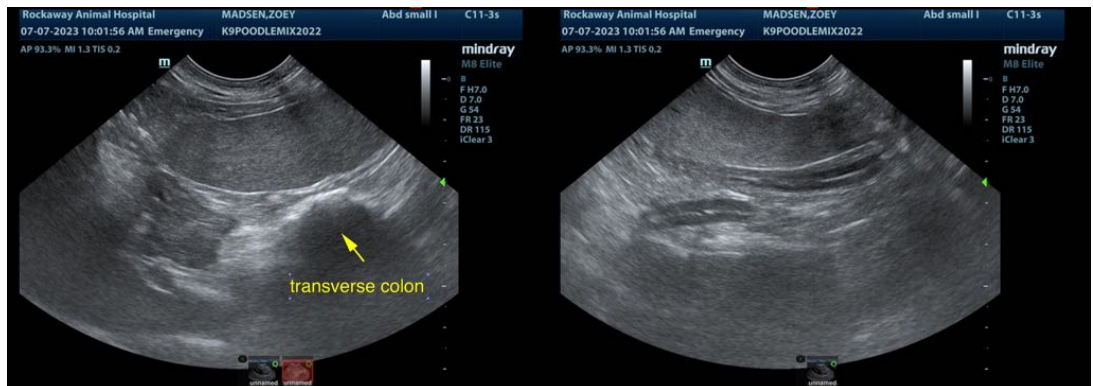
1 year

INTERPRETATION OF THE FINDINGS & FURTHER RECOMMENDATIONS

The foreign matter may have been evacuated or in the colon, yet no obstructive disease was noted.

WEIGHT

41.5 lbs



INTERPRETED BY

Eric Lindquist, DMV
DABVP, Cert. IVUS

IMAGING PERFORMED BY

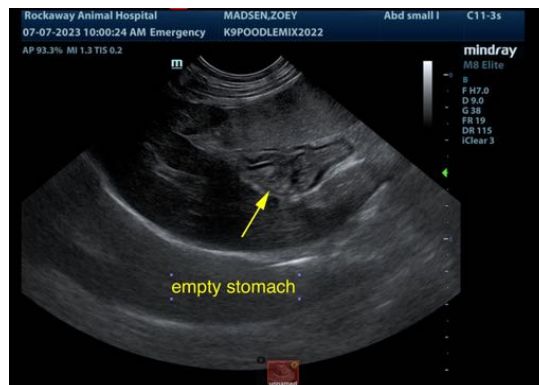Jenn

HOSPITAL NAME

Rockaway AH

REFERRING VET

Dr. Maniar



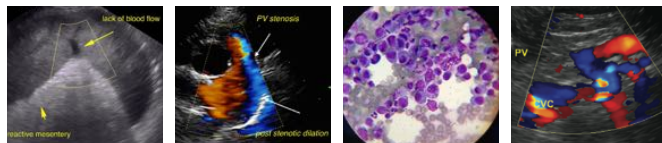
INVOICE

75946

DATE

7/7/23

The information and recommendations provided are based on the images presented by the referring veterinarian/sonographer. No evaluation can be communicated regarding pathology that was not visible in the image/video clips provided.



PATIENT

Zoey Madsen

Thank you for this referral. If the clinical or image interpretation does not parallel your findings or if I can be of any further assistance please contact me.

SPECIES

Canine

Eric Lindquist, DMV, DABVP, Cert. IVUSS, CEO of SonoPath.com
info@SonoPath.com

BREED

Poodle Mix

SEX

Spayed female

AGE

1 year

WEIGHT

41.5 lbs

INTERPRETED BY

Eric Lindquist, DMV
DABVP, Cert. IVUSS

**IMAGING
PERFORMED BY**

Jenn

HOSPITAL NAME

Rockaway AH

REFERRING VET

Dr. Maniar

INVOICE

75946

DATE

7/7/23