



PATIENT PRESENTING CLINICAL SIGNS

Zeus Henry History: Ascites- mod. transudative Current meds: Lasix

SPECIES ULTRASONOGRAPHIC EXAMINATION OF THE HEART & ABDOMEN

Canine

BREED

Pit Mix

SEX

Neutered Male

AGE

9 Years

WEIGHT

70 Pounds

CANINE CARDIAC PARAMETERS	MR VMAX (m/s)	TR VMAX (m/s)	LA/AO (Boon method)	LA/AO (Heart Base; Swe)	FS (%)	EF (%)	EPSS (cm)
NORMAL PARAMETER	4.5-5.5	<2.7	1.3	<1.3	28-40	40-100	<0.6
PATIENT		1.26	1.1	1.04			0.1
CANINE CARDIAC PARAMETERS	HR (BPM)	AV VMAX (m/s)	PV MAX (m/s)	BODY WEIGHT (kg)	LA 2D short axis Base view (cm)	LVIDd Avg; 2D and m-mode short axis (cm)	LVIDs Avg; 2D and m-mode short axis (cm)
NORMAL PARAMETER	50-100	0.7-1.7	0.7-1.6				
PATIENT		1.20	.70	--	3.6		--

Cardiac Presentation

The echocardiogram in this patient demonstrated normal **left atrial** size based on 3 separate methods of LA evaluation. The cranial and caudal **mitral** valve leaflets presented normal linear structure, extension in systole, and union in diastole with normal kinesis. The **left ventricle** presented thicknesses with linear contour and was not dilated nor restricted. The **myocardium** presented normal echogenicity without subjective evidence of significant fibrotic or ischemic disease. **Contractility** of the ventricular walls was adequate and in normal range for this patient evidenced by the fractional shortening measurement and subjective evaluation of the different regions of the myocardium. The **left ventricular outflow** tract demonstrated normal laminar flow and subjective structural integrity. The **right atrium** and auricle revealed normal size, structure and content. No evidence of masses was noted. Tricuspid insufficiency was noted, minor. The **right ventricle** was of normal size (1/3 diameter of LV), chordae structure, myocardial echogenicity and thickness. **Pulmonary outflow** tract assessment revealed normal valve structure, laminar flow, and diameter (approx. 1:1 pa/ao ratio). A 6.6 cm x 5.4 cm hypochoic mass was noted, occupying the right atrium, obstructing vena cava inflow.

Urinary System

The **urinary bladder**, trigone, and pelvic urethra presented normal thicknesses and normal tone. The ureters were not visible which is normal. No uroliths or sediment were visualized and anechoic urine was present. No evidence of inflammatory or neoplastic changes were noted. Ureteral papillae were normal. The pelvic urethra was imaged 3.0 cm beyond the cystourethral junction.

The **kidneys** revealed normal size and structure, corticomedullary definition and ratio for this age. The cortices presented largely uniform texture with normal echogenic relationship to liver and spleen.

INTERPRETED BY

Eric Lindquist, DMV
DABVP, Cert. IVUSS

IMAGING PERFORMED BY

Jessica Miller

HOSPITAL NAME

All Creatures Great &
Small

REFERRING VET

Dr. Ashmore

INVOICE

23212

DATE

7/2



PATIENT

Zeus Henry

Medullary structure differed distinctly from the cortex and no evidence of pelvic dilation was present. The capsules were acceptably uniform without significant irregularities. The right kidney measured 7.0 cm. The left kidney measured 6.9 cm.

SPECIES

Canine

Adrenal Glands

Both **adrenal glands** were visualized and recognized as having normal shape, size, position and echogenicity for this breed. The phrenic vasculature, glandular echogenicity and detail were unremarkable. Capsule, cortex, and medullary definition were normal for this age patient. The left adrenal gland measured 2.55 cm x 0.72 cm at the caudal pole and 0.58 cm at the cranial pole. The right adrenal gland measured 0.4 cm at the caudal pole and 0.8 cm at the cranial pole.

BREED

Pit Mix

Spleen

The **spleen** presented a smooth homogeneous parenchyma hyperechoic to liver and renal cortical parenchyma. The capsule was smooth without noticeable expansion or deviation from within the spleen or adjacent pathology. The splenic vasculature demonstrated normal volume without signs of congestion or thrombosis. No sonographic evidence of acute or chronic inflammatory, neoplastic, or infarctual changes were noted. Cranial folding of the spleen was noted.

SEX

Neutered Male

AGE

9 Years

Liver

The **liver** revealed passive congestion pattern with dilated hepatic veins. Coarse architecture was noted in the liver yet uniform. The gallbladder and common bile duct were unremarkable.

WEIGHT

70 Pounds

Gastrointestinal

There was some residual chyme and gas was noted in the **stomach**, yet not pathological. This is consistent with end post prandial presentation. Transit of chyme into the small intestine was normal. Curvilinear patterns were maintained throughout the GI tract. No evidence of pathology. Small and large intestine demonstrated normal luminal chyme and stool consistency respectively. No obstructive or overt infiltrative disease was noted. No associated abnormal lymphatic activity was noted.

INTERPRETED BY

Eric Lindquist, DMV
DABVP, Cert. IVUSS

Pancreas

The base and limbs of the **pancreas** were observed to be largely isoechoic to surrounding omental fat. Pancreatic duct and capsular contour were acceptably normal and parenchyma respected normal curvilinear patterns. No overt evidence of active inflammatory or neoplastic disease was noted.

IMAGING PERFORMED BY

Jessica Miller

HOSPITAL NAME

All Creatures Great &
Small

Free Abdomen

A large amount of **ascites** was noted in the abdomen.

REFERRING VET

Dr. Ashmore

ULTRASONOGRAPHIC FINDINGS

- Cardiac mass with obstruction of vena cava inflow with secondary passive congestion to the liver and abdomen.
- Ascites, owing to passive congestion in the abdomen.
- Age-related abdominal changes otherwise

INVOICE

23212

INTERPRETATION OF THE FINDINGS & FURTHER RECOMMENDATIONS

DATE

7/2

The mass is nonresectable and in an obstructive position to the right atrium deriving from the right auricle and right auricular free wall causing obstruction of vena cava inflow. The position and



PATIENT

Zeus Henry

architecture would suggest hemangiosarcoma. Passive congestion is secondary to the obstructive mass.

SPECIES

Canine

BREED

Pit Mix

SEX

Neutered Male

AGE

9 Years

WEIGHT

70 Pounds

INTERPRETED BY

Eric Lindquist, DMV
DABVP, Cert. IVUSS

IMAGING PERFORMED BY

Jessica Miller

HOSPITAL NAME

All Creatures Great &
Small

REFERRING VET

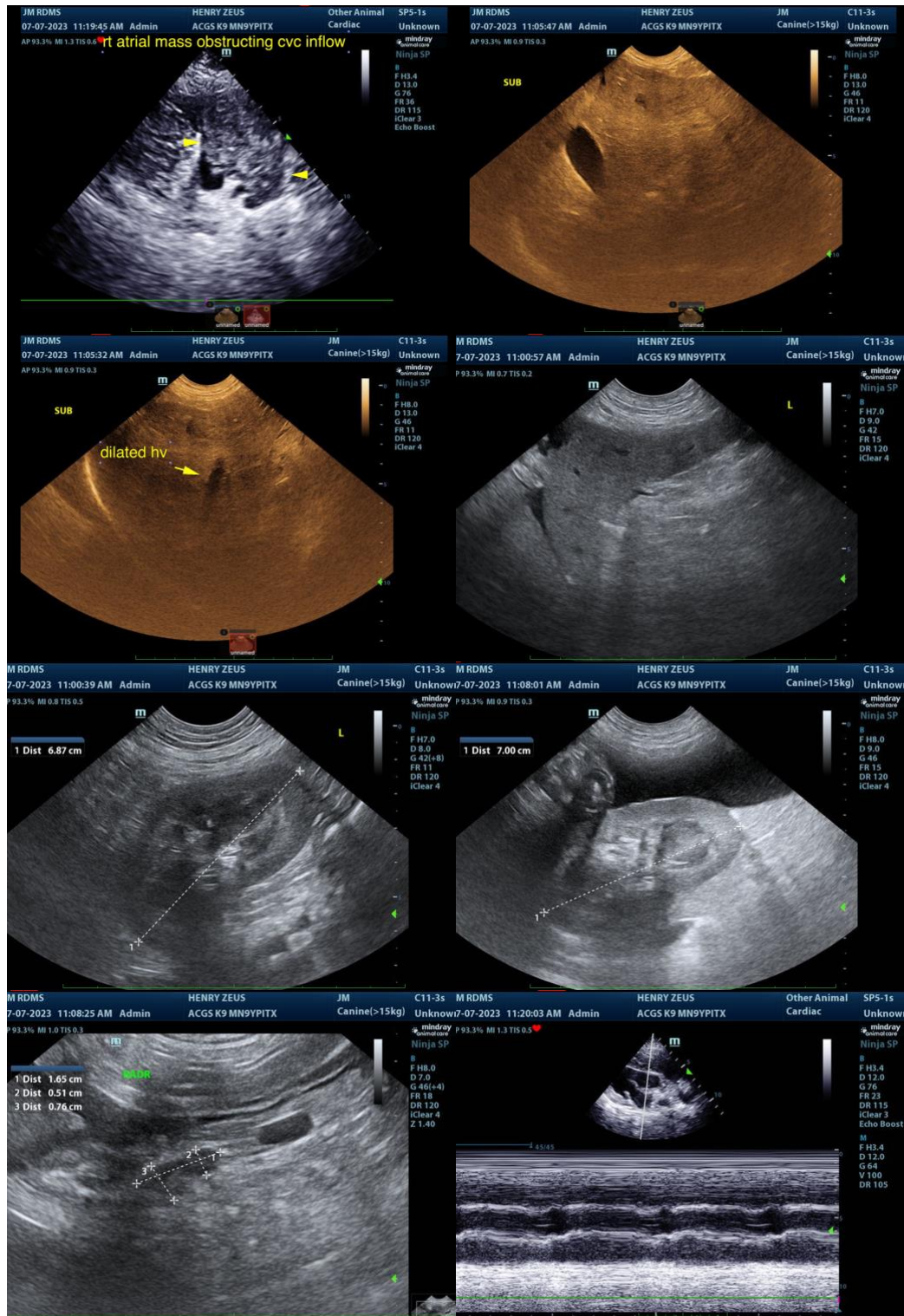
Dr. Ashmore

INVOICE

23212

DATE

7/2





PATIENT

Zeus Henry

SPECIES

Canine

BREED

Pit Mix

SEX

Neutered Male

AGE

9 Years

WEIGHT

70 Pounds

INTERPRETED BY

Eric Lindquist, DMV
DABVP, Cert. IVUSS

IMAGING PERFORMED BY

Jessica Miller

HOSPITAL NAME

All Creatures Great &
Small

REFERRING VET

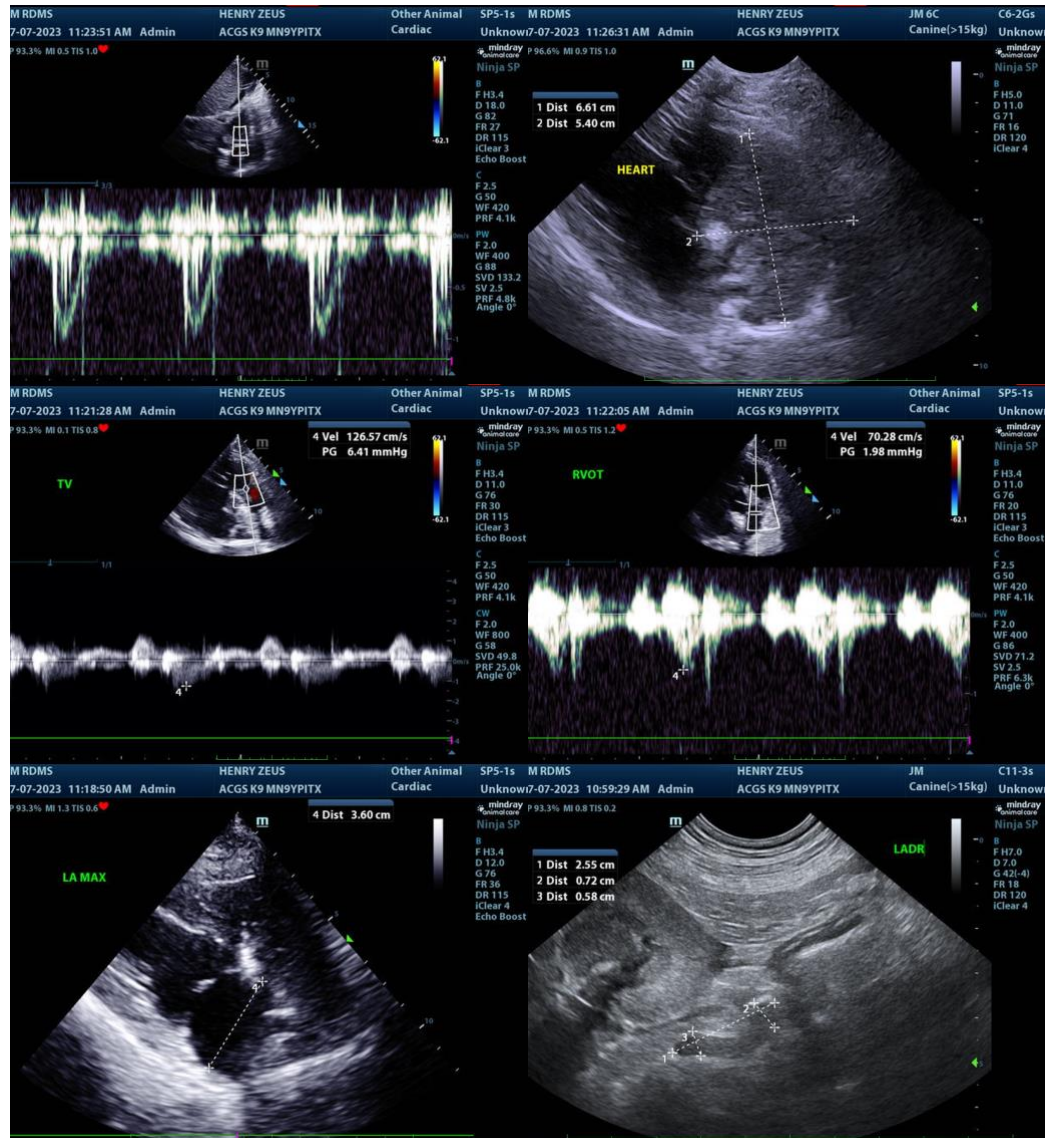
Dr. Ashmore

INVOICE

23212

DATE

7/2



The information and recommendations provided are based on the images presented by the referring veterinarian. No evaluation can be communicated regarding pathology that was not visible in the image/video clips provided.

Thank you for this referral. If the clinical or image interpretation does not parallel your findings or if I can be of any further assistance please contact me.

Eric Lindquist, DMV, DABVP, Cert. IVUSS, CEO of SonoPath.com
info@SonoPath.com

Pericardial Effusion and Cardiac Neoplasia



PATIENT

<http://www.sonopath.com/CardiacNeoplasiaEffusion>

Zeus Henry

SPECIES

Canine

BREED

Pit Mix

SEX

Neutered Male

AGE

9 Years

WEIGHT

70 Pounds

INTERPRETED BY

Eric Lindquist, DMV
DABVP, Cert. IVUSS

IMAGING PERFORMED BY

Jessica Miller

HOSPITAL NAME

All Creatures Great &
Small

REFERRING VET

Dr. Ashmore

INVOICE

23212

DATE

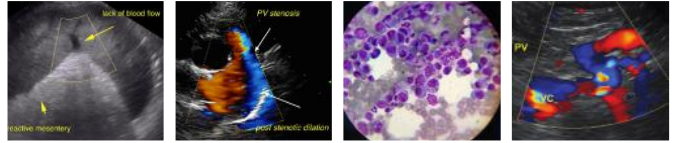
7/2

Description: The pericardium is a fibrous sac that encloses the heart and the great vessels—aorta, pulmonary artery, proximal pulmonary veins, and vena cava—located at the heart's base. It is attached caudally to the diaphragm and under normal circumstances contains 1-15 mL of fluid. The latter is comprised of phospholipids that lubricate the heart and allow it to expand and contract without generating friction. The pericardium also fixes the heart, prevents excess motion, and links the diastolic distensibility of the ventricles, thus limiting the degree to which either the left or the right ventricle will distend during diastole. When there are acute changes in venous return (i.e., during exercise), the pericardium plays a critical role in limiting ventricular filling. In cases of chronic cardiac enlargement, the pericardium also becomes distended, and its ability to limit ventricular filling, especially when the heart is at rest, becomes compromised. Pericardial tamponade occurs when there is a rapid accumulation of fluid and the pressure inside the pericardium increases significantly. With tamponade, ventricular filling is restricted and cardiac output is decreased. The right atrium and ventricle are the most vulnerable to this condition as these compartments have thinner walls and a lower pressure.

Etiology: Causes of pericardial effusion include:

- Neoplasia
 - Right atrial (RA) hemangiosarcoma
 - Heart base (aortic body) tumors
 - Mesothelioma
 - Rhabdomyosarcoma
 - Ectopic thyroid carcinoma
 - Metastatic neoplasia
- Idiopathic
- Congestive heart failure
- Peritoneal-pericardial diaphragmatic hernia
- Pericardial cyst
- Hypoalbuminemia
- Infectious pericarditis (bacterial, *Coccidioides immitus*)
- Feline infectious peritonitis
- Left atrial tear secondary to valvular disease
- Coagulopathy

The majority of neoplastic masses consist of hemangiosarcoma and heart-based tumors (chemodectomas or ectopic thyroid adenocarcinoma). Idiopathic pericardial effusion is a diagnosis of exclusion; the effusion is typically hemorrhagic. Approximately 50% of dogs will be cured with a single pericardiocentesis, while some dogs will require multiple pericardiocenteses as well as surgery. A peritoneal-pericardial diaphragmatic hernia is a congenital hernia seen in dogs and cats in which the abdominal contents (i.e., liver, small intestine, spleen, stomach) herniate into the pericardial sac. Constrictive pericarditis is an uncommon condition in which a non-distensible, thickened, fibrotic pericardium develops over time.



PATIENT

Zeus Henry

Clinical Signs: One will observe the following clinical signs, which often present in combination: ascites, lethargy, exercise intolerance, pale mucous membranes, weak pulses, *pulsus paradoxus*, and respiratory distress.

SPECIES

Canine

Diagnostics: Survey radiographs will reveal hepatomegaly, cardiomegaly (generalized or sectorial globoid), and small pulmonary vessels. Pulmonary edema is typically not found, although one may discover concurrent pulmonary metastatic disease. An ECG will show electrical alternans or small complexes, but often the changes are very subtle and difficult to detect.

BREED

Pit Mix

SEX

Neutered Male

Echocardiography is usually considered the gold standard for diagnosing pericardial effusion. Findings include:

AGE

9 Years

- Anechoic space between the heart and the pericardium.
- Abnormal side-to-side cardiac motion.
- Decreased chamber size (right ventricle [RV] and left ventricle [LV]).
- Presence of a pericardial or cardiac mass.
- Tamponade with early diastolic RA and RV collapse.

WEIGHT

70 Pounds

Cytology is helpful in the diagnosis of lymphoma, septic pericarditis, and idiopathic effusion, but not in cases of neoplasia.

INTERPRETED BY

Eric Lindquist, DMV
DABVP, Cert. IVUSS

According to a study that found troponin I levels to be higher in dogs with neoplastic pericardial effusion, the cardiac troponin I assay can be helpful in the diagnosis hemangiosarcoma.

IMAGING PERFORMED BY

Jessica Miller

Prognosis:

HOSPITAL NAME

All Creatures Great &
Small

- Cardiac hemangiosarcoma: < 8 months with surgical debulking and chemotherapy.
- Chemodectoma (aortic derived): MST 730 days post pericardectomy.
- Idiopathic: 50% complete resolution post cardiocentesis; curative with pericardectomy, which can be done via thoracotomy, or thoracoscopy, or using a balloon to tear the pericardium.
- Mesothelioma: Poor.
- Restrictive pericarditis: Poor, especially when the pericardium has not been surgical stripped.

REFERRING VET

Dr. Ashmore

INVOICE

23212

References:

DATE

7/2

Cagle LA, Epstein SE, Owens SD, et al. Diagnostic yield of cytology analysis of pericardial effusion in dogs. *J Vet Int Med* 2014;28:66-71.



PATIENT

Zeus Henry Feigenbaum H. Pericardial disease. In: Feigenbaum H, ed. *Echocardiography*, 5th ed. Philadelphia, PA: Lippincott, Williams & Wilkins; 1994:556-588.

SPECIES

Canine Jackson J, Richter KP, Launer DP. Thorascopic partial pericardectomy in 13 dogs. *J Vet Int Med* 1999;13:529-33.

BREED

Pit Mix Johnson MS, Martin M, Binns S. A retrospective study of clinical findings, treatment and outcome in 143 dogs with pericardial effusion. *J Small Anim Prac* 2004;45:546-52.

SEX

Neutered Male Kienle RD, Thomas WP. Echocardiography. In: Nyland TG and Mattoon JS, eds. *Small Animal Diagnostic Ultrasound*, 2nd ed. Philadelphia, PA: WB Saunders; 2000:354-423.

AGE

9 Years Miller MW, Sisson DD. Pericardial disorders. In: Ettinger SJ and Feldman EC, eds. *Textbook of Veterinary Internal Medicine*, 5th ed. Philadelphia, PA: WB Saunders; 2000:923-36.

WEIGHT

70 Pounds Rajagopalan V, Jesty SA, Craig LE, et al. Comparison of presumptive echocardiographic and definitive diagnoses of cardiac tumors in dogs. *J Vet Int Med* 2013;27:1092-96.

INTERPRETED BY

Eric Lindquist, DMV DABVP, Cert. IVUSS Shaw SP, Rozanski EA, Ruhs JE. Cardiac troponins I and T in dogs with pericardial effusion. *J Vet Int Med* 2004;18:322-24.

IMAGING PERFORMED BY

Jessica Miller Sidley JA, Atkins CE, Keene BW, et al. Percutaneous balloon pericardiotomy as a treatment for recurrent pericardial effusion in 6 dogs. *J Vet Intern Med* 2002;16:541.

HOSPITAL NAME

All Creatures Great & Small Sisson D, Thomas WP. Pericardial disease and cardiac tumors. In: Fox PR, Sisson D, Moise NS, eds. *Textbook of Canine and Feline Cardiology*, 2nd ed. Philadelphia, PA: WB Saunders; 1999:679-701.

REFERRING VET

Dr. Ashmore Sisson D, Thomas WP, Reed J, et al. Intrapericardial cysts in the dog. *J Vet Int Med* 1993;7:364-69.

INVOICE

23212

DATE

7/2