



PATIENT

Rosay Canale

SPECIES

Canine

BREED

Pitbull

SEX

Spayed Female

AGE

10 Years

WEIGHT

47.5 Pounds

PRESENTING CLINICAL SIGNS

History: Mass in chest (suspect Thymoma) potentially causing swelling in left arm and face. Elevated liver enzymes (concern for mets). Current Meds: Metacam, Lixotinic, Furosemide

Abnormal PE/Chem/CBC/UA Results: SDMA: 20, ALT: 285, RBC: 4.68

ULTRASONOGRAPHIC EXAMINATION OF THE HEART & ABDOMEN

CANINE CARDIAC PARAMETERS	MR VMAX (m/s)	TR VMAX (m/s)	LA/AO (Boon method)	LA/AO (Heart Base; Swe)	FS (%)	EF (%)	EPSS (cm)
NORMAL PARAMETER	4.5-5.5	<2.7	1.3	<1.3	28-40	40-100	<0.6
PATIENT	--	--	1.0	1.34	30	59	NM
CANINE CARDIAC PARAMETERS	HR (BPM)	AV VMAX (m/s)	PV MAX (m/s)	BODY WEIGHT (kg)	LA 2D short axis Base view (cm)	LVIDd Avg; 2D and m-mode short axis (cm)	LVIDs Avg; 2D and m-mode short axis (cm)
NORMAL PARAMETER	50-100	0.7-1.7	0.7-1.6				
PATIENT	138	1.65	1.00	--	--	2.95	--

INTERPRETED BY

Eric Lindquist, DMV
DABVP, Cert. IVUSS

IMAGING PERFORMED BY

Shari Reffi, CVT

HOSPITAL NAME

Smithfield AH

REFERRING VET

Dr. Boe

INVOICE

23207

DATE

7/7/23

Cardiac Presentation

The echocardiogram in this patient demonstrated normal **left atrial** size based on 3 separate methods of LA evaluation. The cranial and caudal **mitral** valve leaflets presented normal linear structure, extension in systole, and union in diastole with normal kinesis. The **left ventricle** presented thicknesses with linear contour and was not dilated nor restricted. The **myocardium** presented normal echogenicity without subjective evidence of significant fibrotic or ischemic disease.

Contractility of the ventricular walls was adequate and in normal range for this patient evidenced by the fractional shortening measurement and subjective evaluation of the different regions of the myocardium. Trivial aortic insufficiency was noted, not clinically significant. The **right atrium** and auricle revealed normal size, structure and content. No evidence of masses was noted. **Tricuspid** valvular assessment demonstrated adequate linear morphology and kinesis. The **right ventricle** was of normal size (1/3 diameter of LV), chordae structure, myocardial echogenicity and thickness.

Pulmonary outflow tract assessment revealed normal valve structure, laminar flow, and diameter (approx. 1:1 pa/ao ratio). A cranial mediastinal tissue mass was noted, measuring 7.5 cm x 5.7 cm.

Urinary System

The **urinary bladder**, trigone, and pelvic urethra presented normal thicknesses and normal tone. The ureters were not visible which is normal. No uroliths or sediment were visualized and anechoic urine was present. No evidence of inflammatory or neoplastic changes were noted. Ureteral papillae were normal.



PATIENT

Rosay Canale

The **kidneys** revealed normal size and structure, corticomedullary definition and ratio for this age. The cortices presented largely uniform texture with normal echogenic relationship to liver and spleen. Medullary structure differed distinctly from the cortex and no evidence of pelvic dilation was present. The capsules were acceptably uniform without significant irregularities. The left kidney measured 5.0 cm.

SPECIES

Canine

Adrenal Glands

BREED

Pitbull

Both **adrenal glands** were visualized and recognized as having normal shape, size, position and echogenicity for this breed. The phrenic vasculature, glandular echogenicity and detail were unremarkable. Capsule, cortex, and medullary definition were normal for this age patient. The right adrenal gland measured 2.08 cm x 0.89 cm at the cranial pole and 0.74 cm at the caudal pole. The left adrenal gland measured 2.04 cm x 0.42 cm at the cranial pole and 0.59 cm at the caudal pole.

SEX

Spayed Female

Spleen

AGE

10 Years

The **spleen** presented a smooth homogeneous parenchyma hyperechoic to liver and renal cortical parenchyma. The capsule was smooth without noticeable expansion or deviation from within the spleen or adjacent pathology. The splenic vasculature demonstrated normal volume without signs of congestion or thrombosis. No sonographic evidence of acute or chronic inflammatory, neoplastic, or infarctual changes were noted.

WEIGHT

47.5 Pounds

Liver

INTERPRETED BY

Eric Lindquist, DMV
DABVP, Cert. IVUSS

The **liver** images submitted revealed subjectively normal liver size, contour, and structure. Parenchymal echogenicity was naturally coarse and hypoechoic to the spleen. Vascular and biliary tracts were of normal volume with no evidence of congestion. The gallbladder presented acceptably thin walls with primarily anechoic content. The cystic and common bile ducts were normal. No pathological hepatic lymphadenopathy was evident. No overt structural evidence of inflammatory, infiltrative or regenerative pathology was evident.

Gastrointestinal

IMAGING PERFORMED BY

Shari Reffi, CVT

Examination of the **gastrointestinal tract** revealed a stomach and intestine free of stasis, of normal wall thickness, acceptable curvilinear mural detail, and peristaltic activity. Small and large intestine demonstrated normal luminal chyme and stool consistency respectively. No obstructive or overt infiltrative disease was noted. No associated abnormal lymphatic activity was noted.

HOSPITAL NAME

Smithfield AH

Pancreas

REFERRING VET

Dr. Boe

The base and limbs of the **pancreas** were observed to be largely isoechoic to surrounding omental fat. Pancreatic duct and capsular contour were acceptably normal and parenchyma respected normal curvilinear patterns. No overt evidence of active inflammatory or neoplastic disease was noted.

INVOICE

23207

ULTRASONOGRAPHIC FINDINGS

- Normal echocardiogram with cranial mediastinal mass, likely of lymph node origin.
- Trivial aortic insufficiency.
- Normal abdomen

DATE

7/7/23

INTERPRETATION OF THE FINDINGS & FURTHER RECOMMENDATIONS

CT evaluation is recommended for potential surgical evaluation/planning. No evidence of related abdominal disease. Sarcoma vs possibility of thymoma. Lung carcinoma or sarcoma is possible yet



PATIENT

less likely, as I do not see any peripheral air entrapment to the lesion. FNA was performed on the mass without complication.

Rosay Canale

ABOUT SONOPATH CT SERVICES:

SPECIES

SonoPath CT Services are offered at the SonoPath Imaging and Veterinary Education Center, 141 Main St (rt 206), Andover, New Jersey, a 20-minute drive west on route 80/206 North from the route 80/287 interchange/Parsippany, New Jersey. More information can be found at <https://sonopath.com/services/vetimaging/>

Canine

BREED

Pitbull

SEX

Spayed Female

AGE

10 Years

WEIGHT

47.5 Pounds

INTERPRETED BY

Eric Lindquist, DMV
DABVP, Cert. IVUSS

IMAGING PERFORMED BY

Shari Reffi, CVT

HOSPITAL NAME

Smithfield AH

REFERRING VET

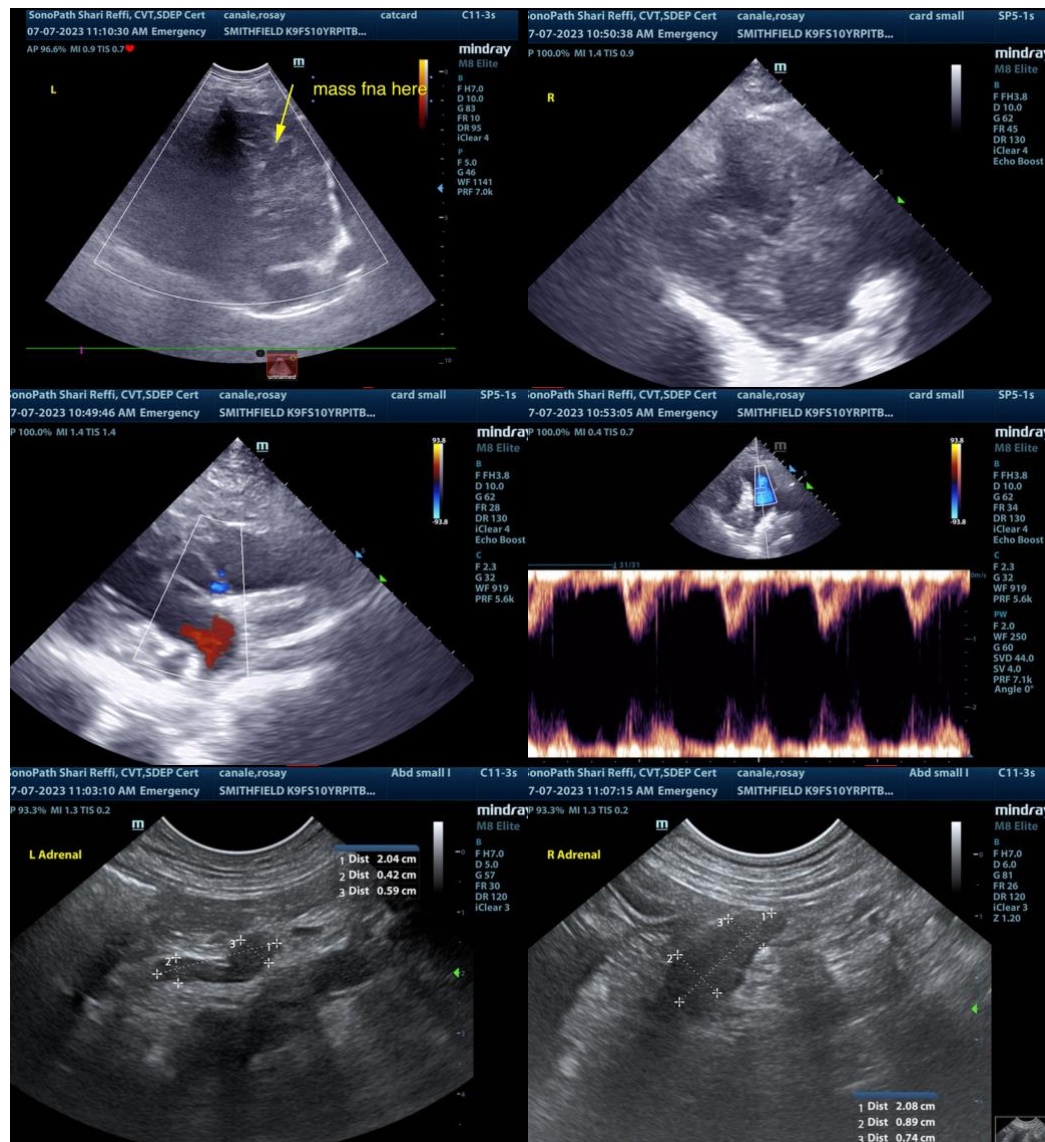
Dr. Boe

INVOICE

23207

DATE

7/7/23





PATIENT

Rosay Canale

SPECIES

Canine

BREED

Pitbull

SEX

Spayed Female

AGE

10 Years

WEIGHT

47.5 Pounds

INTERPRETED BY

Eric Lindquist, DMV
DABVP, Cert. IVUSS

IMAGING PERFORMED BY

Shari Reffi, CVT

HOSPITAL NAME

Smithfield AH

REFERRING VET

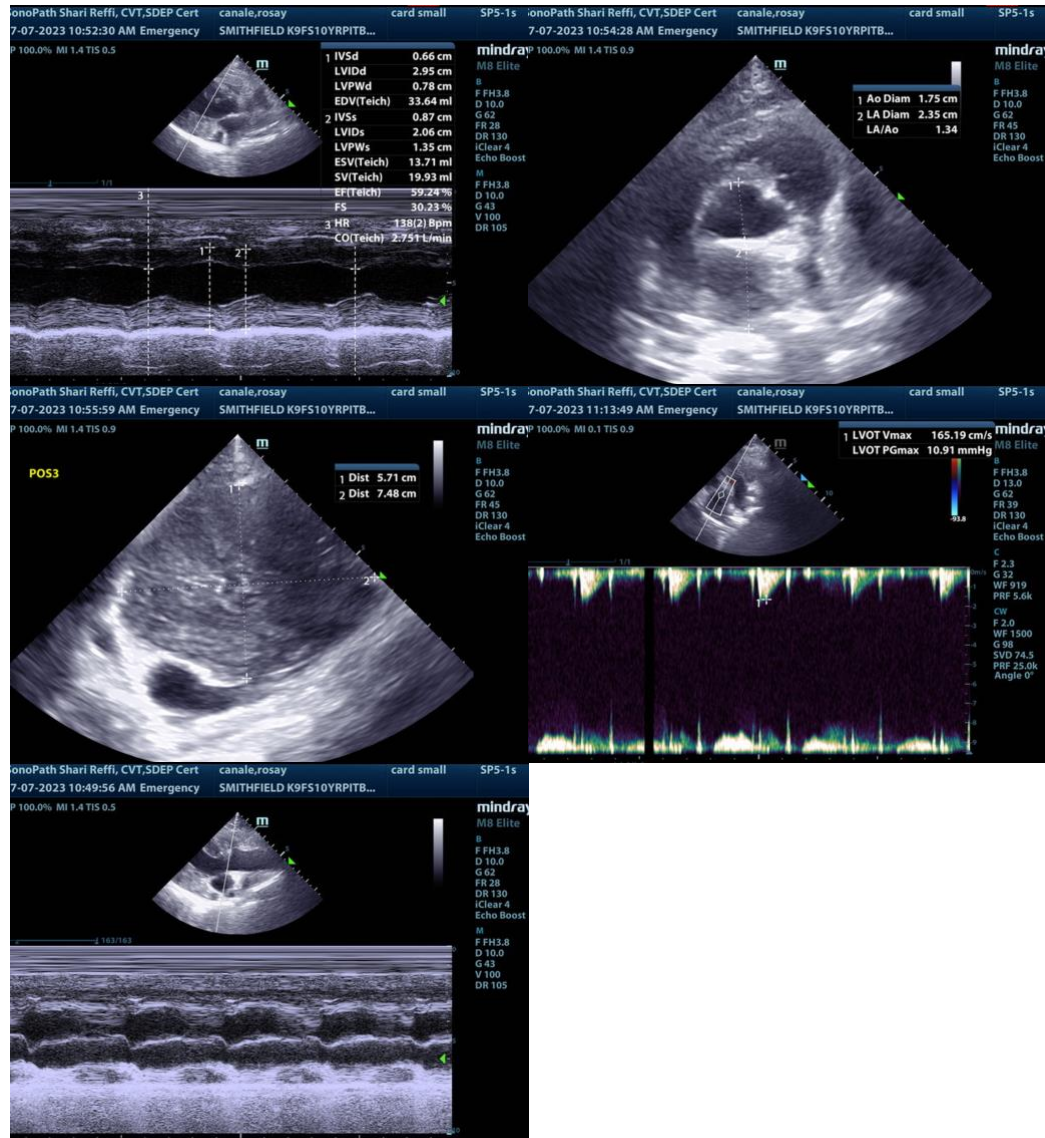
Dr. Boe

INVOICE

23207

DATE

7/7/23



The information and recommendations provided are based on the images presented by the referring veterinarian. No evaluation can be communicated regarding pathology that was not visible in the image/video clips provided.

Thank you for this referral. If the clinical or image interpretation does not parallel your findings or if I can be of any further assistance please contact me.

Eric Lindquist, DMV, DABVP, Cert. IVUSS, CEO of SonoPath.com
info@SonoPath.com