



**PATIENT PRESENTING CLINICAL SIGNS**

Rocco Polit History: Chronic diarrhea for about 2 weeks No vomiting  
Abnormal PE/Chem/CBC/UA Results: PE: NAF Digital fecal scan: NPS CBC/chem: ALT 212 cPL: < 90

**SPECIES ULTRASONOGRAPHIC EXAMINATION OF THE ABDOMEN**

Canine

**Urinary System**

**BREED**

The **urinary bladder**, trigone, and pelvic urethra presented normal thicknesses and normal tone. The ureters were not visible which is normal. No uroliths or sediment were visualized and anechoic urine was present. No evidence of inflammatory or neoplastic changes was noted. Ureteral papillae were normal.

German Shepherd  
Frenchie Mix

**SEX**

Neutered male

The **kidneys** revealed normal size and structure, corticomedullary definition and ratio for this age. The cortices presented largely uniform texture with normal echogenic relationship to liver and spleen. Medullary structure differed distinctly from the cortex and no evidence of pelvic dilation was present. The capsules were acceptably uniform without significant irregularities. The left kidney measured 6.71 cm. The right kidney measured 5.0 cm.

**AGE**

2 years

**WEIGHT**

60 lbs

**Adrenal Glands**

The region of the left adrenal gland was unremarkable.

**INTERPRETED BY**

Eric Lindquist, DMV  
DABVP, Cert. IVUSS

**Spleen**

The **spleen** presented a smooth homogeneous parenchyma hyperechoic to liver and renal cortical parenchyma. The capsule was smooth without noticeable expansion or deviation from within the spleen or adjacent pathology. The splenic vasculature demonstrated normal volume without signs of congestion or thrombosis. No sonographic evidence of acute or chronic inflammatory, neoplastic, or infarctual changes was noted.

**IMAGING PERFORMED BY**

Mayra Sanchez

**Liver**

The **liver** images submitted revealed subjectively normal liver size, contour, and structure. Parenchymal echogenicity was naturally coarse and hypoechoic to the spleen. Vascular and biliary tracts were of normal volume with no evidence of congestion. The gallbladder presented acceptably thin walls with primarily anechoic content. The cystic and common bile ducts were normal. No pathological hepatic lymphadenopathy was evident. No overt structural evidence of inflammatory, infiltrative or regenerative pathology was evident.

**HOSPITAL NAME**

Sunset AH

**REFERRING VET**

Dr. Polit

**INVOICE**

75958

**Gastrointestinal**

Examination of the **gastrointestinal tract** revealed a stomach and intestine free of stasis, of normal wall thickness, acceptable curvilinear mural detail, and peristaltic activity. Soft foreign body transit was noted in the jejunum. No associated abnormal lymphatic activity was noted.

**DATE**

7/7/23



**PATIENT**

Rocco Polit

**SPECIES**

Canine

**BREED**

German Shepherd  
Frenchie Mix

**SEX**

Neutered male

**AGE**

2 years

**WEIGHT**

60 lbs

**INTERPRETED BY**

Eric Lindquist, DMV  
DABVP, Cert. IVUS

**IMAGING PERFORMED BY**

Mayra Sanchez

**HOSPITAL NAME**

Sunset AH

**REFERRING VET**

Dr. Polit

**INVOICE**

75958

**DATE**

7/7/23

**Pancreas**

The base and limbs of the **pancreas** were observed to be largely isoechoic to surrounding omental fat. Pancreatic duct and capsular contour were acceptably normal and parenchyma respected normal curvilinear patterns. No overt evidence of active inflammatory or neoplastic disease was noted.

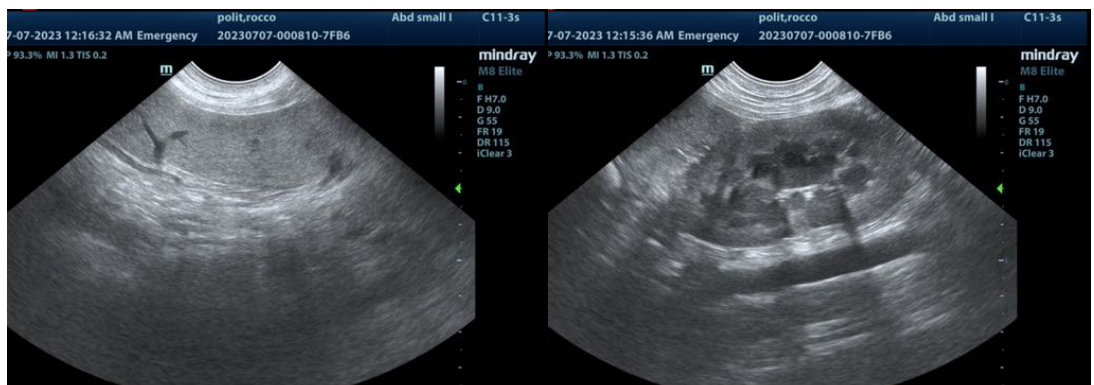
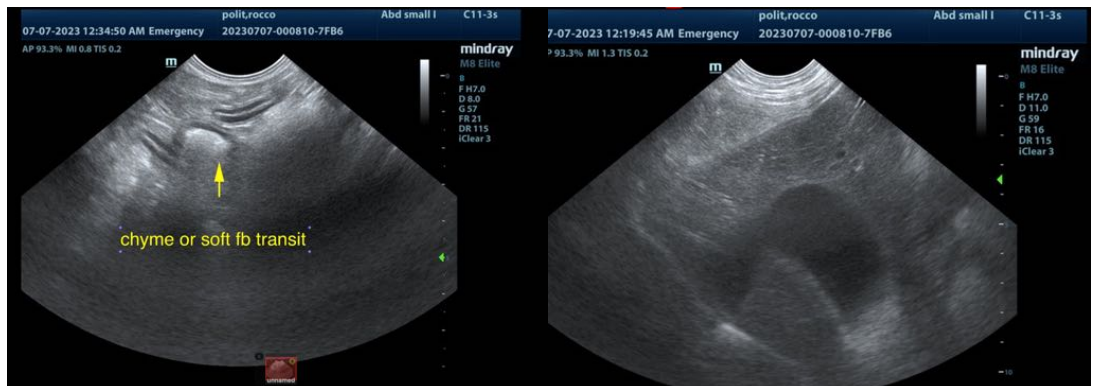**ULTRASONOGRAPHIC FINDINGS**

Transiting chyme or soft foreign matter, but was non-obstructive at the time of the sonogram.

**INTERPRETATION OF THE FINDINGS & FURTHER RECOMMENDATIONS**

Screening for Addison's is warranted given the breed predisposition and lack of visible adrenal glands.

Differentials for diarrhea include occult parasitism. Dietary indiscretion, dietary intolerance, antibiotic responsive colitis, intestinal dysbiosis and occult Addison's should all be considered as causes of diarrhea in this patient. A hydrolyzed diet trial may be in this patient's best interest +/- probiotics. 24-hour NPO and reintroduction of bland diet indicated. I recommend a baseline cortisol or ACTH stimulation test, a fresh fecal smear and fecal floatation analysis if not already performed.





**PATIENT**

Rocco Polit

**SPECIES**

Canine

**BREED**

German Shepherd  
Frenchie Mix

**SEX**

Neutered male

**AGE**

2 years

**WEIGHT**

60 lbs

**INTERPRETED BY**

Eric Lindquist, DMV  
DABVP, Cert. IVUSS

**IMAGING  
PERFORMED BY**

Mayra Sanchez

**HOSPITAL NAME**

Sunset AH

**REFERRING VET**

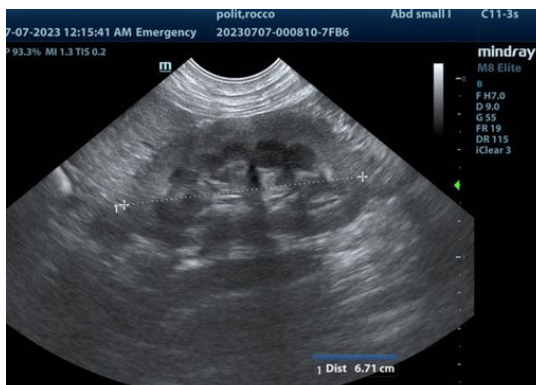Dr. Polit

**INVOICE**

75958

**DATE**

7/7/23



The information and recommendations provided are based on the images presented by the referring veterinarian/sonographer. No evaluation can be communicated regarding pathology that was not visible in the image/video clips provided.

Thank you for this referral. If the clinical or image interpretation does not parallel your findings or if I can be of any further assistance please contact me.

**Eric Lindquist**, DMV, DABVP, Cert. IVUSS, CEO of SonoPath.com  
info@SonoPath.com