SonoPath
Clinical Sonography & Telecytology
EDUCATIONAL TELECONSULTATION SERVICES™

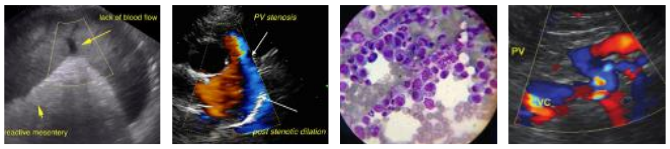

SonoPath.com
1-800-838-4268 info@sonopath.com

PATIENT
Nyx DiFalco

SPECIES
Feline

BREED
DMH

SEX
Spayed Female

AGE
11 Months

WEIGHT
3.33 kg

INTERPRETED BY
Eric Lindquist, DMV DABVP, Cert. IVUSS

IMAGING PERFORMED BY
Kelly Reschny

HOSPITAL NAME
Hamilton Regional EVC

REFERRING VET
Dr. Wattson

INVOICE
23193

DATE
7/7/23

PRESENTING CLINICAL SIGNS

History: Low grade heart murmur appreciated at rdvm prior to referral. None appreciated since transfer and time on IVFs. Primary concern if AKI of unknown origin. Current Medications Cerenia, pantoprazole, gabapentin, aluminum hydroxide.

Abnormal PE/Chem/CBC/UA Results: UA - USG 1.010, glucosuria, pH 5.0 - no significant hematuria or pyuria or casts CBC - L shift but normal WBC count m3 azotemia (Creatinine 913 umol/L, BUN 42.9 mmol/L, phosphorus 2.77 mmol/L) m1 hyponatremia (148) and hypochloremia (105), m2 hypokalemia (2.8 mmol/L) m2 hyperproteinemia (89 g/L) - Hct 0.433 m1 increased globulins (53 g/L) A:G 0.7 For ECHO Only: Blood Pressure 152/97 (MAP 122) HR/RR/BP: HR 174; RR 30.

ULTRASONOGRAPHIC EXAMINATION OF THE HEART & ABDOMEN

FELINE CARDIAC PARAMETERS	**BODY WEIGHT** (kg)	**HR** (BPM)	**IVSd** (cm)	**LVIDd** (cm)	**LVWd** (cm)	**FS** (%)	**EF** (%)
NORMAL PARAMETER	------	150-240	0.3-0.6	1.0-2.1	0.25-0.6	35-67	80-100
PATIENT	--	130	0.45	1.36	0.42	43	78
FELINE CARDIAC PARAMETERS	**LA/AO** (Boon)	**LA/AO HEART BASE** (Sisson)	**LA** 2D 4-chamber long axis AS to FW (Sisson) (cm)		**LVOT VEL.** (m/s)	**RVOT VEL.** (m/s)	**IVRT** (m/)
NORMAL PARAMETER	<1.5	0.88-1.79	0.7-1.7		<1.6	<1.3	40-60
PATIENT	1.09	1.0	1.2		--	.48	NM

Adapted from June Boon,Veterinary Echocardiography,1998
Sisson D et al. JVIM 1991; 5: 232, Jacobs et al. Am J Vet Res 1985; 46:1705

Cardiac Presentation

The echocardiogram in this patient demonstrated normal **left atrial** size based on 3 separate LA measurements. The cranial and caudal **mitral** valve leaflets presented normal linear structure and kinetics. The **left ventricle** presented normal thicknesses with linear contour and was not dilated nor restricted. The **myocardium** presented normal echogenicity without subjective evidence of significant fibrotic or ischemic disease. **Contractility** of the ventricular walls was adequate and in normal range for this patient evidenced by the fractional shortening measurement and subjective evaluation of the different regions and angles of the myocardium. The **left ventricular outflow** tract demonstrated normal laminar flow and subjective structural integrity. The **right atrium** and auricle revealed normal size, structure and content. No evidence of masses was noted or chamber overload. **Tricuspid** valvular assessment demonstrated adequate linear morphology and kinetics. The **right ventricle** was of normal size (1/3 diameter of LV), chordae structure, myocardial echogenicity and thickness. **Pulmonic** tract assessment revealed normal valve structure, laminar flow, and diameter (approx.1:1 pa/ao ratio).

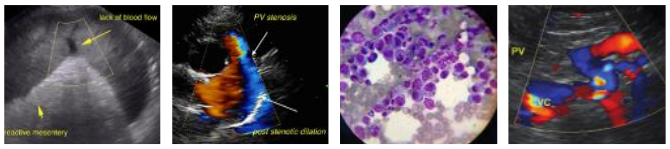

SonoPath.com™
1-800-838-4268 info@sonopath.com

PATIENT

Nyx DiFalco

SPECIES

Feline

BREED

DMH

SEX

Spayed Female

AGE

11 Months

WEIGHT

3.33 kg

INTERPRETED BY

Eric Lindquist, DMV
DABVP, Cert. IVUSS

IMAGING PERFORMED BY

Kelly Reschny

HOSPITAL NAME

Hamilton Regional EVC

REFERRING VET

Dr. Wattson

INVOICE

23193

DATE

7/7/23

No visible **pericardial** or free pleura fluid was noted or extra cardiac pathology in the visible planes. The cranial **mediastinum and pericardial regions** were free of masses in the visible window.

Urinary System

The **urinary bladder**, trigone, and pelvic urethra presented normal thicknesses and normal tone. The ureters were not visible which is normal. No uroliths or sediment were visualized and anechoic urine was present. No evidence of inflammatory or neoplastic changes were noted. Ureteral papillae were normal.

The **kidneys** were mildly swollen and slightly irregular with minor loss of corticomedullary definition. The right kidney measured 3.9 cm. The left kidney measured 3.9 cm. Blood flow to the kidneys was subnormal on power doppler assessment, but blood flow has improved. Hydration status should be evaluated in light of this finding. Slight pyelectasia was noted in the right kidney. This is a nonspecific insult.

Adrenal Glands

The **left adrenal gland** was visualized and recognized as having normal shape, size, position and echogenicity for this breed. The phrenic vasculature, glandular echogenicity and detail were unremarkable. Capsule, cortex, and medullary definition were normal for this age patient. The left adrenal gland measured 0.34 cm.

The region of the **right adrenal gland** revealed no evident pathology.

Spleen

The **spleen** presented a smooth homogeneous parenchyma hyperechoic to liver and renal cortical parenchyma. The capsule was smooth without noticeable expansion or deviation from within the spleen or adjacent pathology. The splenic vasculature demonstrated normal volume without signs of congestion or thrombosis. No sonographic evidence of acute or chronic inflammatory, neoplastic, or infarctual changes were noted.

Liver

The **liver** images submitted revealed subjectively normal liver size, contour, and structure. Parenchymal echogenicity was naturally coarse and hypoechoic to the spleen. Vascular and biliary tracts were of normal volume with no evidence of congestion. The gallbladder presented acceptably thin walls with primarily anechoic content. The cystic and common bile ducts were normal. No pathological hepatic lymphadenopathy was evident. No overt structural evidence of inflammatory, infiltrative or regenerative pathology was evident.

Gastrointestinal

Examination of the **gastrointestinal tract** revealed a stomach and intestine free of stasis, of normal wall thickness, acceptable curvilinear mural detail, and peristaltic activity. Small and large intestine demonstrated normal luminal chyme and stool consistency respectively. No obstructive or overt infiltrative disease was noted. No associated abnormal lymphatic activity was noted.

Pancreas

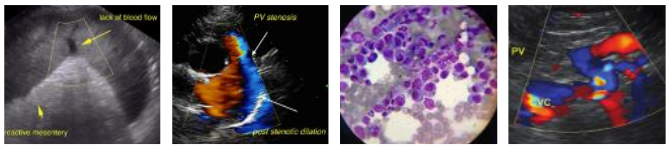

SonoPath.com
1-800-838-4268 info@sonopath.com

PATIENT

Nyx DiFalco

SPECIES

Feline

BREED

DMH

SEX

Spayed Female

AGE

11 Months

WEIGHT

3.33 kg

INTERPRETED BY

Eric Lindquist, DMV
DABVP, Cert. IVUSS

IMAGING PERFORMED BY

Kelly Reschny

HOSPITAL NAME

Hamilton Regional EVC

REFERRING VET

Dr. Wattson

INVOICE

23193

DATE

7/7/23

The base and limbs of the **pancreas** were observed to be largely isoechoic to surrounding omental fat. Pancreatic duct and capsular contour were acceptably normal and parenchyma respected normal curvilinear patterns. No overt evidence of active inflammatory or neoplastic disease was noted.

ULTRASONOGRAPHIC FINDINGS

- Normal echocardiogram-likely flow murmur
- Nonspecific renal insult

INTERPRETATION OF THE FINDINGS & FURTHER RECOMMENDATIONS

I recommend 72hr IV fluid protocol. Urine culture and sensitivity, blood pressures and hydration status are all important evaluations. Toxic or infectious insult should be considered. No contraindication to fluids based on the cardiac presentation. The murmur is likely a flow murmur, and not clinically significant. Flow murmurs can be caused by volume shifts, anemia, excitable/tachycardic state, DRVOTO (Dynamic Right Ventricular Outflow Obstruction), or even simple stethoscope pressure upon clinical exam. These flow murmurs are typically benign and may develop often later in life theoretically owing to age related clinically insignificant changes of the heart. If the patient is recently clinical for anorexia, weight loss or metabolic disturbances, an abdominal sonogram and full workup may be appropriate to assess underlying clinical systemic causes of a newly developed flow murmur.

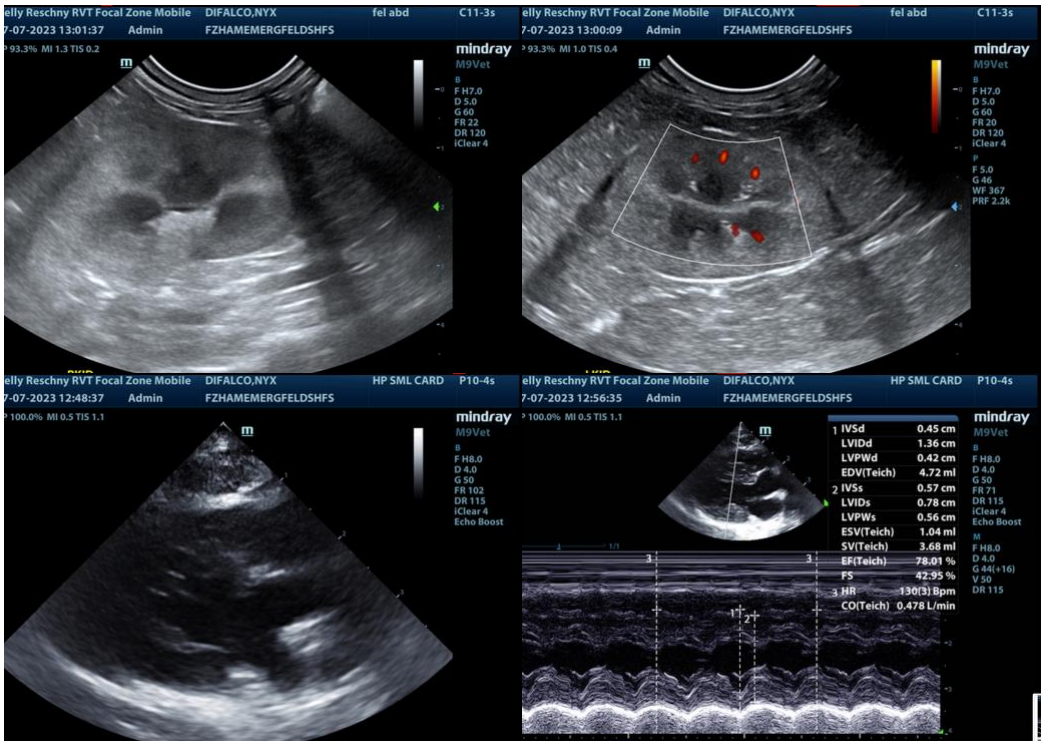

SonoPath

Clinical Sonography & Telecytology

EDUCATIONAL TELECONSULTATION SERVICES™

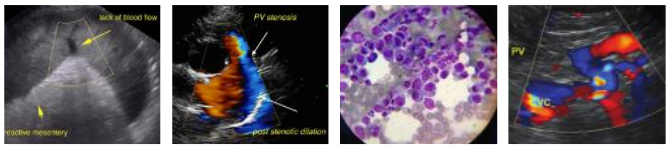

SonoPath.com™
1-800-838-4268 info@sonopath.com

PATIENT

Nyx DiFalco

SPECIES

Feline

BREED

DMH

SEX

Spayed Female

AGE

11 Months

WEIGHT

3.33 kg

INTERPRETED BY

Eric Lindquist, DMV
DABVP, Cert. IVUSS

IMAGING PERFORMED BY

Kelly Reschny

HOSPITAL NAME

Hamilton Regional EVC

REFERRING VET

Dr. Wattson

INVOICE

23193

DATE

7/7/23

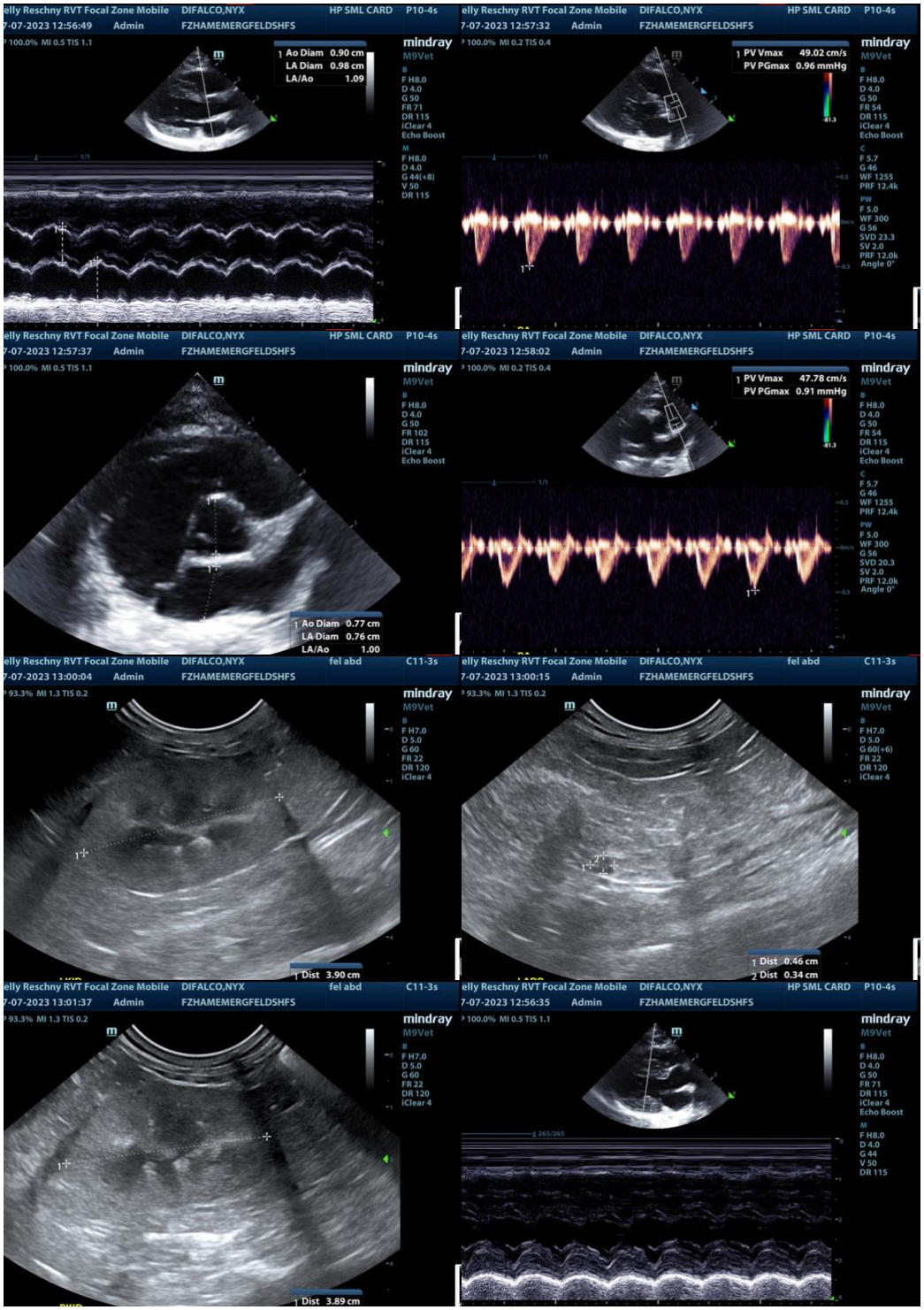

The information and recommendations provided are based on the images presented by the referring veterinarian. No evaluation can be communicated regarding pathology that was not visible in the image/video clips provided.

SonoPath
Clinical Sonography & Telecytology

EDUCATIONAL TELECONSULTATION SERVICES™

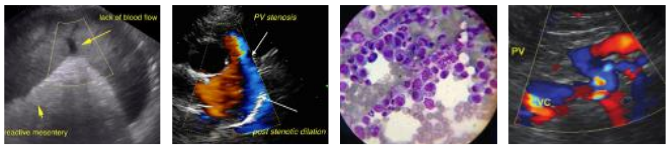

SonoPath.com™
1-800-838-4268 info@sonopath.com

PATIENT

Nyx DiFalco

SPECIES

Feline

BREED

DMH

SEX

Spayed Female

AGE

11 Months

WEIGHT

3.33 kg

INTERPRETED BY

Eric Lindquist, DMV
DABVP, Cert. IVUSS

IMAGING PERFORMED BY

Kelly Reschny

HOSPITAL NAME

Hamilton Regional EVC

REFERRING VET

Dr. Wattson

INVOICE

23193

DATE

7/7/23

Thank you for this referral. If the clinical or image interpretation does not parallel your findings or if I can be of any further assistance please contact me.

Eric Lindquist, DMV, DABVP, Cert. IVUSS, CEO of SonoPath.com
info@SonoPath.com