



PATIENT PRESENTING CLINICAL SIGNS

Infinity Buczek History: Possibly 5 weeks pregnant, mammary tissue is quite enlarged and firm.

SPECIES ULTRASONOGRAPHIC PREGNANCY CHECK

Feline Positive pregnancy noted in this patient. Fetal size measures 5.4 cm. Amniotic fluid appeared to be normal, anechoic. Spinal formation was normal with normal cardiac activity. At least 3 fetuses appear to be present. In the near field mammary tissue, it was uniform but significantly enlarged.

BREED ULTRASONOGRAPHIC FINDINGS

- Exotic • Live pregnancy, approximately 3 fetuses- Count should be performed based on radiographic findings.
- SEX • Mammary tissue significantly enlarged.

Intact Female

INTERPRETATION OF THE FINDINGS & FURTHER RECOMMENDATIONS

AGE Mammary gland evaluation is recommended; however, the gestation appears to be normal and healthy. The fetal size and development is consistent with 5 weeks of gestation.

WEIGHT

3.34 kg

INTERPRETED BY

Eric Lindquist, DMV
DABVP, Cert. IVUSS

IMAGING PERFORMED BY

Kelly Reschny

HOSPITAL NAME

Beattie PH Burlington

REFERRING VET

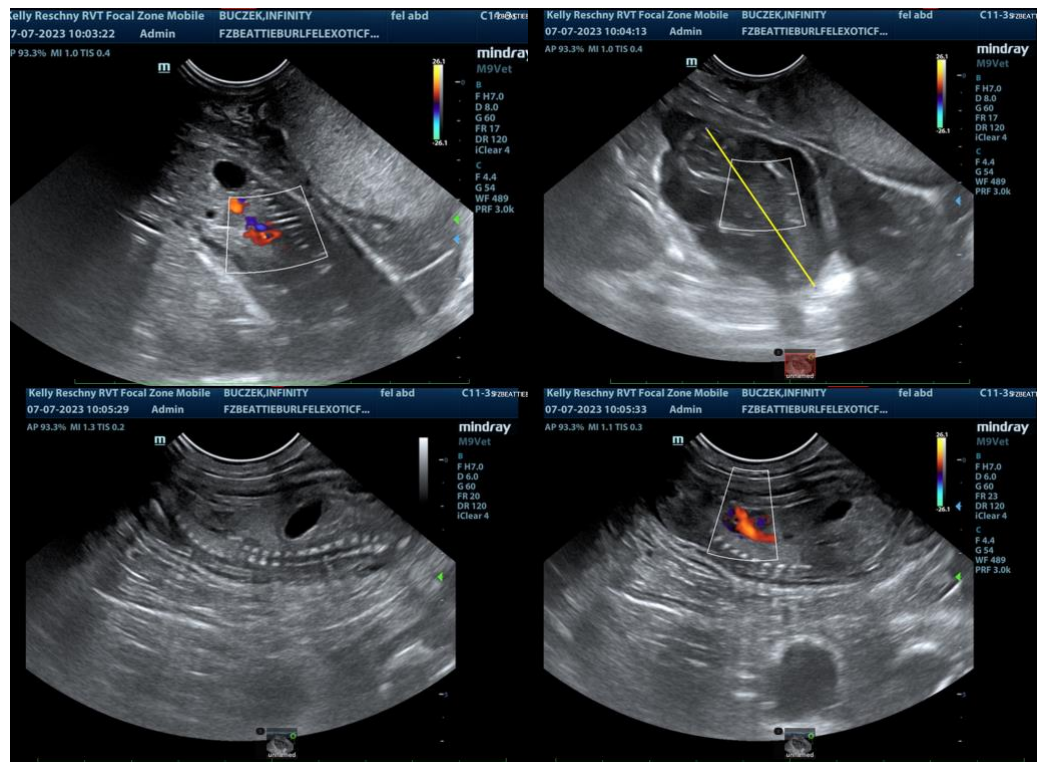
Dr. Wittenrich

INVOICE

23211

DATE

7/7/23



The information and recommendations provided are based on the images presented by the referring veterinarian. No evaluation can be communicated regarding pathology that was not visible in the image/video clips provided.

Thank you for this referral. If the clinical or image interpretation does not parallel your findings or if I can be of any further assistance please contact me.



PATIENT

Infinity Buczek

Eric Lindquist, DMV, DABVP, Cert. IVUSS, CEO of SonoPath.com
info@SonoPath.com

SPECIES

Feline

BREED

Exotic

SEX

Intact Female

AGE

1 Year

WEIGHT

3.34 kg

INTERPRETED BY

Eric Lindquist, DMV
DABVP, Cert. IVUSS

IMAGING PERFORMED BY

Kelly Reschny

HOSPITAL NAME

Beattie PH Burlington

REFERRING VET

Dr. Wittenrich

INVOICE

23211

DATE

7/7/23