



**PATIENT**

Gunner Rizzo

**SPECIES**

Canine

**BREED**

Brittany Spaniel

**SEX**

MN

**AGE**

13yr

**WEIGHT**

55lb

**INTERPRETED BY**

Eric Lindquist, DMV  
DABVP, Cert. IVUSS

**IMAGING PERFORMED BY**

John Ammeraal DVM

**HOSPITAL NAME**

Sova Animal Hospital

**REFERRING VET**

John Ammeraal DVM

**INVOICE**

14292ag

**DATE**

07/07/2023

**PRESENTING CLINICAL SIGNS**

Doing well. pants sometimes, Higher anxiety, concerns with dental disease.

Abnormal PE/Chem/CBC/UA Results: Multiple SQ fatty masses Heavy dental calculus ALKP 1818 U/L, ALT 333 U/L, AST 71 U/L rest BW WNL UA pending

**ULTRASONOGRAPHIC EXAMINATION OF THE ABDOMEN**

**Urinary System**

The urinary bladder, trigone, and pelvic urethra presented normal thicknesses and normal tone. The ureters were not visible which is normal. No uroliths or sediment were visualized, and anechoic urine was present. No evidence of inflammatory or neoplastic changes were noted. Ureteral papillae were normal.

The kidneys revealed normal size and structure, corticomedullary definition and ratio for this age. The cortices presented largely uniform texture with normal echogenic relationship to liver and spleen.

Medullary structure differed distinctly from the cortex and no evidence of pelvic dilation was present.

The capsules were acceptably uniform without significant irregularities. The left kidney measured 6.36 cm in length. The right kidney measured 6.33 cm in length.

**Adrenal Glands**

Both adrenal glands were visualized and recognized as having normal shape, size, position and echogenicity for this breed. The phrenic vasculature, glandular echogenicity and detail were unremarkable. Capsule, cortex, and medullary definition were normal for this age patient. The left adrenal gland measured 3.41 cm in length by 0.82 cm caudal pole width by 0.87 cm cranial pole width. The right adrenal gland measured 2.7 cm in length by 0.75 cm caudal pole width by 1.05 cm cranial pole width.

**Spleen**

The spleen was largely smooth with subtle heterogeneous parenchymal changes while maintaining normal echogenic relationship to the liver and kidney. These changes are consistent with normal age-related alteration. The capsule was smooth without noticeable impingement from within the spleen or from pathology in the adjacent abdomen. The splenic vasculature demonstrated normal volume without signs of congestion or significant contraction. No evidence of active acute or chronic inflammatory, neoplastic, or infarctual changes were noted.

**Liver**

The liver images from right and left intercostal as well as subcostal views revealed subjectively normal liver size, contour, and structure. Moderate age-related parenchymal remodeling was noted but likely not clinically significant at this time. Vascular and biliary tracts were of normal volume and no evidence of congestion was noted. A non-expansive hyperechoic nodule measuring 4.6 cm was present adjacent to the diaphragm. The gallbladder presented some dependent debris with essentially normal contour. The cystic and common bile ducts were normal. No overt evidence of active inflammatory, infiltrative or regenerative pathology was noted but should be paired with current or past LE elevations regarding any clinical significance to this presentation. The hepatic lymph nodes were unremarkable.

**Gastrointestinal**

Examination of the gastrointestinal tract revealed a stomach and intestine free of stasis, of normal wall thickness, acceptable curvilinear mural detail, and peristaltic activity. Small and large intestine



**PATIENT**

Gunner Rizzo

demonstrated normal luminal chyme and stool consistency respectively. No obstructive or overt infiltrative disease was noted. No associated abnormal lymphatic activity was noted.

**Pancreas**

**SPECIES**

Canine

The base and limbs of the pancreas were observed to be largely isoechoic to surrounding omental fat. Pancreatic duct and capsular contour were acceptably normal, and parenchyma respected normal curvilinear patterns. No overt evidence of active inflammatory or neoplastic disease was noted.

**BREED**

Brittany Spaniel

**Free Abdomen**

No omental masses, overt lymphadenopathy or peritoneal effusion was present.

**SEX**

Excessive falciform fat was present creating a lipomatous like structure measuring 4.0 cm x 7.0 cm.

MN

**ULTRASONOGRAPHIC FINDINGS**

**AGE**

13yr

- Subjectively benign hepatopathy-vacuolar hepatopathy pattern with right cranial liver nodule.
- Excessive falciform fat creating lipomatous like structure.

**WEIGHT**

55lb

**INTERPRETATION OF THE FINDINGS & FURTHER RECOMMENDATIONS**

No evidence of significant pathology related directly to the clinical signs. Given the panting, BP measurements are warranted. Assessment for orthopedic or CNS disease is warranted. CT for CNS/spinal column may be appropriate depending upon clinical status. FNA of the liver is warranted for further definition yet subjectively the liver appears benign.

**INTERPRETED BY**

Eric Lindquist, DMV  
DABVP, Cert. IVUSS

**IMAGING PERFORMED BY**

John Ammeraal DVM

**HOSPITAL NAME**

Sova Animal Hospital

**REFERRING VET**

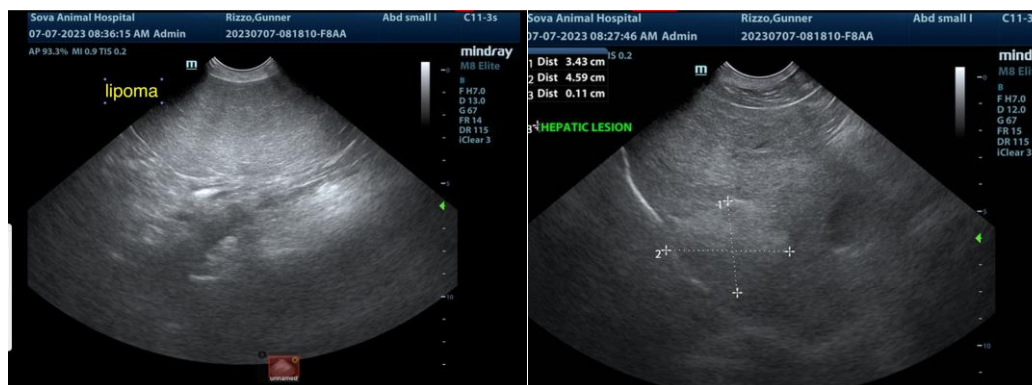
John Ammeraal DVM

**INVOICE**

14292ag

**DATE**

07/07/2023





**PATIENT**

Gunner Rizzo

**SPECIES**

Canine

**BREED**

Brittany Spaniel

**SEX**

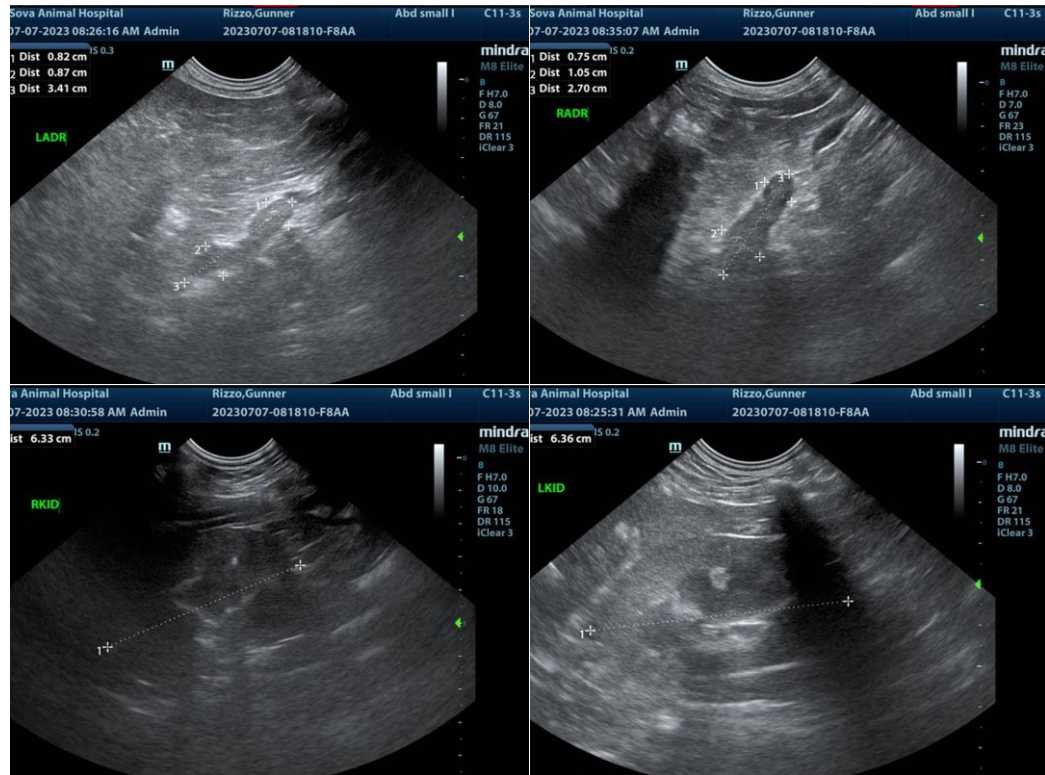
MN

**AGE**

13yr

**WEIGHT**

55lb



**INTERPRETED BY**

Eric Lindquist, DMV  
DABVP, Cert. IVUSS

**IMAGING PERFORMED BY**

John Ammeraal DVM

**HOSPITAL NAME**

Sova Animal Hospital

**REFERRING VET**

John Ammeraal DVM

**INVOICE**

14292ag

**DATE**

07/07/2023

The information and recommendations provided are based on the images presented by the referring veterinarian/sonographer. No evaluation can be communicated regarding pathology that was not visible in the image/video clips provided.

Thank you for this referral. If the clinical or image interpretation does not parallel your findings or if I can be of any further assistance, please contact me.

Eric Lindquist, DMV, DABVP, Cert. IVUSS, CEO of SonoPath.com  
Eric.Lindquist@SonoPath.com