



**PATIENT PRESENTING CLINICAL SIGNS**

Dunkin Bratton Hx of diabetes, was boarding then went home and collapsed.

**SPECIES ULTRASONOGRAPHIC EXAMINATION OF THE HEART & ABDOMEN**

Feline

BREED

DSH

SEX

Neutered Male

AGE

10

WEIGHT

14.7

FELINE CARDIAC PARAMETERS	BODY WEIGHT (kg)	HR (BPM)	IVSd (cm)	LVIDd (cm)	LVWd (cm)	FS (%)	EF (%)
NORMAL PARAMETER	-----	150-240	0.3-0.6	1.0-2.1	0.25-0.6	35-67	80-100
PATIENT		NM	0.45	1.6	0.45	45	90
FELINE CARDIAC PARAMETERS	LA/AO (Boon)	LA/AO HEART BASE (Sisson)	LA 2D 4-chamber long axis AS to FW (Sisson) (cm)	LVOT VEL. (m/s)	RVOT VEL. (m/s)	IVRT (m/)	
NORMAL PARAMETER	<1.5	0.88-1.79	0.7-1.7	<1.6	<1.3	40-60	
PATIENT	1.3	1.3	--	--	--	NM	

Adapted from June Boon, Veterinary Echocardiography, 1998  
Sisson D et al. JVIM 1991; 5: 232, Jacobs et al. Am J Vet Res 1985; 46:1705

**INTERPRETED BY**

Eric Lindquist, DMV

DABVP, Cert. IVUSS

**IMAGING PERFORMED BY**

Jenn

**HOSPITAL NAME**

Rockaway AH

**REFERRING VET**

Dr. Maniar

**INVOICE**

43861

**DATE**

7/7/23

**Cardiac Presentation**

The echocardiogram in this patient demonstrated normal **left atrial** size based on 3 separate LA measurements. The cranial and caudal **mitral** valve leaflets presented normal linear structure and kinetics. The **left ventricle** presented normal thicknesses with linear contour and was not dilated nor restricted. The **myocardium** presented normal echogenicity without subjective evidence of significant fibrotic or ischemic disease. **Contractility** of the ventricular walls was adequate and in normal range for this patient evidenced by the fractional shortening measurement and subjective evaluation of the different regions and angles of the myocardium. The **left ventricular outflow** tract demonstrated normal laminar flow and subjective structural integrity. The **right atrium** and auricle revealed normal size, structure and content. No evidence of masses was noted or chamber overload. **Tricuspid** valvular assessment demonstrated adequate linear morphology and kinetics. The **right ventricle** was of normal size (1/3 diameter of LV), chordae structure, myocardial echogenicity and thickness. **Pulmonic** tract assessment revealed normal valve structure, laminar flow, and diameter (approx. 1:1 pa/ao ratio). No visible **pericardial** or free pleura fluid was noted or extra cardiac pathology in the visible planes. The cranial **mediastinum** and **pericardial** regions were free of masses in the visible window.

**Urinary System**

The **urinary bladder**, trigone, and pelvic urethra presented normal thicknesses and normal tone. The ureters were not visible which is normal. No uroliths or sediment were visualized and anechoic urine was present. No evidence of inflammatory or neoplastic changes were noted. Ureteral papillae were normal.



**PATIENT**

Dunkin Bratton

The **kidneys** revealed normal size and structure, corticomedullary definition and ratio for this age. The cortices presented largely uniform texture with normal echogenic relationship to liver and spleen. Medullary structure differed distinctly from the cortex and no evidence of pelvic dilation was present. The capsules were acceptably uniform without significant irregularities. The right kidney measured 5.7 cm. The left kidney measured 4.78 cm.

**SPECIES**

Feline

**Adrenal Glands**

**BREED**

DSH

The regions of the **adrenal glands** were unremarkable.

**Spleen**

**SEX**

Neutered Male

The **spleen** revealed a hypoechoic nodule at the mid body. Splenic nodule measured 0.67 cm. The remainder of the spleen was unremarkable and uniform.

**Liver**

**AGE**

10

The **liver** images submitted revealed subjectively normal liver size, contour, and structure. Parenchymal echogenicity was naturally coarse and hypoechoic to the spleen. Vascular and biliary tracts were of normal volume with no evidence of congestion. The gallbladder presented acceptably thin walls with primarily anechoic content. The cystic and common bile ducts were normal. No pathological hepatic lymphadenopathy was evident. No overt structural evidence of inflammatory, infiltrative or regenerative pathology was evident.

**WEIGHT**

14.7

**Gastrointestinal**

**INTERPRETED BY**

Eric Lindquist, DMV

DABVP, Cert. IVUSS

Examination of the **gastrointestinal tract** revealed a stomach and intestine free of stasis, of normal wall thickness, acceptable curvilinear mural detail, and peristaltic activity. Small and large intestine demonstrated normal luminal chyme and stool consistency respectively. No obstructive or overt infiltrative disease was noted. No associated abnormal lymphatic activity was noted.

**IMAGING PERFORMED BY**

Jenn

**Pancreas**

The base and limbs of the **pancreas** were observed to be largely isoechoic to surrounding omental fat. Pancreatic duct and capsular contour were acceptably normal and parenchyma respected normal curvilinear patterns. No overt evidence of active inflammatory or neoplastic disease was noted.

**HOSPITAL NAME**

Rockaway AH

**ULTRASONOGRAPHIC FINDINGS**

- Normal echocardiogram, no evidence of functional pathology.
- Splenic nodule – round cell neoplasia, abscessation, hyperplasia all possible.

**REFERRING VET**

Dr. Maniar

**INTERPRETATION OF THE FINDINGS & FURTHER RECOMMENDATIONS**

**INVOICE**

43861

FNA of the splenic nodule warranted. The cause of collapse is not evident in this patient. Full CNS and orthopedic examination warranted. If suspicion of pathology in the CNS, thorax, or orthopedic regions is present, then CT of the region would be indicated.

**DATE**

7/7/23



**PATIENT**

Dunkin Bratton

**SPECIES**

Feline

**BREED**

DSH

**SEX**

Neutered Male

**AGE**

10

**WEIGHT**

14.7

**INTERPRETED BY**

Eric Lindquist, DMV  
DABVP, Cert. IVUSS

**IMAGING PERFORMED BY**

Jenn

**HOSPITAL NAME**

Rockaway AH

**REFERRING VET**

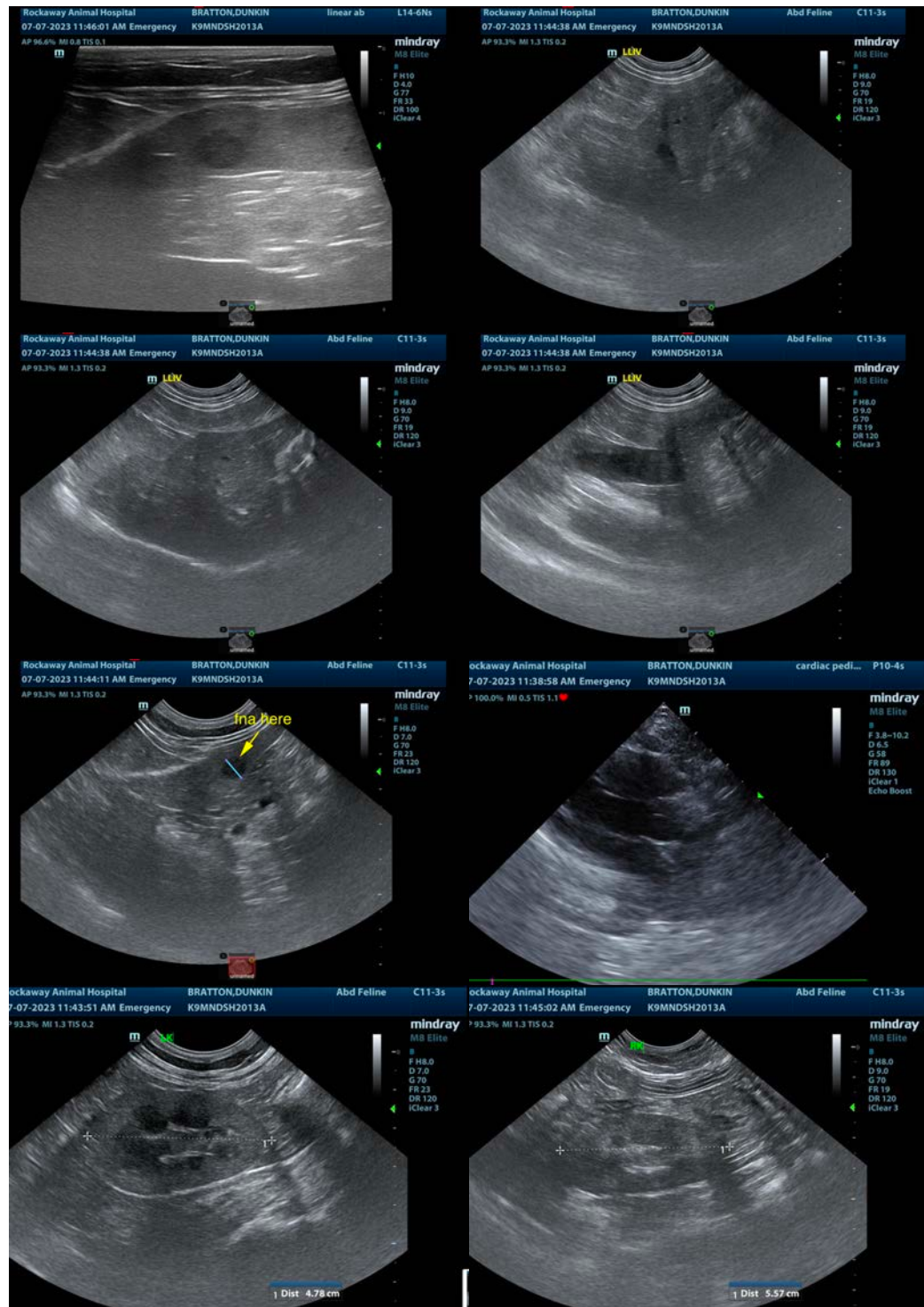
Dr. Maniar

**INVOICE**

43861

**DATE**

7/7/23





**PATIENT**

Dunkin Bratton

The information and recommendations provided are based on the images presented by the referring veterinarian/sonographer. No evaluation can be communicated regarding pathology that was not visible in the image/video clips provided.

**SPECIES**

Feline

Thank you for this referral. If the clinical or image interpretation does not parallel your findings or if I can be of any further assistance please contact me.

**Eric Lindquist**, DMV, DABVP, Cert. IVUSS, CEO of SonoPath.com

**BREED**

DSH

[info@SonoPath.com](mailto:info@SonoPath.com)

**SEX**

Neutered Male

**AGE**

10

**WEIGHT**

14.7

**INTERPRETED BY**

Eric Lindquist, DMV

DABVP, Cert. IVUSS

**IMAGING PERFORMED BY**

Jenn

**HOSPITAL NAME**

Rockaway AH

**REFERRING VET**

Dr. Maniar

**INVOICE**

43861

**DATE**

7/7/23