



PATIENT PRESENTING CLINICAL SIGNS

Tito Mann History: Went to the beach now lethargic decreased water intake radio opque material in small intestine on xray Prev Hx of heart dz on Vetmedin

SPECIES ULTRASONOGRAPHIC EXAMINATION OF THE ABDOMEN

Canine

Urinary System

BREED

Poodle

The **urinary bladder**, trigone, and pelvic urethra presented normal thicknesses and normal tone. The ureters were not visible which is normal. No uroliths or sediment were visualized and anechoic urine was present. No evidence of inflammatory or neoplastic changes was noted. Ureteral papillae were normal.

SEX

Neutered male

AGE

15 years

The **kidneys** revealed normal size and structure, corticomedullary definition and ratio for this age. The cortices presented largely uniform texture with normal echogenic relationship to liver and spleen. Medullary structure differed distinctly from the cortex and no evidence of pelvic dilation was present. The capsules were acceptably uniform without significant irregularities. The left kidney revealed an anechoic cyst that measured 2.0 cm at the caudal pole. Mildly increased cortical echogenicity was noted. Microcystic changes were noted elsewhere in the left kidney. The left kidney measured 4.7 cm. The right kidney measured 4.2 cm.

WEIGHT

10.8 lbs

Adrenal Glands

The left adrenal gland was enlarged and heterogenous measuring 2.21 x 0.75 cm at the caudal pole and 1.07 cm at the cranial pole. The right adrenal gland was small and isoechoic measuring 0.5 cm in width.

INTERPRETED BY

Eric Lindquist, DMV
DABVP, Cert. IVUSS

Spleen

IMAGING PERFORMED BY

Jenn

The **spleen** presented a smooth homogeneous parenchyma hyperechoic to liver and renal cortical parenchyma. The capsule was smooth without noticeable expansion or deviation from within the spleen or adjacent pathology. The splenic vasculature demonstrated normal volume without signs of congestion or thrombosis. No sonographic evidence of acute or chronic inflammatory, neoplastic, or infarctual changes was noted.

HOSPITAL NAME

Rockaway AH

Liver

REFERRING VET

Dr. Maniar

The **liver** images submitted revealed subjectively normal liver size, contour, and structure. Parenchymal echogenicity was naturally coarse and hypoechoic to the spleen. The hepatic veins were not dilated. The gallbladder presented acceptably thin walls with primarily anechoic content. The cystic and common bile ducts were normal. No pathological hepatic lymphadenopathy was evident. No overt structural evidence of inflammatory, infiltrative or regenerative pathology was evident.

INVOICE

45929

DATE

7/6/23



PATIENT

Gastrointestinal

Tito Mann

The **stomach** and upper small intestine was empty. A portion of jejunum appeared to be thickened with reactive mesentery. This is consistent with enteritis.

SPECIES

Canine

Pancreas

The base and limbs of the **pancreas** were observed to be largely isoechoic to surrounding omental fat. Pancreatic duct and capsular contour were acceptably normal and parenchyma respected normal curvilinear patterns. No overt evidence of active inflammatory or neoplastic disease was noted.

BREED

Poodle

SEX

Neutered male

ULTRASONOGRAPHIC EXAMINATION OF THE HEART

AGE

15 years

The echocardiogram in this patient demonstrated normal **left atrial** size based on 3 different LA measurement methods. Chamber volumes and echogenicity were normal. The cranial and caudal **mitral** valve leaflets presented vegetative thickening consistent with endocardiosis. Doppler indicated measurable insufficiency. The **left ventricle** presented thicknesses with linear contour and was not dilated nor restricted. The **myocardium** presented normal echogenicity without subjective evidence of significant fibrotic or ischemic disease. **Contractility** of the ventricular walls was adequate and in normal range for this patient evidenced by the fractional shortening measurement and subjective evaluation of the different regions of the myocardium. The **left ventricular outflow** tract demonstrated normal laminar flow and subjective structural integrity. The **right atrium** and auricle revealed normal size, structure and content. No evidence of masses was noted or chamber overload. **Tricuspid** valvular assessment demonstrated adequate linear morphology. The **right ventricle** was of normal size (1/3 diameter of LV), chordae structure, myocardial echogenicity and thickness. **Pulmonic** tract assessment revealed normal valve structure, laminar flow, and diameter (approx. 1:1 pa/ao ratio). No visible **pericardial** or free pleura fluid was noted. No echographically detectable evidence of infiltrative disease was visible. The cranial **mediastinum and pericardial regions** were free of masses in the visible window.

WEIGHT

10.8 lbs

INTERPRETED BY

Eric Lindquist, DMV
DABVP, Cert. IVUSS

IMAGING PERFORMED BY

Jenn

HOSPITAL NAME

Rockaway AH

REFERRING VET

Dr. Maniar

INVOICE

45929

DATE

7/6/23



PATIENT

Tito Mann

SPECIES

Canine

BREED

Poodle

SEX

Neutered male

AGE

15 years

WEIGHT

10.8 lbs

INTERPRETED BY

Eric Lindquist, DMV
DABVP, Cert. IVUSS

IMAGING PERFORMED BY

Jenn

HOSPITAL NAME

Rockaway AH

REFERRING VET

Dr. Maniar

INVOICE

45929

DATE

7/6/23

CANINE CARDIAC PARAMETERS	MR VMAX (m/s)	TR VMAX (m/s)	LA/AO (Boon method)	LA/AO (Heart Base;)	FS (%)	EF (%)	EPSS (cm)
NORMAL PARAMETER	4.5-5.5	<2.7	1.3	<1.6	28-40	40-100	<0.6
PATIENT			NM				0.1
CANINE CARDIAC PARAMETERS	HR (BPM)	AV VMAX (m/s)	PV MAX (m/s)	BODY WEIGHT (kg)	LA (2D short axis Base view) (cm)	LVIDd (Avg; 2D and m-mode short axis) (cm)	LVIDs (Avg; 2D and m-mode short axis) (cm)
NORMAL PARAMETER	50-100	0.7-1.7	0.7-1.6	BELOW	BELOW	BELOW	BELOW
PATIENT		1.0	0.5	10.8 lbs			

ULTRASONOGRAPHIC FINDINGS

BB1 valvular disease.

Enlarged, heterogenous left adrenal gland. Hyperplasia, carcinoma, pheochromocytoma are all possible.

Polycystic kidneys.

Minor enteritis pattern.

INTERPRETATION OF THE FINDINGS & FURTHER RECOMMENDATIONS

No cardiac therapy is recommended at this time. If hypertension is an issue then evaluation of urine catecholamine is indicated. Supportive care should prove effective. Broad spectrum antibiotics and IV fluid support (with caution given the cardiac disease) is recommended. Full urinary work-up is warranted given the chronic renal changes. Recheck sonogram is recommended in a week to assess for any progression or regression.



PATIENT

Tito Mann

SPECIES

Canine

BREED

Poodle

SEX

Neutered male

AGE

15 years

WEIGHT

10.8 lbs

INTERPRETED BY

Eric Lindquist, DMV
DABVP, Cert. IVUS

IMAGING PERFORMED BY

Jenn

HOSPITAL NAME

Rockaway AH

REFERRING VET

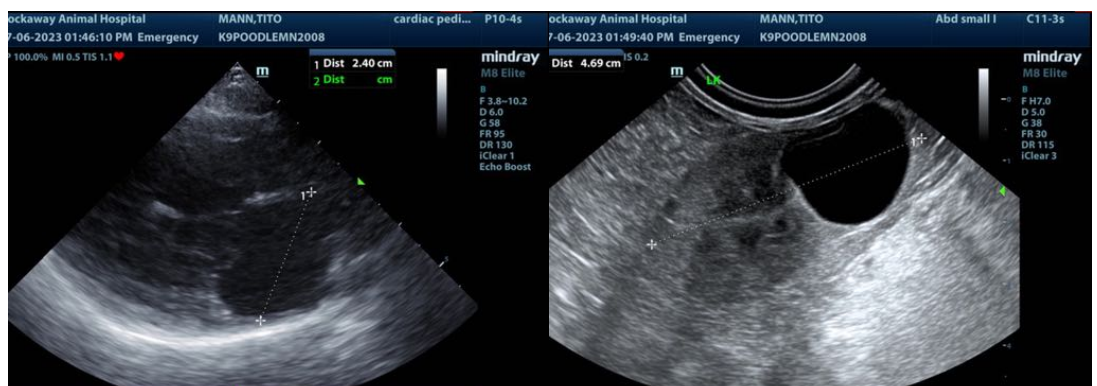
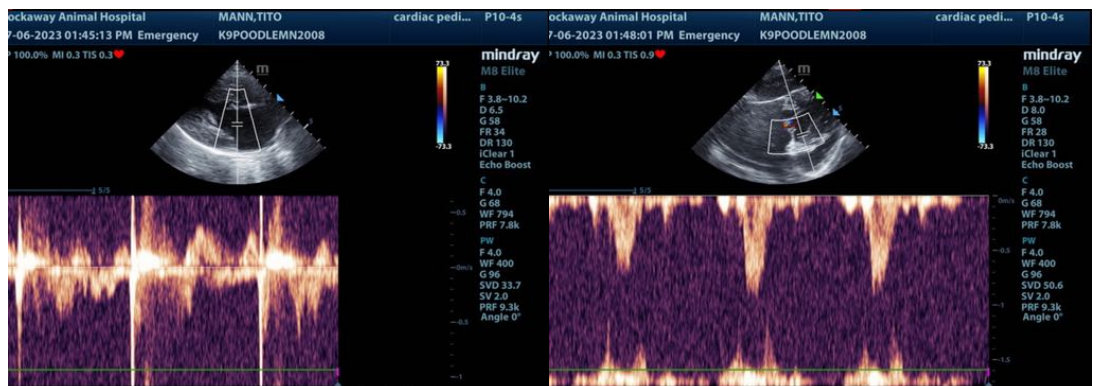
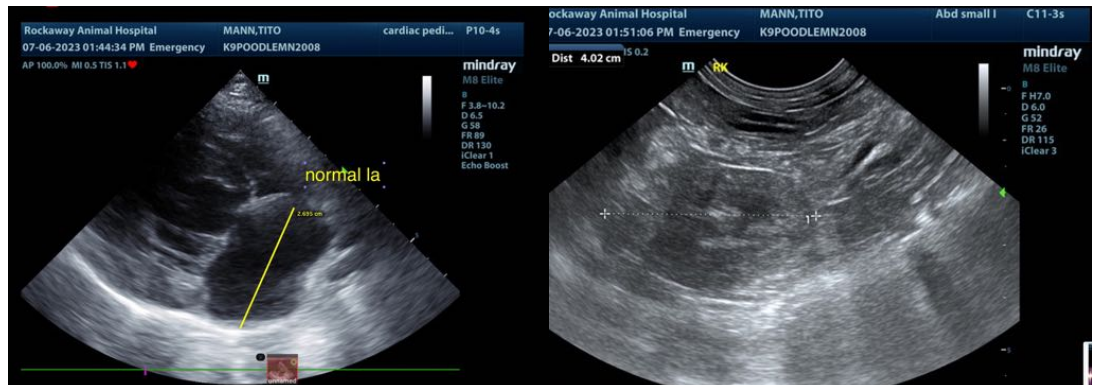
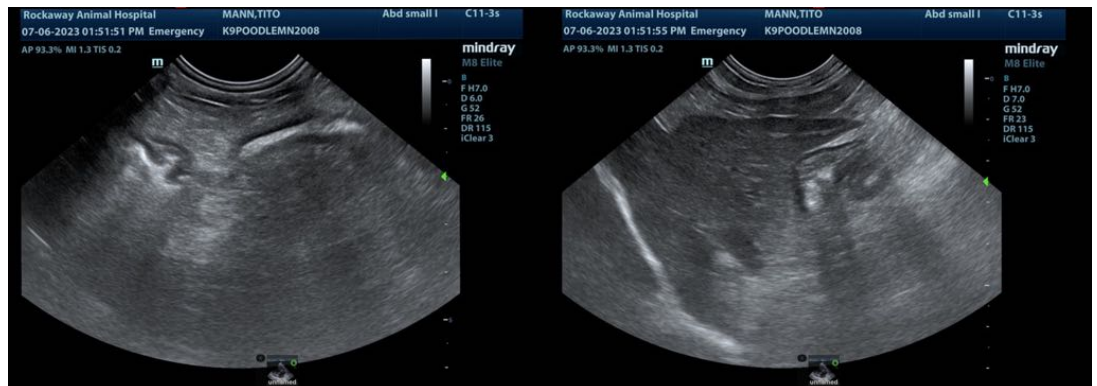
Dr. Maniar

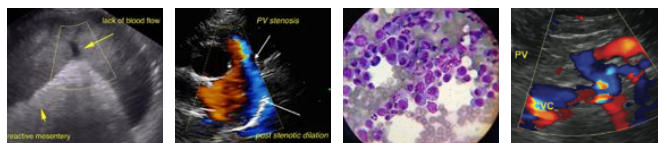
INVOICE

45929

DATE

7/6/23





PATIENT

Tito Mann

SPECIES

Canine

BREED

Poodle

SEX

Neutered male

AGE

15 years

WEIGHT

10.8 lbs

INTERPRETED BY

Eric Lindquist, DMV
DABVP, Cert. IVUSS

**IMAGING
PERFORMED BY**

Jenn

HOSPITAL NAME

Rockaway AH

REFERRING VET

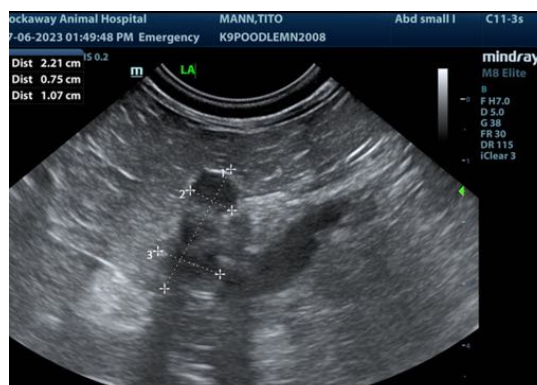Dr. Maniar

INVOICE

45929

DATE

7/6/23



The information and recommendations provided are based on the images presented by the referring veterinarian/sonographer. No evaluation can be communicated regarding pathology that was not visible in the image/video clips provided.

Thank you for this referral. If the clinical or image interpretation does not parallel your findings or if I can be of any further assistance please contact me.

Eric Lindquist, DMV, DABVP, Cert. IVUSS, CEO of SonoPath.com
info@SonoPath.com