



PATIENT PRESENTING CLINICAL SIGNS

Theo Artinian

Patient presents with possible tracheal collapse, bronchial collapse, enlarged heart, and a grade 3/6 heart murmur. Current meds: Hydroxyzine 10 mgs and Theophylline 100 mgs.

SPECIES

Canine

Abnormal PE/Chem/CBC/UA Results: Chem: ALT 129, T4 0.9. CBC: WNL.

BREED

Maltese

ULTRASONOGRAPHIC EXAMINATION OF THE HEART & ABDOMEN

SEX

Neutered Male

AGE

9 Years

WEIGHT

11.6 Pounds

CANINE CARDIAC PARAMETERS	MR VMAX (m/s)	TR VMAX (m/s)	LA/AO (Boon method)	LA/AO (Heart Base; Swe)	FS (%)	EF (%)	EPSS (cm)
NORMAL PARAMETER	4.5-5.5	<2.7	1.3	<1.6	28-40	40-100	<0.6
PATIENT	5.8		NM	2.0	50	83	NM
CANINE CARDIAC PARAMETERS	HR (BPM)	AV VMAX (m/s)	PV MAX (m/s)	BODY WEIGHT (kg)	LA 2D short axis Base view (cm)	LVIDd Avg; 2D and m-mode short axis (cm)	LVIDs Avg; 2D and m-mode short axis (cm)
NORMAL PARAMETER	50-100	0.7-1.7	0.7-1.6	BELOW	BELOW	BELOW	BELOW
PATIENT	140	1.18	0.9		3.36	3.01	

INTERPRETED BY

Eric Lindquist, DMV

DABVP, Cert. IVUSS

Cardiac Presentation

IMAGING PERFORMED BY

Kelly Vazquez

HOSPITAL NAME

Animal Paradise Hospital

REFERRING VET

Dr. Mostafa ElShafie

INVOICE

43828

DATE

7/6/23

Urinary System

The urinary bladder, trigone, and pelvic urethra presented normal thicknesses and normal tone. The ureters were not visible which is normal. No uroliths or sediment were visualized and anechoic urine was present. No evidence of inflammatory or neoplastic changes were noted. Ureteral papillae were normal.



PATIENT The prostate was uniform at 1.67 cm.

Theo Artinian

The **kidneys** revealed largely normal size and structure, corticomedullary definition and ratio (cortex 1/3 of medulla) were essentially maintained with some age-related loss of curvilinear patterns regarding the capsule and C/M junction. The cortices presented largely uniform texture with some increased echogenicity expected for his age patient. Medullary structure differed distinctly from that of the cortex and no evidence of pelvic dilation was present. The right kidney measured 4.11 cm. The left kidney measured 4.82 cm.

SPECIES

Canine

BREED

Maltese

Adrenal Glands

Both **adrenal glands** were visualized and recognized as having normal shape, size, position and echogenicity for this breed. The phrenic vasculature, glandular echogenicity and detail were unremarkable. Capsule, cortex, and medullary definition were normal for this age patient. The left adrenal gland measured 1.4 cm x 0.44 cm at the caudal pole and 0.47 cm at the cranial pole.

SEX

Neutered Male

AGE

9 Years

Spleen

The **spleen** presented a smooth homogeneous parenchyma hyperechoic to liver and renal cortical parenchyma. The capsule was smooth without noticeable expansion or deviation from within the spleen or adjacent pathology. The splenic vasculature demonstrated normal volume without signs of congestion or thrombosis. No sonographic evidence of acute or chronic inflammatory, neoplastic, or infarctual changes were noted.

WEIGHT

11.6 Pounds

Liver

The **liver** images from right and left intercostal as well as subcostal views revealed subjectively normal liver size, contour, and structure. Some age-related parenchymal remodeling was noted but likely not clinically significant at this time. Vascular and biliary tracts were of normal volume and no evidence of congestion was noted. The gallbladder presented some dependent debris with essentially normal contour. The cystic and common bile ducts were normal. No overt evidence of active inflammatory, infiltrative or regenerative pathology was noted but should be paired with current or past LE elevations regarding any clinical significance to this presentation. The hepatic lymph nodes were unremarkable.

INTERPRETED BY

Eric Lindquist, DMV

DABVP, Cert. IVUSS

Comet tail lung pattern noted through the diaphragm, indicative of alveolar disease.

Gastrointestinal

Examination of the **gastrointestinal tract** revealed a stomach and intestine free of stasis, of normal wall thickness, acceptable curvilinear mural detail, and peristaltic activity. Small and large intestine demonstrated normal luminal chyme and stool consistency respectively. No obstructive or overt infiltrative disease was noted. No associated abnormal lymphatic activity was noted.

IMAGING PERFORMED BY

Kelly Vazquez

HOSPITAL NAME

Animal Paradise Hospital

REFERRING VET

Dr. Mostafa ElShafie

INVOICE

43828

DATE

7/6/23

Pancreas

The base and limbs of the **pancreas** were observed to be largely isoechoic to surrounding omental fat. Pancreatic duct and capsular contour were acceptably normal and parenchyma respected normal curvilinear patterns. No overt evidence of active inflammatory or neoplastic disease was noted.



PATIENT

Theo Artinian

SPECIES

Canine

BREED

Maltese

SEX

Neutered Male

AGE

9 Years

WEIGHT

11.6 Pounds

ULTRASONOGRAPHIC FINDINGS

- Mitral insufficiency with left atrial enlargement, advanced stage B2+ valvular disease with comet tail lung, potential pulmonary edema versus bronchoalveolar disease.
- Non-specific hepatopathy, not pathological
- Age related renal changes

INTERPRETATION OF THE FINDINGS & FURTHER RECOMMENDATIONS

Chest radiographs warranted. Recommend Pimobendan 0.3 mg/kg BID. ACE inhibitor 0.5 mg/kg SID progressing to BID and Spironolactone at 1-2 mg/kg BID could be considered, yet no consensus on its use at this stage. If pulmonary edema is present, then additional Lasix could be considered at 1-2 mg/kg BID.

The heart has some volume overload and is working to compensate for the valvular insufficiency. Target respiratory rate is < 20 resp/minute after therapy. After initiating therapy, I recommend recheck on the clinical exam, BUN, Creatinine, USG, Chest radiographs & Blood pressure in 5-7 days. Recheck echo in 1 month. Earlier if clinical decompensation is occurring. I do not recommend anesthesia at this time until stabilization has occurred on the recommended medications. Repeat preanesthetic echo is ideal if anesthesia is eventually necessary. There is moderate anesthetic risk for this patient. I recommend cardiac treatment prior to sedation unless only light opioids are utilized which would have minimal effect on heart function.

INTERPRETED BY

Eric Lindquist, DMV

DABVP, Cert. IVUSS

IMAGING PERFORMED BY

Kelly Vazquez

HOSPITAL NAME

Animal Paradise Hospital

REFERRING VET

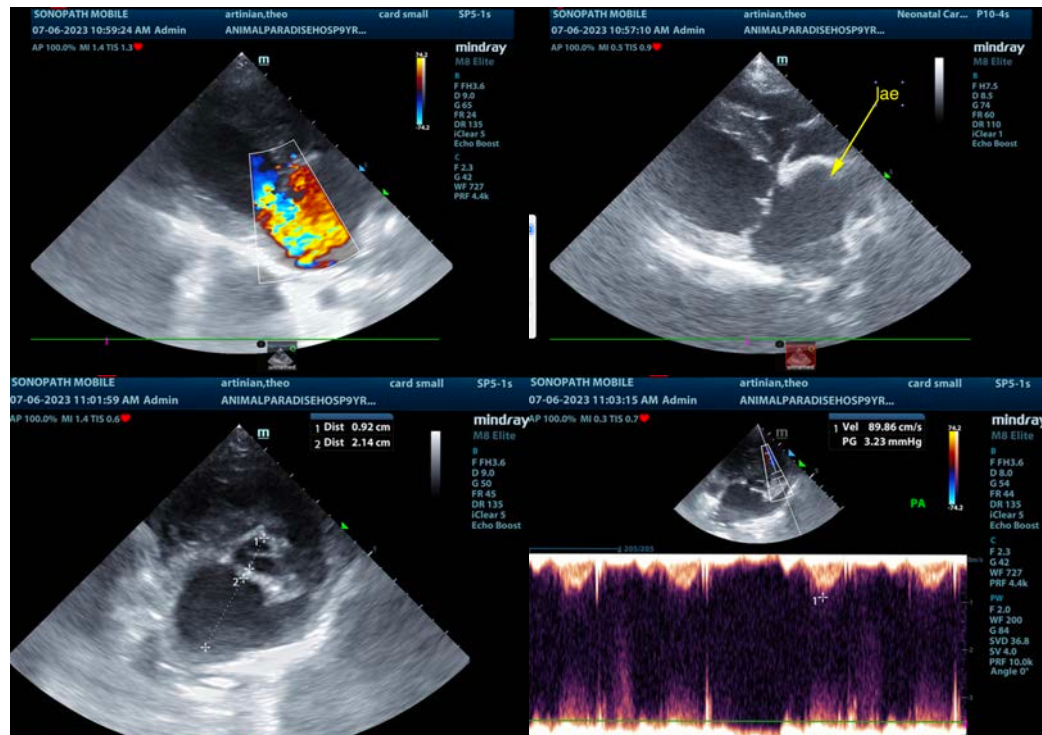
Dr. Mostafa ElShafie

INVOICE

43828

DATE

7/6/23





PATIENT

Theo Artinian

SPECIES

Canine

BREED

Maltese

SEX

Neutered Male

AGE

9 Years

WEIGHT

11.6 Pounds

INTERPRETED BY

Eric Lindquist, DMV
DABVP, Cert. IVUSS

IMAGING PERFORMED BY

Kelly Vazquez

HOSPITAL NAME

Animal Paradise
Hospital

REFERRING VET

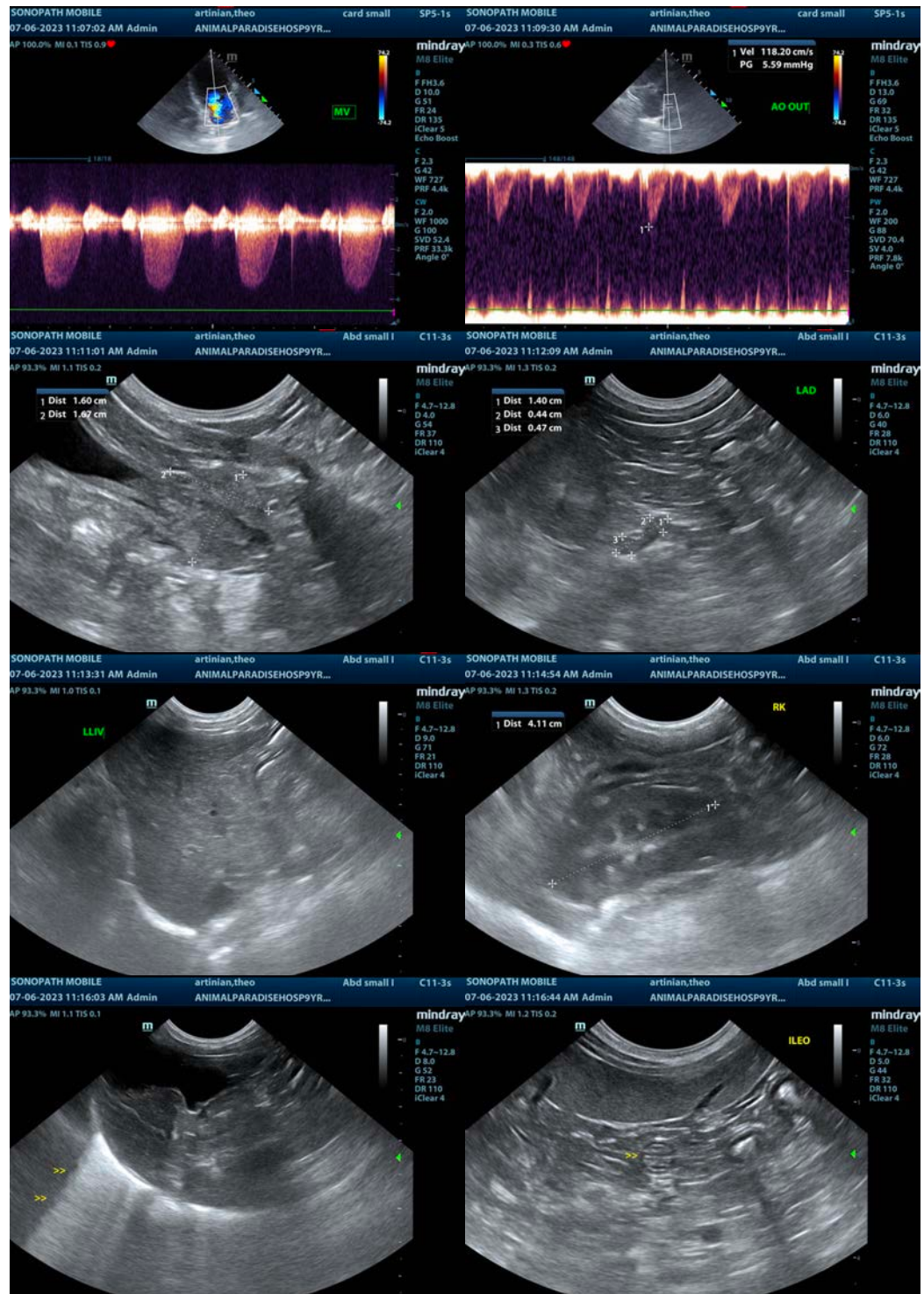
Dr. Mostafa ElShafie

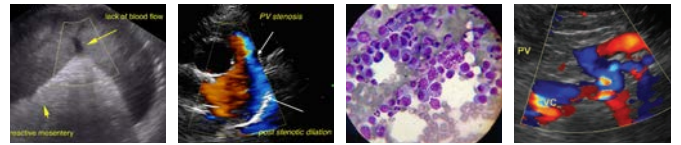
INVOICE

43828

DATE

7/6/23





PATIENT

Theo Artinian

SPECIES

Canine

BREED

Maltese

SEX

Neutered Male

AGE

9 Years

WEIGHT

11.6 Pounds

INTERPRETED BY

Eric Lindquist, DMV

DABVP, Cert. IVUSS

IMAGING PERFORMED BY

Kelly Vazquez

HOSPITAL NAME

Animal Paradise
Hospital

REFERRING VET

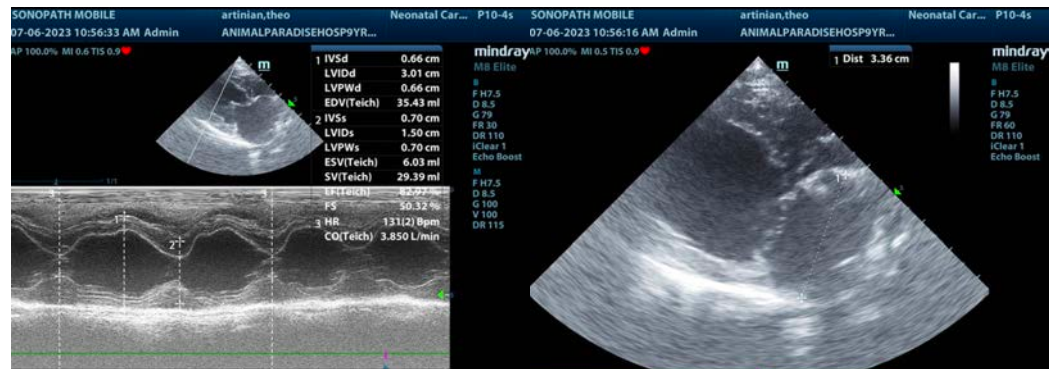
Dr. Mostafa ElShafie

INVOICE

43828

DATE

7/6/23



The information and recommendations provided are based on the images presented by the referring veterinarian/sonographer. No evaluation can be communicated regarding pathology that was not visible in the image/video clips provided.

Thank you for this referral. If the clinical or image interpretation does not parallel your findings or if I can be of any further assistance please contact me.

Eric Lindquist, DMV, DABVP, Cert. IVUSS, CEO of SonoPath.com

info@SonoPath.com