



**PATIENT**

Robbie Birch

**PRESENTING CLINICAL SIGNS**

History: isolating, decreased appetite, vomiting clear liquid lethargic  
Abnormal PE/Chem/CBC/UA Results: increased BUN Crea ALT

**SPECIES**

Feline

**ULTRASONOGRAPHIC EXAMINATION OF THE ABDOMEN**

**Urinary System**

**BREED**

American Shorthair

The **urinary bladder**, trigone, and pelvic urethra presented normal thicknesses and normal tone. The ureters were not visible which is normal. No uroliths or sediment were visualized and anechoic urine was present. No evidence of inflammatory or neoplastic changes was noted. Ureteral papillae were normal.

**SEX**

Neutered male

The **kidneys** presented a relatively uniform cortical hyperechogenicity when compared to the renal medulla, spleen and liver. No overt masses were noted. Corticomedullary definition was nebulous and the ratio favored the cortex slightly. The ureters were not visible and assumed to be normal. These changes are most consistent with chronic interstitial nephritis yet infiltrative disease could not be entirely ruled out without biopsy though neoplasia is not suspected. The left kidney measured 3.11 cm. The right kidney measured 3.66 cm.

**AGE**

19 years

**WEIGHT**

9.4 lbs

**Adrenal Glands**

Both **adrenal glands** were visualized and recognized as having normal shape, size, position and echogenicity for this breed. The phrenic vasculature, glandular echogenicity and detail were unremarkable. Capsule, cortex, and medullary definition were normal for this age patient.

**INTERPRETED BY**

Eric Lindquist, DMV  
DABVP, Cert. IVUSS

**Spleen**

**IMAGING PERFORMED BY**

Jenn

The **spleen** presented a smooth homogeneous parenchyma hyperechoic to liver and renal cortical parenchyma. The capsule was smooth without noticeable expansion or deviation from within the spleen or adjacent pathology. The splenic vasculature demonstrated normal volume without signs of congestion or thrombosis. No sonographic evidence of acute or chronic inflammatory, neoplastic, or infarctual changes was noted.

**HOSPITAL NAME**

Rockaway AH

**Liver**

**REFERRING VET**

Dr. Maniar

The **liver** revealed multi-focal, nodular changes measuring up to 1.4 cm. The gallbladder and common bile duct were unremarkable. A minor amount of gallbladder sand was noted.

**INVOICE**

45926

**Gastrointestinal**

**DATE**

7/6/23

Examination of the **gastrointestinal tract** revealed a stomach and intestine free of stasis, of normal wall thickness, acceptable curvilinear mural detail, and peristaltic activity. Small and large intestine demonstrated normal luminal chyme and stool consistency respectively. No obstructive or overt infiltrative disease was noted. No associated abnormal lymphatic activity was noted.



**PATIENT**

Robbie Birch

**SPECIES**

Feline

**BREED**

American Shorthair

**SEX**

Neutered male

**AGE**

19 years

**WEIGHT**

9.4 lbs

**INTERPRETED BY**

Eric Lindquist, DMV  
DABVP, Cert. IVUSS

**IMAGING PERFORMED BY**

Jenn

**HOSPITAL NAME**

Rockaway AH

**REFERRING VET**

Dr. Maniar

**INVOICE**

45926

**DATE**

7/6/23

**Pancreas**

The base and limbs of the **pancreas** were observed to be largely isoechoic to surrounding omental fat. Some parenchymal remodeling, however, with mild deviation from curvilinear normalcy was observed. Pancreatic duct and capsular irregularities were present consistent with age related changes. If pain upon imaging (+ Murphy sign) was present or if the patient is focally painful in subxiphoid palpation then low-grade smoldering chronic pancreatitis should be suspected.

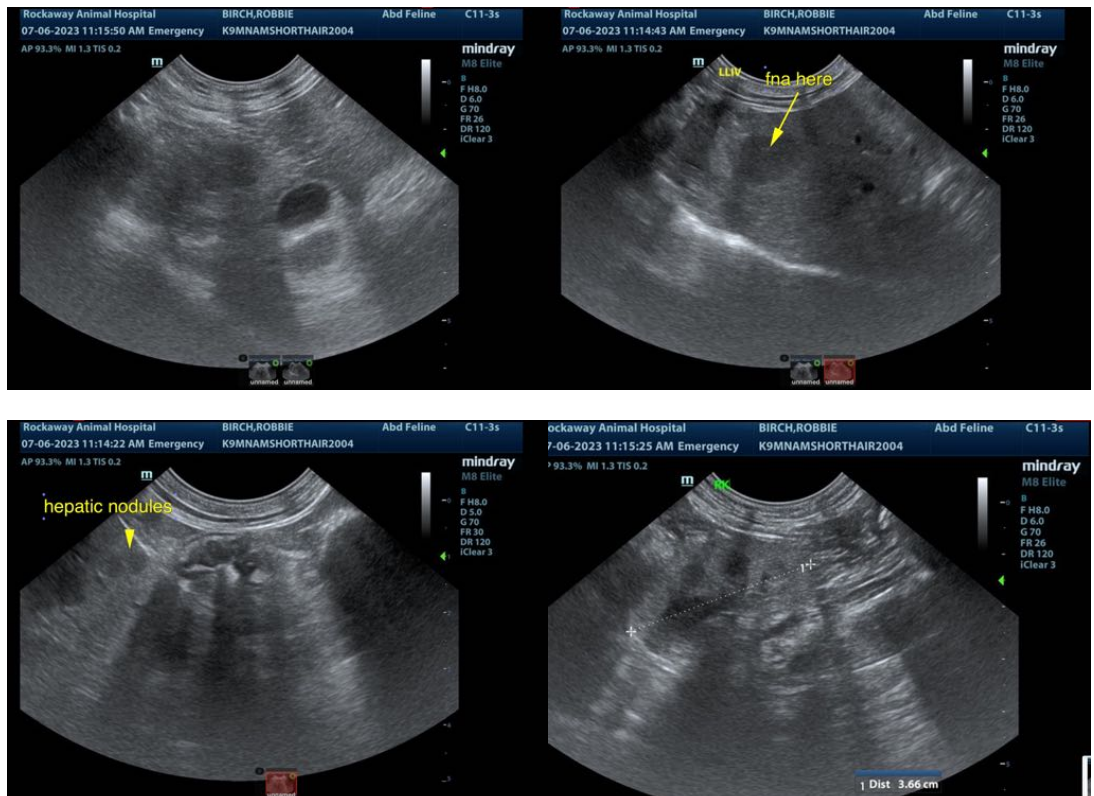
**ULTRASONOGRAPHIC FINDINGS**

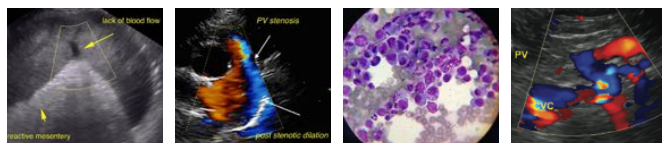
Multi-focal, hepatic nodules, strong concern for round cell neoplasia or metastatic disease.

Otherwise, geriatric abdomen.

**INTERPRETATION OF THE FINDINGS & FURTHER RECOMMENDATIONS**

FNA of the liver is indicated. Nodular hyperplasia is possible, yet less likely. Suppurative hepatitis is also possible. Cytology and culture are ideal.





**PATIENT**

Robbie Birch

**SPECIES**

Feline

**BREED**

American Shorthair

**SEX**

Neutered male

**AGE**

19 years

**WEIGHT**

9.4 lbs

**INTERPRETED BY**

Eric Lindquist, DMV  
DABVP, Cert. IVUSS

**IMAGING  
PERFORMED BY**

Jenn

**HOSPITAL NAME**

Rockaway AH

**REFERRING VET**

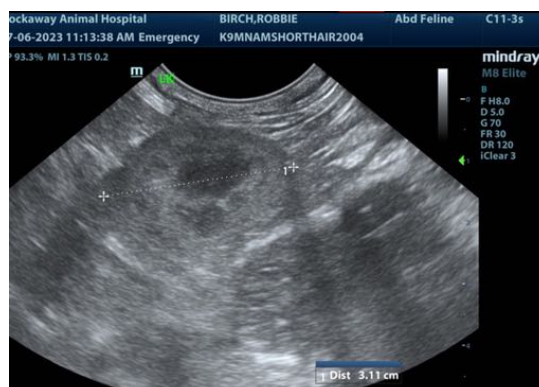
Dr. Maniar

**INVOICE**

45926

**DATE**

7/6/23



The information and recommendations provided are based on the images presented by the referring veterinarian/sonographer. No evaluation can be communicated regarding pathology that was not visible in the image/video clips provided.

Thank you for this referral. If the clinical or image interpretation does not parallel your findings or if I can be of any further assistance please contact me.

**Eric Lindquist**, DMV, DABVP, Cert. IVUSS, CEO of SonoPath.com  
info@SonoPath.com