



PATIENT PRESENTING CLINICAL SIGNS

PATIENT
Lola Waterfield
History: clinically normal
Abnormal PE/Chem/CBC/UA Results: Obese Elevated ALT (214) ALKP (1922) have been tracking since March 2023 when noted at dental

SPECIES

Canine

BREED

Labrador

SEX

Spayed female

AGE

9 years

WEIGHT

36 kg

INTERPRETED BY

Eric Lindquist, DMV
DABVP, Cert. IVUSS

IMAGING PERFORMED BY

Dr. Goeres

HOSPITAL NAME

Keowna VH

REFERRING VET

Dr. Jenner

INVOICE

75954

DATE

7/6/23

ULTRASONOGRAPHIC EXAMINATION OF THE ABDOMEN

Urinary System

The **urinary bladder**, trigone, and pelvic urethra presented normal thicknesses and normal tone. The ureters were not visible which is normal. No uroliths or sediment were visualized and anechoic urine was present. No evidence of inflammatory or neoplastic changes was noted. Ureteral papillae were normal.

The **kidneys** revealed normal size and structure, corticomedullary definition and ratio for this age. The cortices presented largely uniform texture with normal echogenic relationship to liver and spleen. Medullary structure differed distinctly from the cortex and no evidence of pelvic dilation was present. The capsules were acceptably uniform without significant irregularities. The left kidney measured 7.13 cm. The right kidney measured 7.15 cm.

Adrenal Glands

The right **adrenal gland** was visualized and recognized as having normal shape, size, position and echogenicity for this breed. The phrenic vasculature, glandular echogenicity and detail were unremarkable. Capsule, cortex, and medullary definition were normal for this age patient. The right adrenal gland measured 0.6 cm. The region of the left adrenal gland was unremarkable.

Spleen

The **spleen** presented a smooth homogeneous parenchyma hyperechoic to liver and renal cortical parenchyma. The capsule was smooth without noticeable expansion or deviation from within the spleen or adjacent pathology. The splenic vasculature demonstrated normal volume without signs of congestion or thrombosis. No sonographic evidence of acute or chronic inflammatory, neoplastic, or infarctual changes was noted.

Liver

Exam of the cranial abdomen demonstrated excessive **liver** size and swollen contour. Mild, coarse architecture was noted with increased portal markings and minor parenchymal remodeling is suggestive of an inflammatory component. Minor excessive GB debris was noted with the presence gall bladder dilation and precipitate without the overt formation of mucocele but this may be an issue in the future. This type of liver presentation typically is associated with slow and gradual SAP elevations with low-grade ALT rise. USG-FNA sampling is encouraged if more aggressive LE profiles are present such as ALT > 200 or rapid rise in SAP. These presentations are usually reactive hepatopathies owing to other disease processes either endocrine (Diabetes, Hypothyroidism, Cushing's disease), "antigen surveillance" from the gut/pancreas, or idiopathic breed predisposed progressions.



PATIENT

Lola Waterfield

SPECIES

Canine

BREED

Labrador

SEX

Spayed female

AGE

9 years

WEIGHT

36 kg

INTERPRETED BY

Eric Lindquist, DMV
DABVP, Cert. IVUSS

**IMAGING
PERFORMED BY**

Dr. Goeres

HOSPITAL NAME

Keowna VH

REFERRING VET

Dr. Jenner

INVOICE

75954

DATE

7/6/23

Gastrointestinal

Examination of the **gastrointestinal tract** revealed a stomach and intestine free of stasis, of normal wall thickness, acceptable curvilinear mural detail, and peristaltic activity. Small and large intestine demonstrated normal luminal chyme and stool consistency respectively. No obstructive or overt infiltrative disease was noted. No associated abnormal lymphatic activity was noted.

Pancreas

The base and limbs of the **pancreas** were observed to be largely isoechoic to surrounding omental fat. Pancreatic duct and capsular contour were acceptably normal and parenchyma respected normal curvilinear patterns. No overt evidence of active inflammatory or neoplastic disease was noted.

ULTRASONOGRAPHIC FINDINGS

Structurally unremarkable abdomen.

Minor hepatic remodeling, consistent with history of inflammatory hepatopathy.

Gallbladder sludge.

INTERPRETATION OF THE FINDINGS & FURTHER RECOMMENDATIONS

FNA of the liver can be considered for further definition. Treatment should be based on cytology results. Possible reactive hepatopathy or low-grade inflammatory hepatopathy, subjectively appears benign.



PATIENT

Lola Waterfield

SPECIES

Canine

BREED

Labrador

SEX

Spayed female

AGE

9 years

WEIGHT

36 kg

INTERPRETED BY

Eric Lindquist, DMV
DABVP, Cert. IVUS

IMAGING PERFORMED BY

Dr. Goeres

HOSPITAL NAME

Keowna VH

REFERRING VET

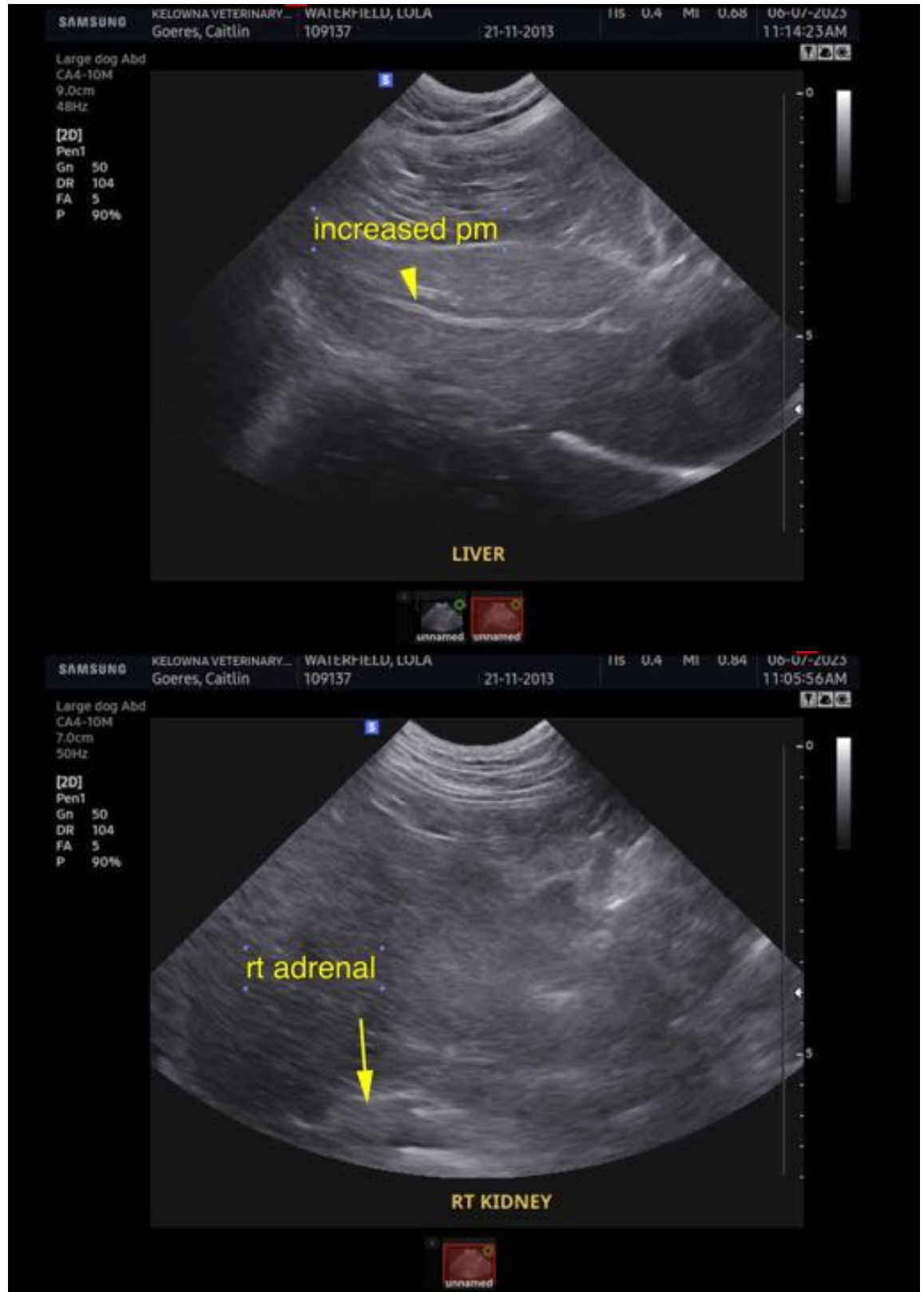
Dr. Jenner

INVOICE

75954

DATE

7/6/23





PATIENT

Lola Waterfield

SPECIES

Canine

BREED

Labrador

SEX

Spayed female

AGE

9 years

WEIGHT

36 kg

INTERPRETED BY

Eric Lindquist, DMV
DABVP, Cert. IVUSS

IMAGING PERFORMED BY

Dr. Goeres

HOSPITAL NAME

Keowna VH

REFERRING VET

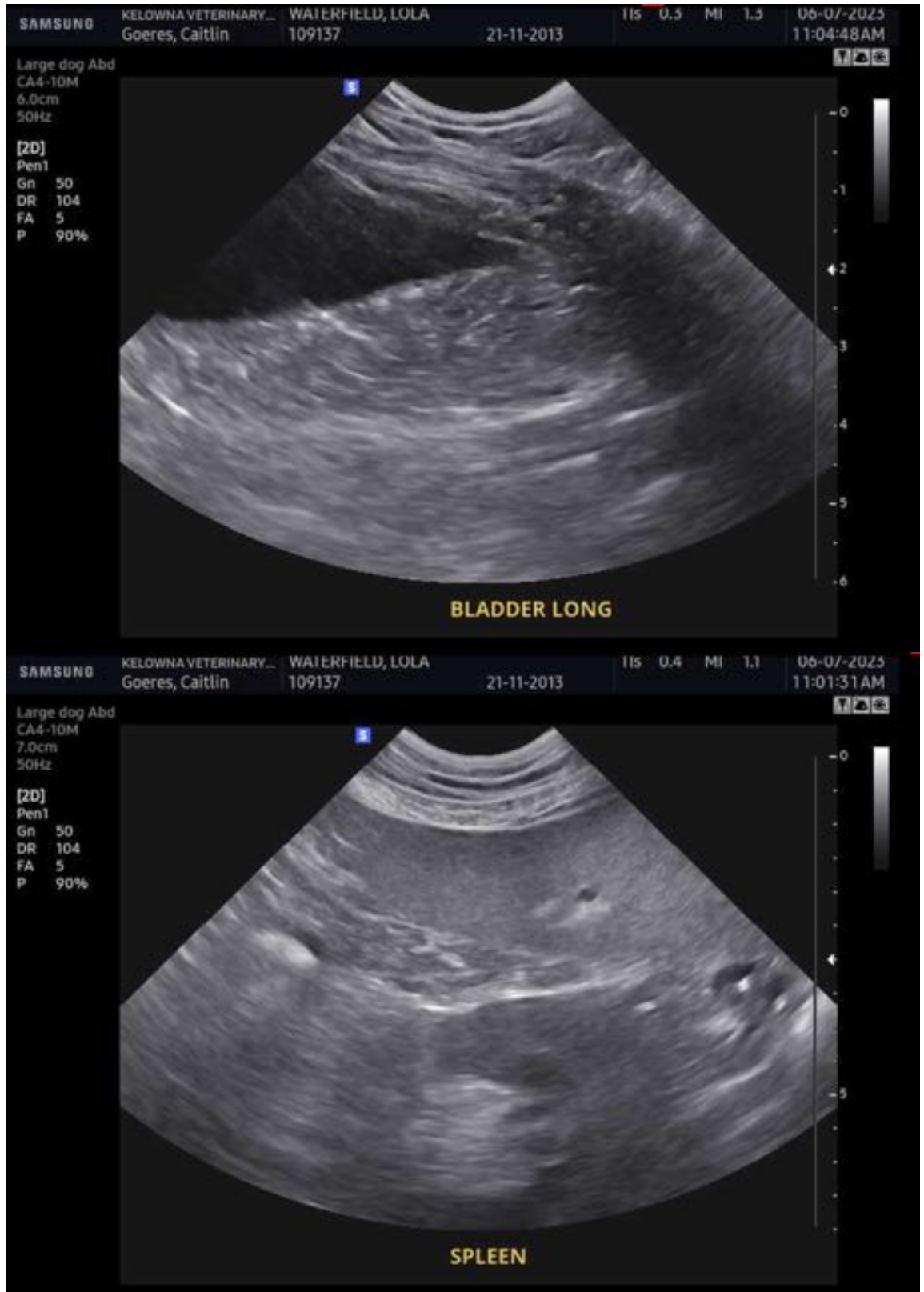
Dr. Jenner

INVOICE

75954

DATE

7/6/23





PATIENT

Lola Waterfield

SPECIES

Canine

BREED

Labrador

SEX

Spayed female

AGE

9 years

WEIGHT

36 kg

INTERPRETED BY

Eric Lindquist, DMV
DABVP, Cert. IVUSS

IMAGING PERFORMED BY

Dr. Goeres

HOSPITAL NAME

Keowna VH

REFERRING VET

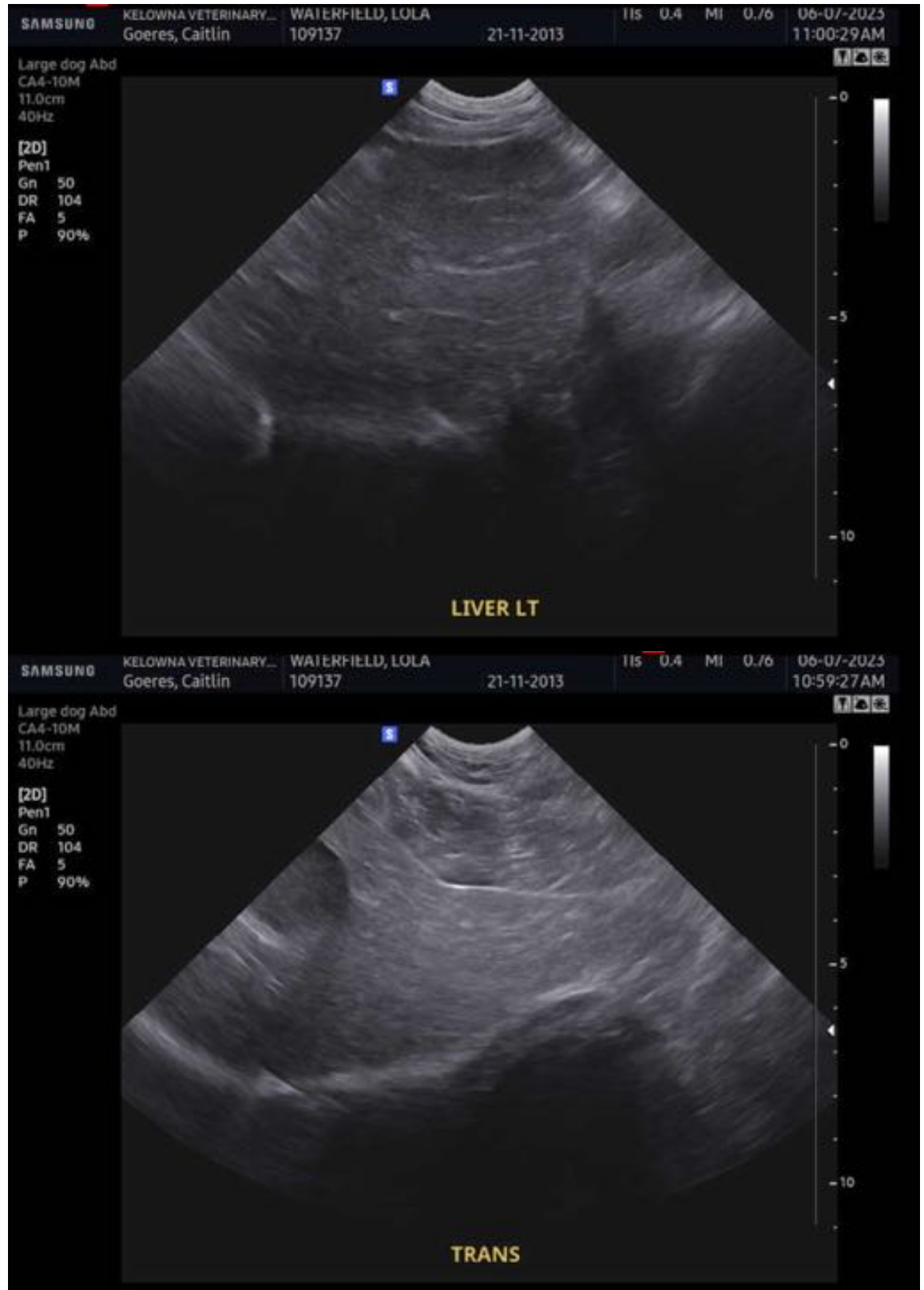Dr. Jenner

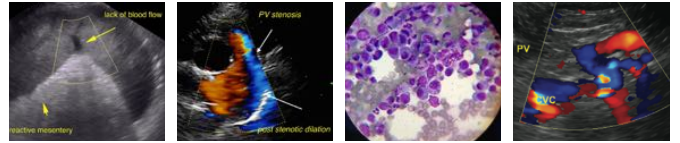
INVOICE

75954

DATE

7/6/23





PATIENT

Lola Waterfield

SPECIES

Canine

BREED

Labrador

SEX

Spayed female

AGE

9 years

WEIGHT

36 kg

INTERPRETED BY

Eric Lindquist, DMV
DABVP, Cert. IVUSS

IMAGING PERFORMED BY

Dr. Goeres

HOSPITAL NAME

Keowna VH

REFERRING VET

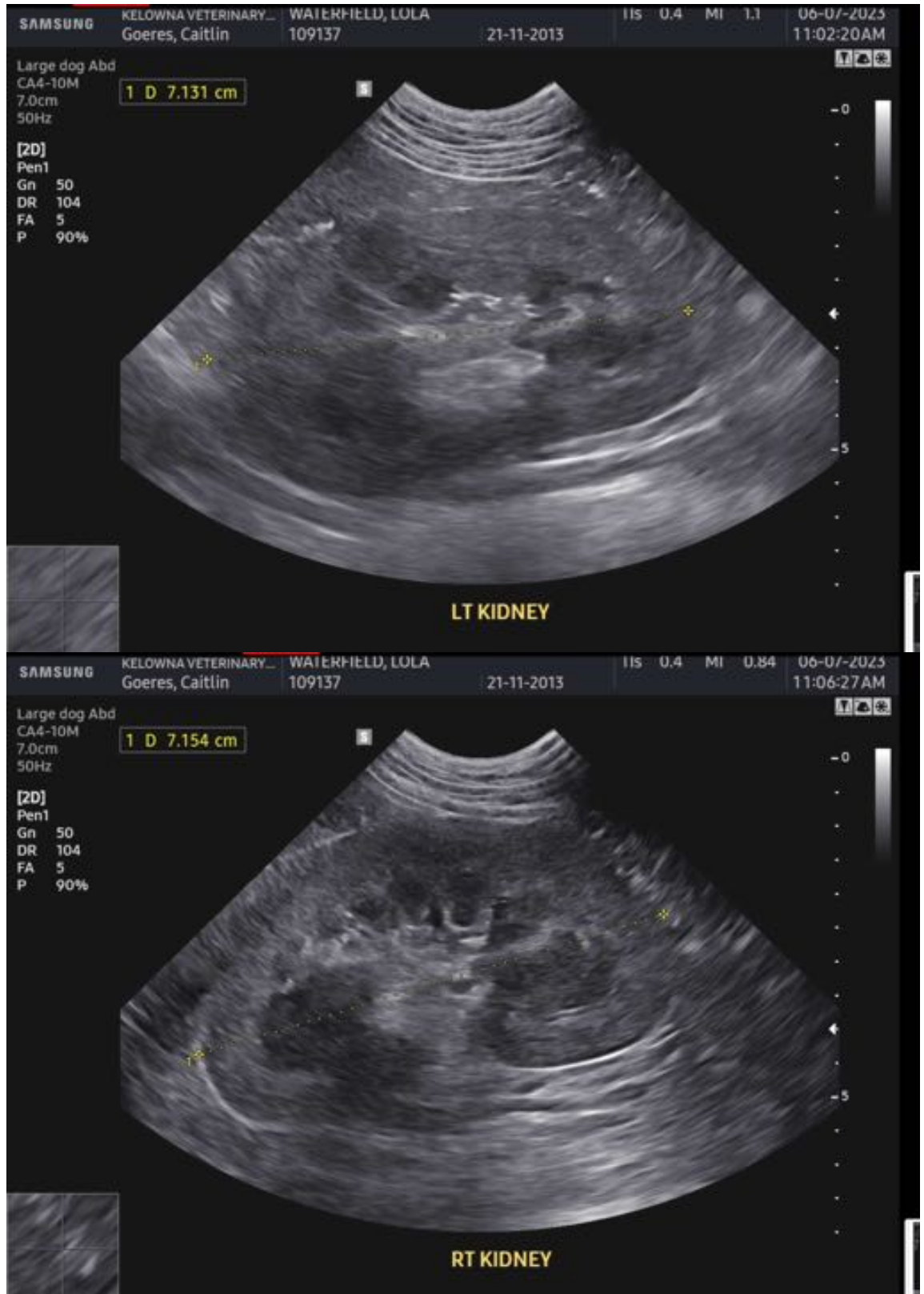
Dr. Jenner

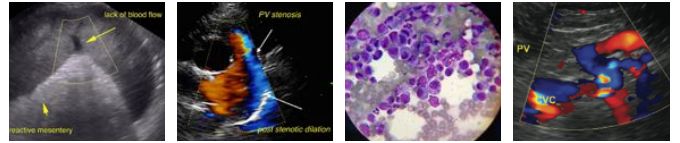
INVOICE

75954

DATE

7/6/23





PATIENT

Lola Waterfield

SPECIES

Canine

BREED

Labrador

SEX

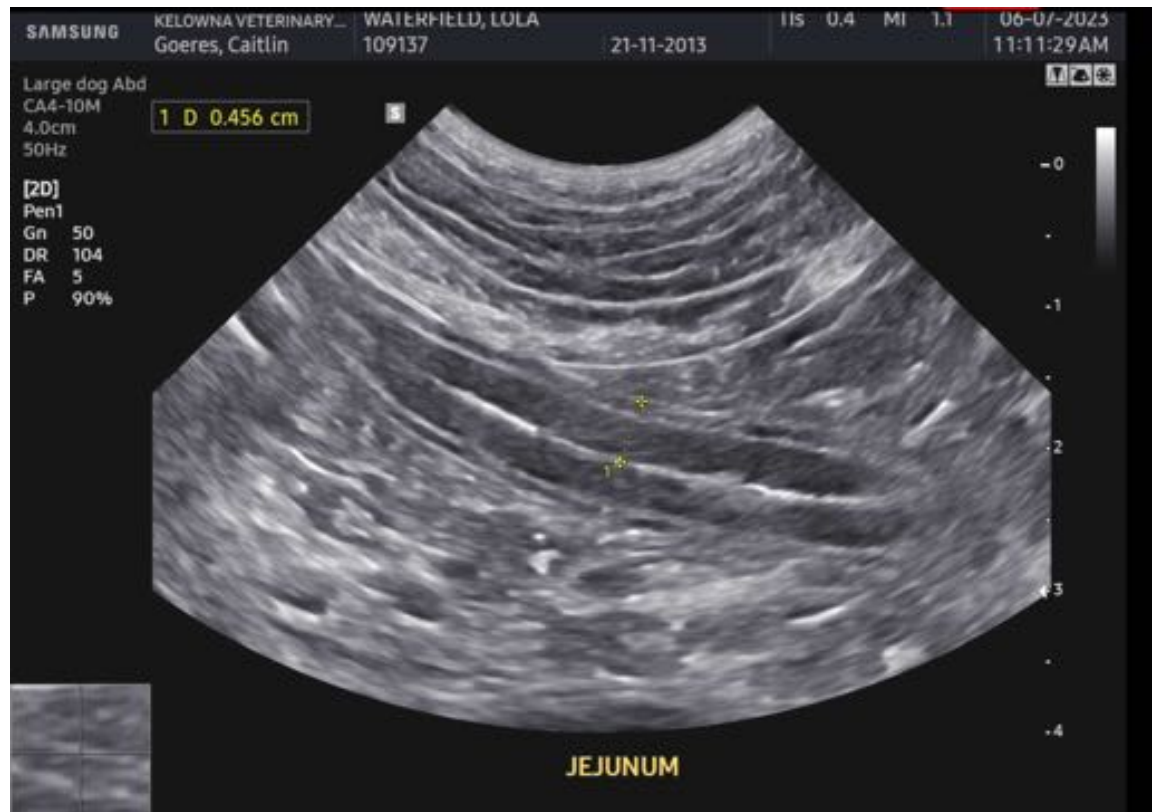Spayed female

AGE

9 years

WEIGHT

36 kg



INTERPRETED BY

Eric Lindquist, DMV
DABVP, Cert. IVUSS

IMAGING PERFORMED BY

Dr. Goeres

HOSPITAL NAME

Keowna VH

REFERRING VET

Dr. Jenner

INVOICE

75954

DATE

7/6/23

The information and recommendations provided are based on the images presented by the referring veterinarian/sonographer. No evaluation can be communicated regarding pathology that was not visible in the image/video clips provided.

Thank you for this referral. If the clinical or image interpretation does not parallel your findings or if I can be of any further assistance please contact me.

Eric Lindquist, DMV, DABVP, Cert. IVUSS, CEO of SonoPath.com
info@SonoPath.com