


PATIENT

Korben Tomasicchio

SPECIES

Canine

BREED

Chihuahua Mix

SEX

Neutered male

AGE

9 years

WEIGHT

8.6 lbs

INTERPRETED BY

 Eric Lindquist, DMV
 DABVP, Cert. IVUSS

IMAGING PERFORMED BY

Jenn

HOSPITAL NAME

Rockaway AH

REFERRING VET

Dr. Maniar

INVOICE

45928

DATE

7/6/23

PRESENTING CLINICAL SIGNS

History: recheck prev u/s 4/3 and 5/8 Compensated Stage B1 valvular dz Owner was concerned because dog had a coughing fit yesterday but was out in the heat, otherwise has been fine Current meds Lasix 12.5mg 1/4 BID Enalapril 2.5 mg 1 SID Vetmedin 1.25 1 pill BID

ULTRASONOGRAPHIC EXAMINATION OF THE HEART

The echocardiogram in this patient revealed persistent mitral and tricuspid insufficiency with prolapse of the anterior mitral valve leaflet with a relatively contained left atrial size. The contractility was unremarkable. The right heart was unremarkable. There was no pericardial or pleural effusion noted.

	CANINE	MR	TR	LA/AO	LA/AO	FS	EF	EPSS
CARDIAC PARAMETERS		VMAX (m/s)	VMAX (m/s)	(Boon method)	(Heart Base;)	(%)	(%)	(cm)
NORMAL PARAMETER		4.5-5.5	<2.7	1.3	<1.6	28-40	40-100	<0.6
PATIENT				1.3	1.7	54	86	0.1
	CANINE	HR	AV	PV	BODY WEIGHT	LA	LVIDd	LVIDs
CARDIAC PARAMETERS		(BPM)	VMAX (m/s)	MAX (m/s)		2D short axis Base view (cm)	Avg; 2D and m-mode short axis (cm)	Avg; 2D and m-mode short axis (cm)
NORMAL PARAMETER		50-100	0.7-1.7	0.7-1.6	BELOW	BELOW	BELOW	BELOW
PATIENT		160		0.9	8.6 lbs	2.45	2.7	

ULTRASONOGRAPHIC FINDINGS

Stable valvular disease.

INTERPRETATION OF THE FINDINGS & FURTHER RECOMMENDATIONS

The coughing is unlikely to be cardiogenic. Primary respiratory adjustment is recommended. There was no progression from the prior echocardiogram.



PATIENT

Korben Tomasicchio

SPECIES

Canine

BREED

Chihuahua Mix

SEX

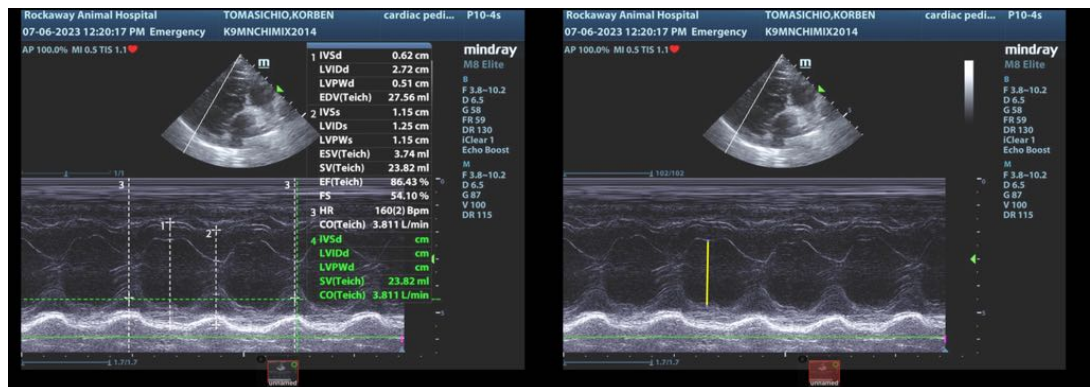
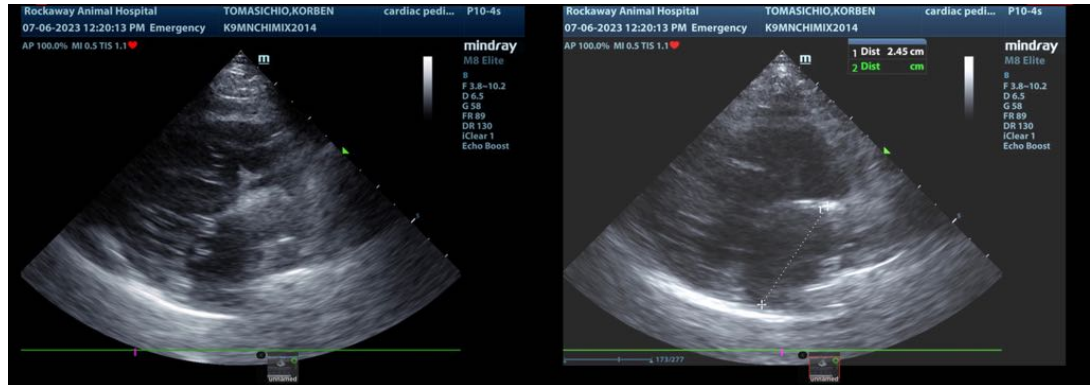
Neutered male

AGE

9 years

WEIGHT

8.6 lbs



INTERPRETED BY

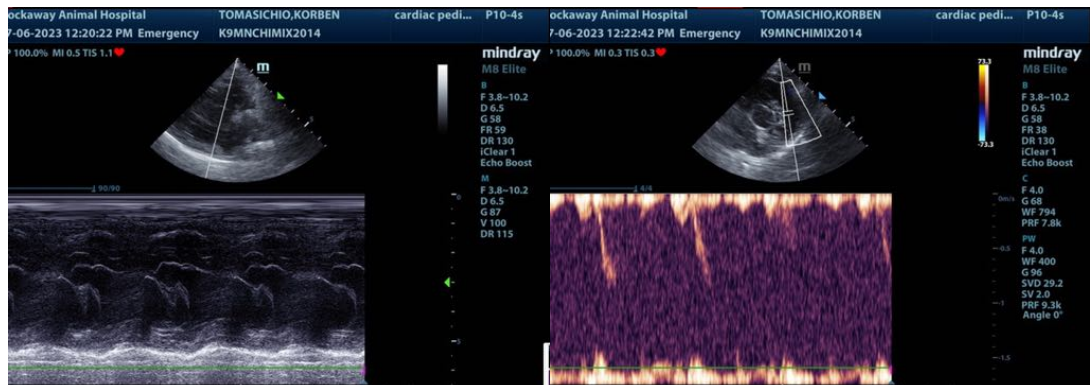
Eric Lindquist, DMV
DABVP, Cert. IVUSS

IMAGING PERFORMED BY

Jenn

HOSPITAL NAME

Rockaway AH



REFERRING VET

Dr. Maniar

INVOICE

45928

DATE

7/6/23

The information and recommendations provided are based on the images presented by the referring veterinarian/sonographer. No evaluation can be communicated regarding pathology that was not visible in the image/video clips provided.

Thank you for this referral. If the clinical or image interpretation does not parallel your findings or if I can be of any further assistance please contact me.

Eric Lindquist, DMV, DABVP, Cert. IVUSS, CEO of SonoPath.com
info@SonoPath.com