

**PATIENT**

Otis Slattery

**SPECIES**

Canine

**BREED**

English Bulldog

**SEX**

Neutered Male

**AGE**

10 Years

**WEIGHT**

79 Pounds

**INTERPRETED BY**

Eric Lindquist, DMV  
DABVP, Cert. IVUSS

**IMAGING  
PERFORMED BY**

Kelly Vazquez

**HOSPITAL NAME**

Glen Rock VH

**REFERRING VET**

Dr. Scott Stekler

**INVOICE**

16495

**DATE**

7/6/22

**PRESENTING CLINICAL SIGNS**

History: Patient presents for abdominal distention. Current meds: Flagyl 250mgs 1 ½ BID.

Abnormal PE/Chem/CBC/UA Results: ALT 141.

**ULTRASONOGRAPHIC EXAMINATION OF THE ABDOMEN**

**Urinary System**

The **urinary bladder** revealed minor uniform thickening. The residual prostate was uniform, measuring 1.03 cm.

The **kidneys** revealed largely normal size and structure, corticomedullary definition and ratio (cortex 1/3 of medulla) were essentially maintained with some mild age-related loss of curvilinear patterns regarding the capsule and C/M junction. The cortices presented largely uniform texture with some increased echogenicity expected for his age patient. Medullary structure differed distinctly from that of the cortex and no evidence of pelvic dilation was present. Slight mineralization was noted. The left kidney measured 5.6 cm. The right kidney measured 6.7 cm.

**Adrenal Glands**

The regions of the **adrenal glands** revealed no evident pathology.

**Spleen**

The **spleen** was uniform with coarse architecture. The spleen was volume contracted.

**Liver**

The **liver** itself was unremarkable. The vena cava was dilated at 1.96 cm. Hepatic veins were dilated consistent with passive congestion. The gallbladder and common bile duct were unremarkable.

**Gastrointestinal**

Examination of the **gastrointestinal tract** revealed a stomach and intestine free of stasis, of normal wall thickness, acceptable curvilinear mural detail, and peristaltic activity. Small and large intestine demonstrated normal luminal chyme and stool consistency respectively. No obstructive or overt infiltrative disease was noted. No associated abnormal lymphatic activity was noted.

**Pancreas**

The base and limbs of the **pancreas** were observed to be largely isoechoic to surrounding omental fat. Pancreatic duct and capsular contour were acceptably normal and parenchyma respected normal curvilinear patterns. No overt evidence of active inflammatory or neoplastic disease was noted.

**Free Abdomen**

A large amount of **ascites** was noted in this patient.

**ULTRASONOGRAPHIC FINDINGS**

- Passive congestion liver pattern with secondary ascites, concern for thoracic disease, such as right sided congestive heart failure.
- Volume contracted spleen with coarse architecture



**PATIENT**

- Urinary bladder thickening
- Age-related renal changes with mineralization

Otis Slattery

**INTERPRETATION OF THE FINDINGS & FURTHER RECOMMENDATIONS**

**SPECIES**

Full echocardiogram is recommended, as well as chest radiographs. Abdominocentesis is warranted with cytospin to assess for occult neoplasia, yet no evidence of neoplastic organ changes were noted.

Canine

**BREED**

English Bulldog

**SEX**

Neutered Male

**AGE**

10 Years

**WEIGHT**

79 Pounds

**INTERPRETED BY**

Eric Lindquist, DMV  
DABVP, Cert. IVUSS

**IMAGING PERFORMED BY**

Kelly Vazquez

**HOSPITAL NAME**

Glen Rock VH

**REFERRING VET**

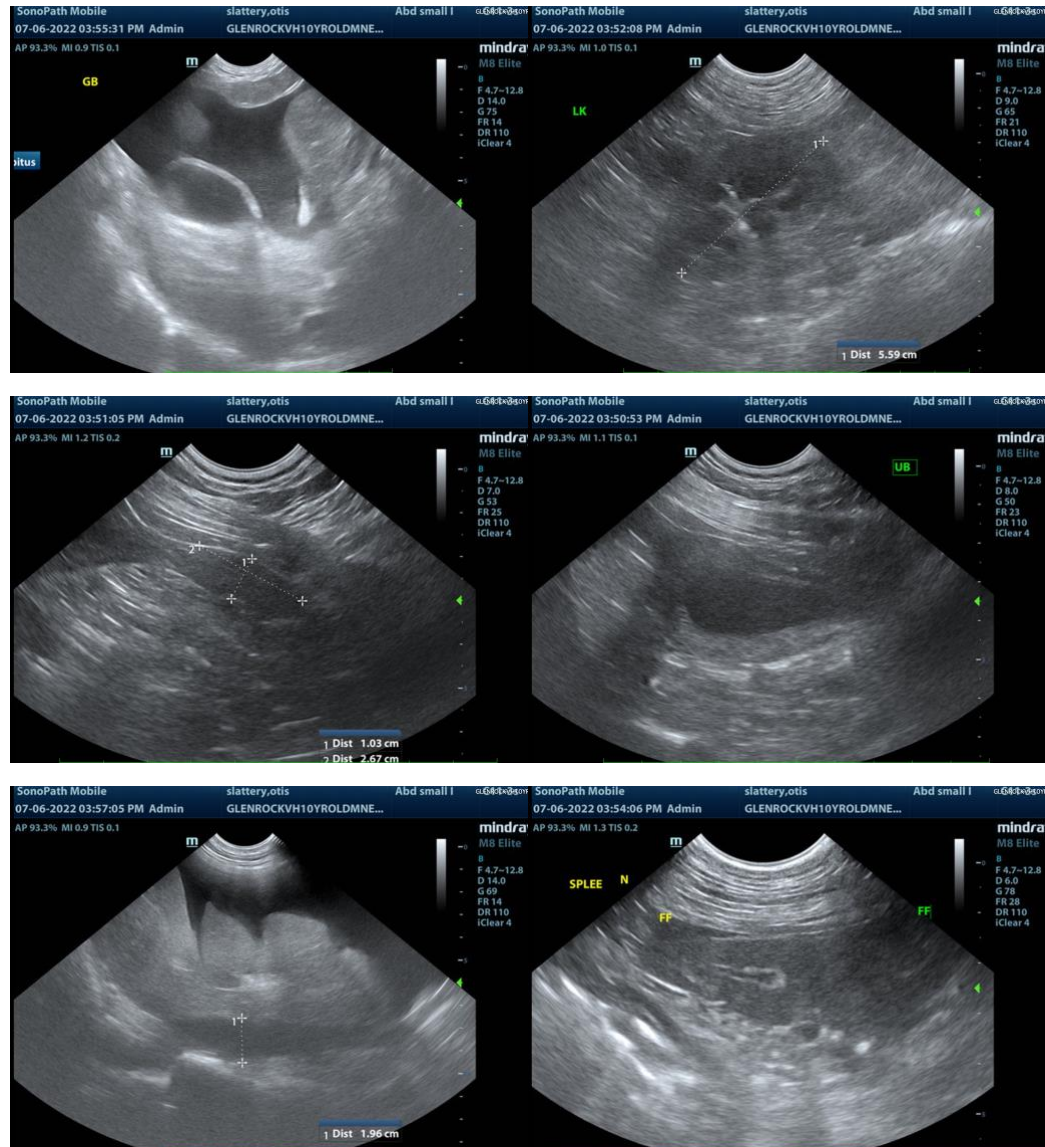
Dr. Scott Stekler

**INVOICE**

16495

**DATE**

7/6/22





**PATIENT**

Otis Slattery

**SPECIES**

Canine

**BREED**

English Bulldog

**SEX**

Neutered Male

**AGE**

10 Years

**WEIGHT**

79 Pounds

**INTERPRETED BY**

Eric Lindquist, DMV  
DABVP, Cert. IVUSS

**IMAGING PERFORMED BY**

Kelly Vazquez

**HOSPITAL NAME**

Glen Rock VH

**REFERRING VET**

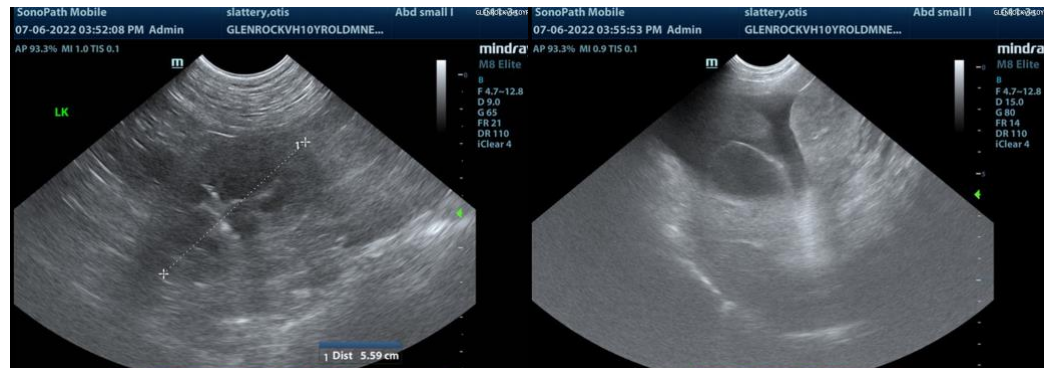Dr. Scott Stekler

**INVOICE**

16495

**DATE**

7/6/22



The information and recommendations provided are based on the images presented by the referring veterinarian. No evaluation can be communicated regarding pathology that was not visible in the image/video clips provided.

Thank you for this referral. If the clinical or image interpretation does not parallel your findings or if I can be of any further assistance please contact me.

**Eric Lindquist**, DMV, DABVP, Cert. IVUSS, CEO of SonoPath.com  
info@SonoPath.com