



PATIENT PRESENTING CLINICAL SIGNS

Nikki MacDougall

History: lipoma-type mass on cranial aspect of left front leg(inside elbow), concern for possibility of removal

SPECIES LIMITED ULTRASONOGRAPHIC EXAMINATION

Canine

A 2.0 cm round, well encapsulated hypoechoic mass was noted in this patient. The mass appears to not involve the periosteum or bony structures. The mass appears to be resectable and noninvasive. However, it is mildly vascular and the hypoechoogenicity would suggest potential sarcoma. FNA could be considered for further definition, as well as abdominal sonogram and chest screening for potential related lesions/metastasis.

BREED

Poodle

SEX

Neutered Male

ULTRASONOGRAPHIC FINDINGS

- Moderately vascular hypoechoic sarcoma-type mass, well encapsulated and not involving bony structures.

AGE

8 Years

INTERPRETATION OF THE FINDINGS & FURTHER RECOMMENDATIONS

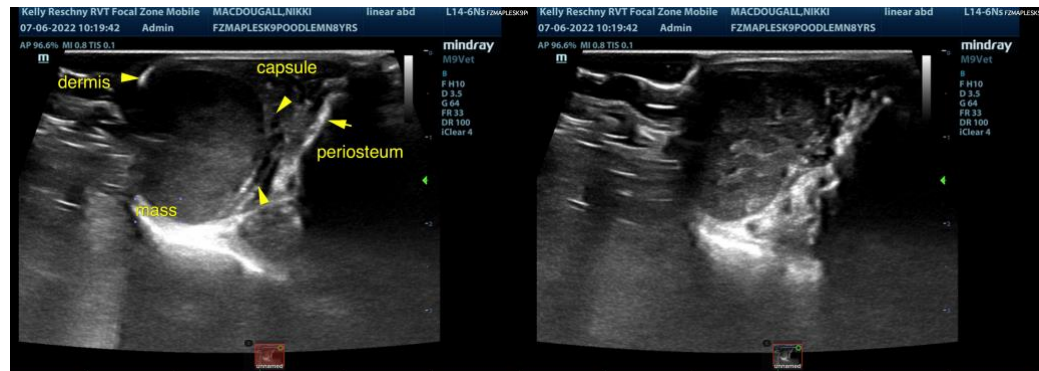The mass appears resectable yet screening of the abdomen and chest recommended for metastatic disease, depending upon cytology results. Well organized lipomas are possible, however, the level of vascularity and hypoechoogenicity would suggest a more aggressive process.

WEIGHT

16 Pounds

INTERPRETED BY

Eric Lindquist, DMV
DABVP, Cert. IVUSS

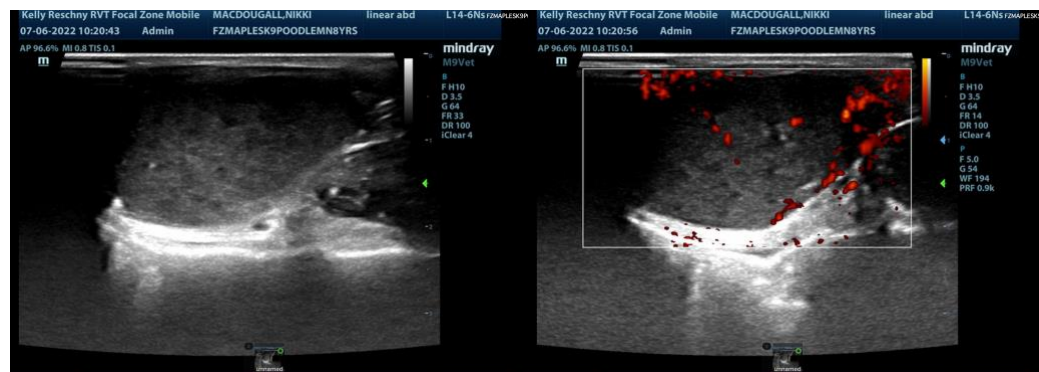

IMAGING PERFORMED BY

Kelly Reschny

HOSPITAL NAME

Maples AH



REFERRING VET

Dr. Kazienko

INVOICE

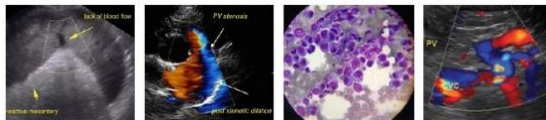
16503

DATE

7/6/22

The information and recommendations provided are based on the images presented by the referring veterinarian. No evaluation can be communicated regarding pathology that was not visible in the image/video clips provided.

Thank you for this referral. If the clinical or image interpretation does not parallel your findings or if I



PATIENT

can be of any further assistance please contact me.

Nikki MacDougall

SPECIES

Canine

BREED

Poodle

SEX

Neutered Male

AGE

8 Years

WEIGHT

16 Pounds

INTERPRETED BY

Eric Lindquist, DMV
DABVP, Cert. IVUSS

**IMAGING
PERFORMED BY**

Kelly Reschny

HOSPITAL NAME

Maples AH

REFERRING VET

Dr. Kazienko

INVOICE

16503

DATE

7/6/22

Eric Lindquist, DMV, DABVP, Cert. IVUSS, CEO of SonoPath.com
Eric.Lindquist@SonoPath.com