



PATIENT

Max Sinkus

SPECIES

Feline

BREED

DSH

SEX

Neutered Male

AGE

12 Year

WEIGHT

9 Pounds

INTERPRETED BY

Eric Lindquist, DMV
DABVP, Cert. IVUSS

IMAGING PERFORMED BY

Marti Williams

HOSPITAL NAME

Limestone VH

REFERRING VET

Dr. Laurita Halbert

INVOICE

16513

DATE

7/6/22

PRESENTING CLINICAL SIGNS

History: Small bowel diarrhea x ~ 3 months with mild weight loss. No response to Metronidazole, Probiotics, GI Biome, broad spectrum deworming.

Abnormal PE/Chem/CBC/UA Results: Labwork, Fecal NSF

ULTRASONOGRAPHIC EXAMINATION OF THE ABDOMEN

Urinary System

The **urinary bladder**, trigone, and pelvic urethra presented normal thicknesses and normal tone. The ureters were not visible which is normal. No uroliths or sediment were visualized, and anechoic urine was present. No evidence of inflammatory or neoplastic changes were noted. Ureteral papillae were normal.

The **kidneys** revealed largely normal size and structure, corticomedullary definition and ratio (cortex 1/3 of medulla) were essentially maintained with some age-related loss of curvilinear patterns regarding the capsule and C/M junction. The cortices presented largely uniform texture with some increased echogenicity expected for his age patient. Medullary structure differed distinctly from that of the cortex and no evidence of pelvic dilation was present. The left kidney measured 3.71 cm. The right kidney measured 3.5 cm.

Adrenal Glands

Both **adrenal glands** were visualized and recognized as having normal shape, size, position and echogenicity for this breed. The phrenic vasculature, glandular echogenicity and detail were unremarkable. Capsule, cortex, and medullary definition were normal for this age patient. The right adrenal gland measured 0.4 cm. The left adrenal gland measured 0.4 cm.

Spleen

The **spleen** presented a smooth homogeneous parenchyma hyperechoic to liver and renal cortical parenchyma. The capsule was smooth without noticeable expansion or deviation from within the spleen or adjacent pathology. The splenic vasculature demonstrated normal volume without signs of congestion or thrombosis. No sonographic evidence of acute or chronic inflammatory, neoplastic, or infarctual changes were noted. The spleen measured 9.0 mm in width.

Liver

The **liver** images submitted revealed subjectively normal liver size, contour, and structure. Parenchymal echogenicity was naturally coarse and hypoechoic to the spleen. Vascular and biliary tracts were of normal volume with no evidence of congestion. The gallbladder presented acceptably thin walls with primarily anechoic content. The cystic and common bile ducts were normal. No pathological hepatic lymphadenopathy was evident. No overt structural evidence of inflammatory, infiltrative or regenerative pathology was evident.

Gastrointestinal

The **gastrointestinal tract** revealed minor variable thickening and echogenic submucosal changes most consistent with low grade end result of chronic GI disease such as IBD and may be related to malassimilation of nutrients if any weight loss is present. No obvious neoplastic patterns were noted and luminal content as unremarkable. A minor amount of gastric fluid was present.



PATIENT

Max Sinkus

SPECIES

Feline

BREED

DSH

SEX

Neutered Male

AGE

12 Year

WEIGHT

9 Pounds

INTERPRETED BY

Eric Lindquist, DMV
DABVP, Cert. IVUSS

IMAGING PERFORMED BY

Marti Williams

HOSPITAL NAME

Limestone VH

REFERRING VET

Dr. Laurita Halbert

INVOICE

16513

DATE

7/6/22

Pancreas

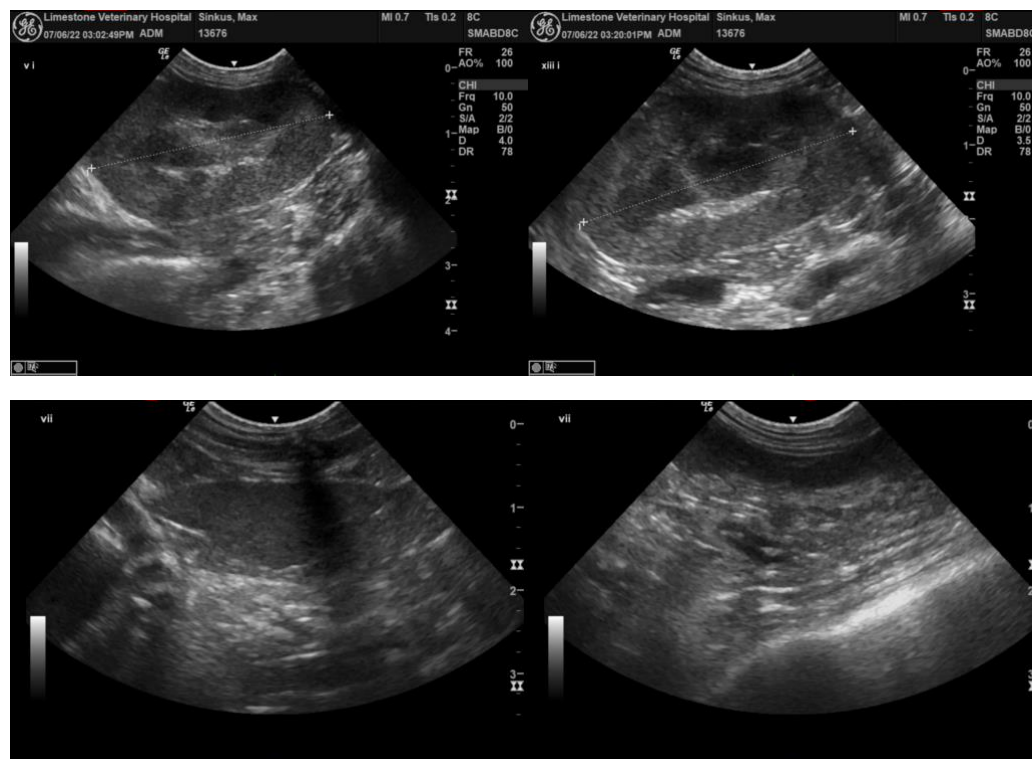The base and limbs of the **pancreas** were observed to be largely isoechoic to surrounding omental fat. Pancreatic duct and capsular contour were acceptably normal and parenchyma respected normal curvilinear patterns. No overt evidence of active inflammatory or neoplastic disease was noted.

ULTRASONOGRAPHIC FINDINGS

- Mild chronic GI changes
- Structurally unremarkable abdomen otherwise

INTERPRETATION OF THE FINDINGS & FURTHER RECOMMENDATIONS

Chronic inflammatory bowel is likely. No evidence of neoplastic criteria. Largely geriatric abdomen. Maldigestion panel, three view chest radiographs and full CNS examination is recommended to examine for occult disease that could be responsible for the weight loss. Evaluation for competitive eating environments should also be considered. Malassimilation of nutrients is a strong potential in this patient.





PATIENT

Max Sinkus

SPECIES

Feline

BREED

DSH

SEX

Neutered Male

AGE

12 Year

WEIGHT

9 Pounds

INTERPRETED BY

Eric Lindquist, DMV
DABVP, Cert. IVUSS

**IMAGING
PERFORMED BY**

Marti Williams

HOSPITAL NAME

Limestone VH

REFERRING VET

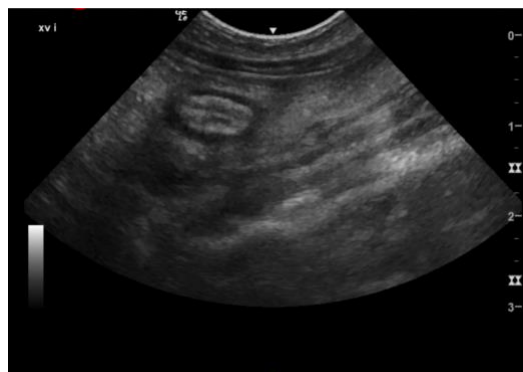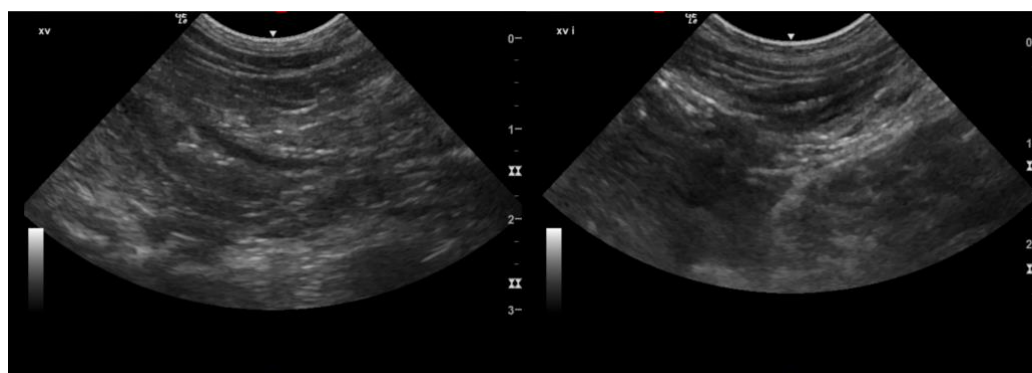
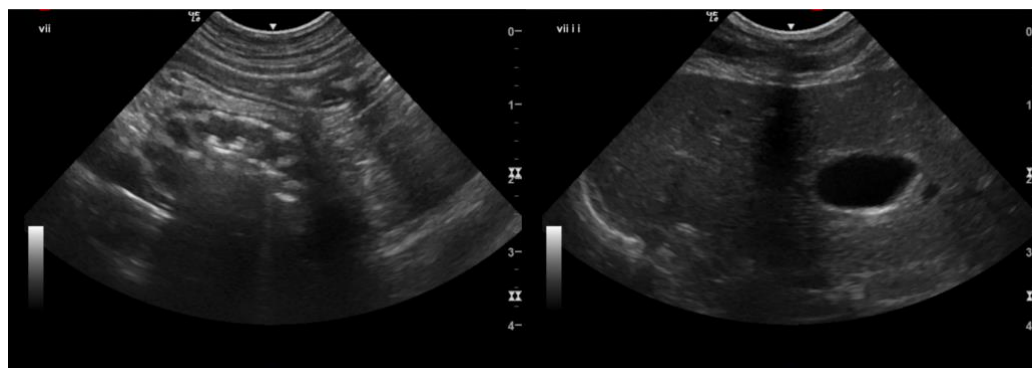
Dr. Laurita Halbert

INVOICE

16513

DATE

7/6/22



The information and recommendations provided are based on the images presented by the referring veterinarian. No evaluation can be communicated regarding pathology that was not visible in the image/video clips provided.

Thank you for this referral. If the clinical or image interpretation does not parallel your findings or if I can be of any further assistance please contact me.

Eric Lindquist, DMV, DABVP, Cert. IVUSS, CEO of SonoPath.com
info@SonoPath.com