

**DATE**

7/6/22

**PRESENTING CLINICAL SIGNS**

History: Elevated ALKp and ALT not resolving with denamarin.

**PATIENT**

Juvee Johnson

Current Medications: None listed.

Date of Previous IntraPet Ultrasound: No previous.

Sedation: Declined.

Stat Report: Not requested.

**SPECIES**

Canine

Imaging Performed By: Rachel Brillhart, RDMS.

**BREED**

Shih Tzu

**SEX**

Intact Male

**AGE**

1/23/16

**WEIGHT**

6.3 kg

**ULTRASONOGRAPHIC EXAMINATION OF THE ABDOMEN****Urinary System**

The **urinary bladder**, trigone, and pelvic urethra presented normal thicknesses and normal tone. The ureters were not visible which is normal. No uroliths or sediment were visualized and anechoic urine was present. No evidence of inflammatory or neoplastic changes were noted. Ureteral papillae were normal.

The **prostate** was uniformly enlarged with lobar swelling appeared to impinge upon the urethra and mildly deviate the descending colon. The prostatic tissue was hyperechoic containing focal areas of decreased echogenicity. These changes are suggestive of either chronic inflammatory episodes, benign cystic pathology or both. Underlying neoplasia cannot be completely ruled-out but is lower on the differential list. This presentation is most consistent with benign prostatic hyperplasia with possible active prostatitis. Neutering or off-label Finasteride (Propecia) (0.1-0.5 mg/kg Sid) treatment is indicated +/- FNA or prostatic wash cytology and culture. The prostate measured 4.04 cm.

The **testicles** were imaged and found to be uniform with no evidence of pathology.

The **kidneys** revealed normal size and structure, corticomedullary definition and ratio for this age. The cortices presented largely uniform texture with normal echogenic relationship to liver and spleen. Medullary structure differed distinctly from the cortex and no evidence of pelvic dilation was present. The capsules were acceptably uniform without significant irregularities. The left kidney measured 4.82 cm. The right kidney measured 4.82 cm.

**Adrenal Glands**

Both **adrenal glands** were visualized and recognized as having normal shape, size, position and echogenicity for this breed. The phrenic vasculature, glandular echogenicity and detail were unremarkable. Capsule, cortex, and medullary definition were normal for this age patient. The left adrenal gland measured 1.36 cm x 0.39 cm at the caudal pole and 0.55 cm at the cranial pole. The right adrenal gland measured 1.68 cm x 0.41 cm at the caudal pole and 0.41 cm at the cranial pole.

**Spleen**

The **spleen** presented a smooth homogeneous parenchyma hyperechoic to liver and renal cortical parenchyma. The capsule was smooth without noticeable expansion or deviation from within the spleen or adjacent pathology. The splenic vasculature demonstrated normal volume without signs of congestion or thrombosis. No sonographic evidence of acute or chronic inflammatory, neoplastic, or infarctual changes were noted.

**Liver****INTERPRETED BY**Eric Lindquist, DMV  
DABVP, Cert. IVUSS**HOSPITAL NAME**

Banfield Towson

**REFERRING VET**

Dr. Washington

**INVOICE**

16510

The **liver** was slightly subnormal in size with minor heterogeneous changes and slight increased portal markings. Occasional hypoechoic nondisruptive nodules were noted. The gallbladder and common bile duct were unremarkable. The portal vein to vena cava ratio is 1:1.

### **Gastrointestinal**

Examination of the **gastrointestinal tract** revealed a stomach and intestine free of stasis, of normal wall thickness, acceptable curvilinear mural detail, and peristaltic activity. Small and large intestine demonstrated normal luminal chyme and stool consistency respectively. No obstructive or overt infiltrative disease was noted. No associated abnormal lymphatic activity was noted.

### **Pancreas**

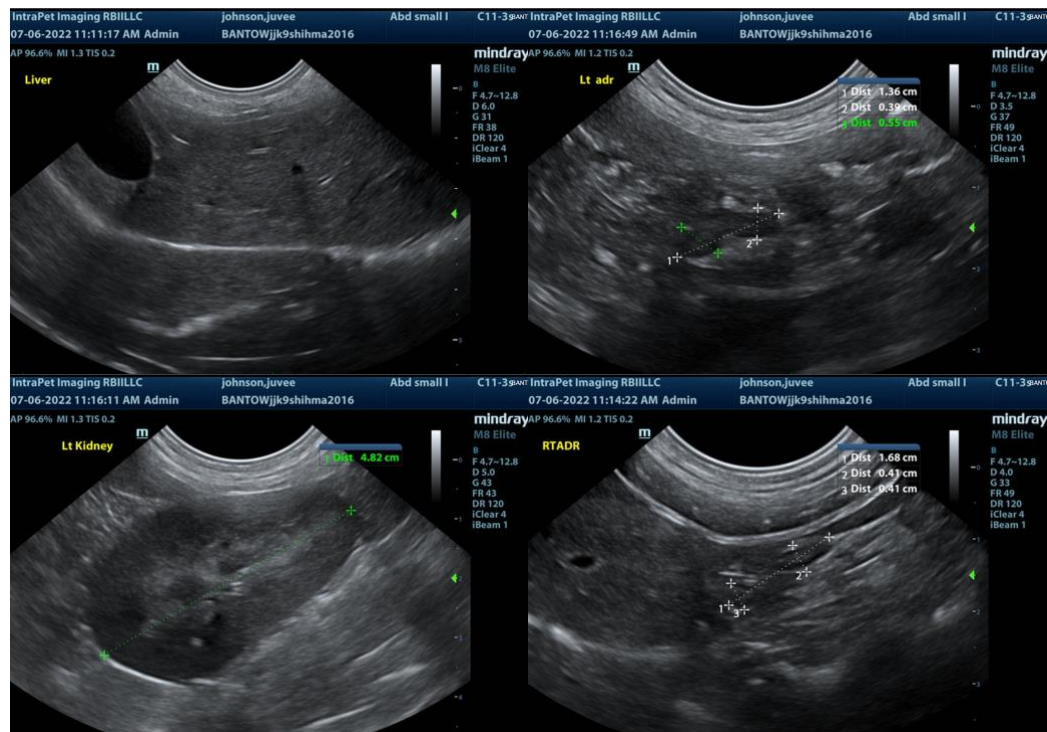
The base and limbs of the **pancreas** were observed to be largely isoechoic to surrounding omental fat. Pancreatic duct and capsular contour were acceptably normal and parenchyma respected normal curvilinear patterns. No overt evidence of active inflammatory or neoplastic disease was noted.

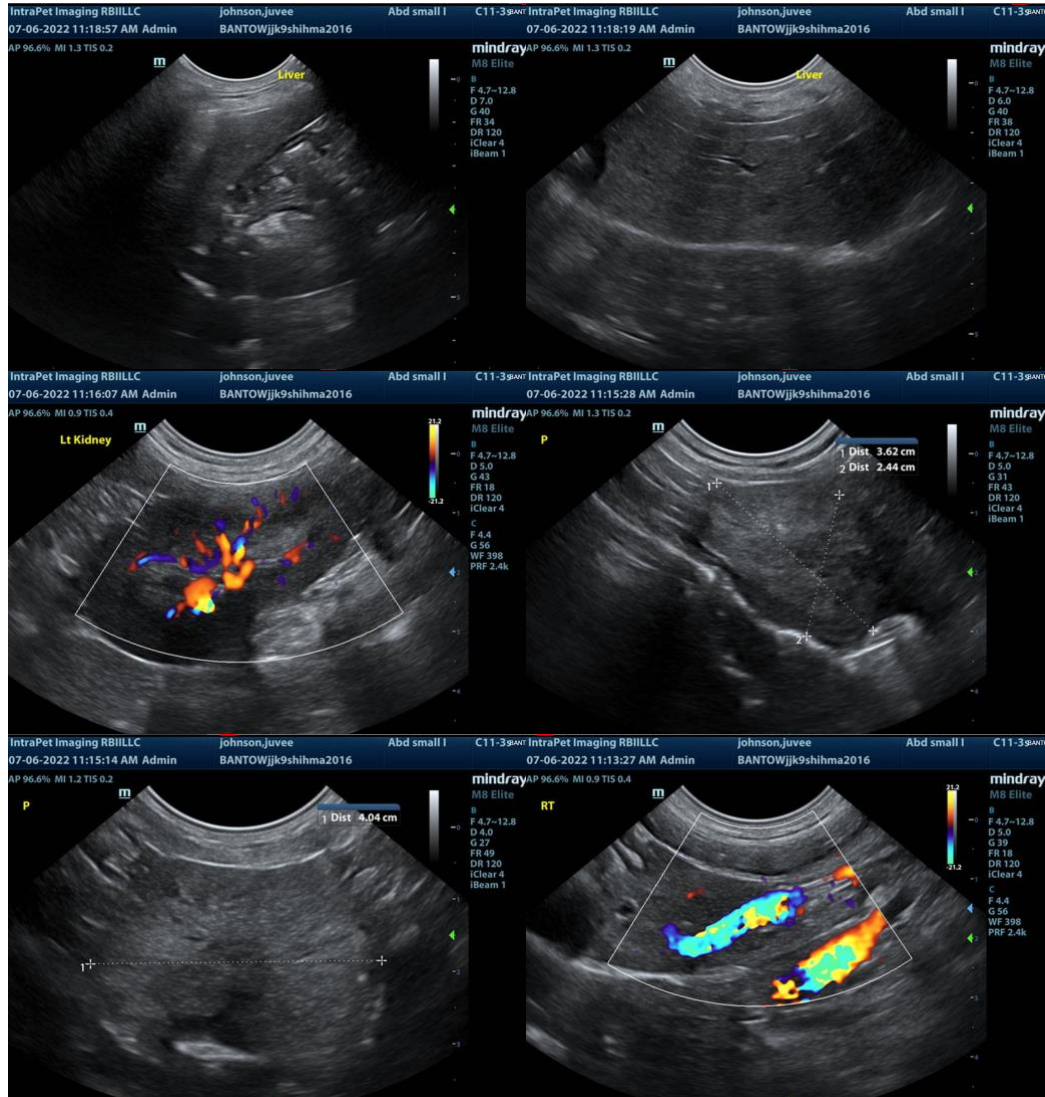
### **ULTRASONOGRAPHIC FINDINGS**

- Nonspecific mild chronic inflammatory hepatopathy
- BPH prostate

### **INTERPRETATION OF THE FINDINGS & FURTHER RECOMMENDATIONS**

FNA or core biopsy of the liver would be ideal, especially if bile acids are elevated. Bile acid profile could be considered. Neutering is indicated. No evidence of neoplasia.





The information and recommendations provided are based on the images presented by the referring veterinarian. No evaluation can be communicated regarding pathology that was not visible in the image/video clips provided.

Thank you for this referral. If the clinical or image interpretation does not parallel your findings or if I can be of any further assistance please contact me.

**Eric Lindquist**, DMV, DABVP, Cert. IVUSS, CEO of SonoPath.com  
 Eric.Lindquist@SonoPath.com