

**DATE PRESENTING CLINICAL SIGNS**

7/5/23 Recheck bladder from previous AUS.  
Lab Results: Sp. Gr. 1010.  
Date of Previous IntraPet Ultrasound: 5/19/23.

**PATIENT** Sedation: Not required to complete full diagnostic ultrasound.  
Stat Report: Not requested.

Faigh Starr Imaging Performed By: Rachel Brillhart, RDMS.

**SPECIES ULTRASONOGRAPHIC EXAMINATION OF THE ABDOMEN**  
**Urinary System**

Canine The **urinary bladder** revealed apical wall thickening that is significantly progressed from the prior sonogram. This created a transmural thickening that measured 3.4 x 1.4 cm with some suspended debris and a trace amount of sand.

**BREED** Boxer Mix  
The **kidneys** were normal in size and contour similar to the prior sonogram. The left kidney measured 7.64 cm. The right kidney measured 6.53 cm.

**SEX** Spayed female

**ULTRASONOGRAPHIC FINDINGS**

**AGE** Ventral bladder wall thickening, progressive. Strong concern for emerging carcinoma.  
8/16/12 Persistent bladder sand.  
Polypoid cystitis possible.

**WEIGHT INTERPRETATION OF THE FINDINGS & FURTHER RECOMMENDATIONS**

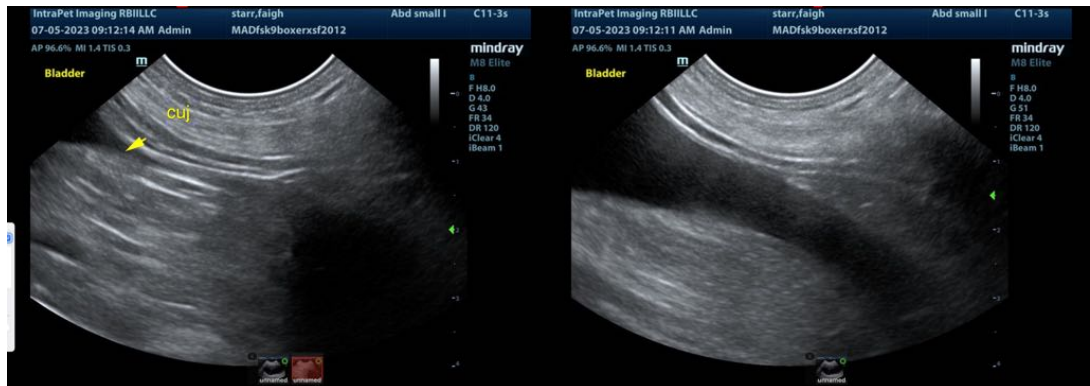87.9 lbs The ventral bladder wall thickening appears to be resectable. The cystourethral junction was free of evident pathology as was the urethra. I recommend surgical intervention with resection of the ventral apical bladder wall and bladder lavage sand analysis. Bladder wall biopsy and culture are indicated. BRAFF testing would be appropriate as well as cytospin of free catch urine sample to assess for any carcinoma type cells.

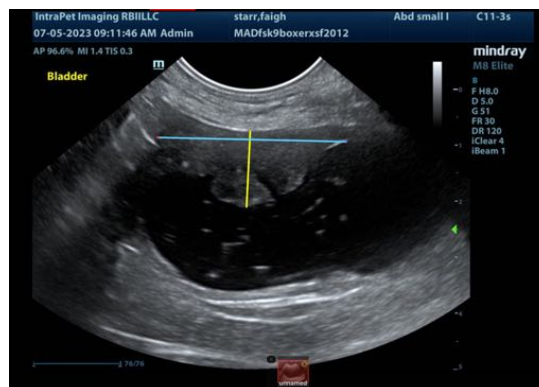
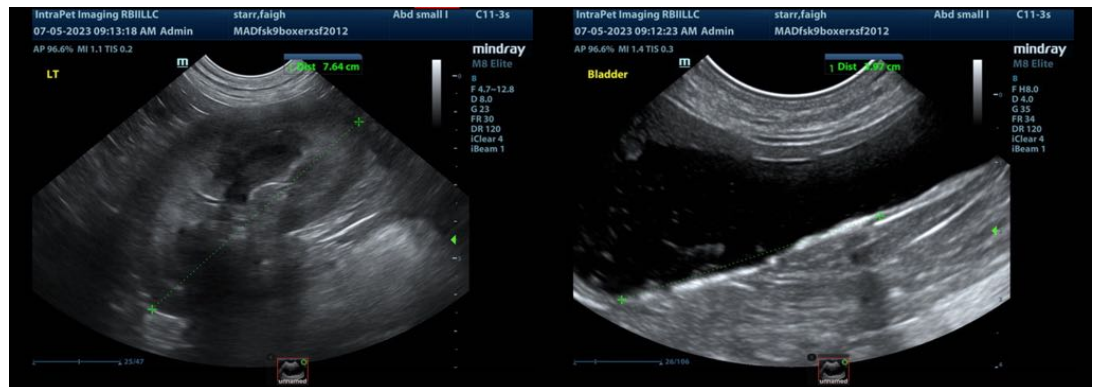
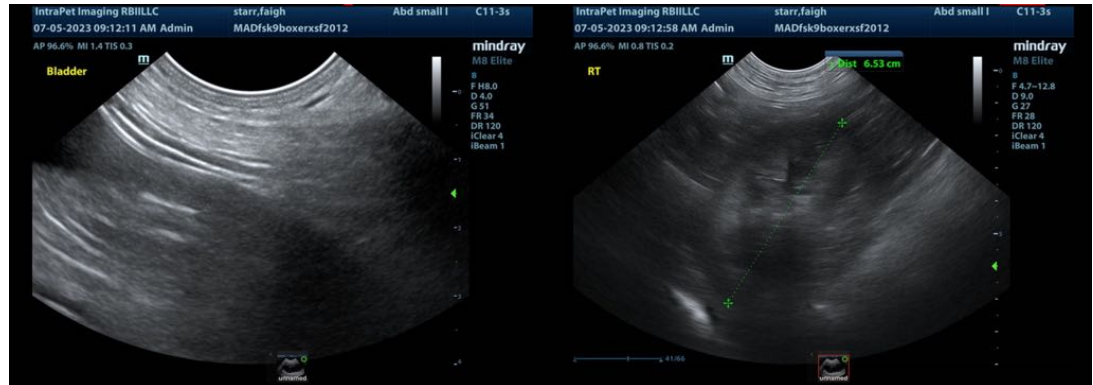
**INTERPRETED BY**  
Eric Lindquist, DMV  
DABVP, Cert. IVUSS

**HOSPITAL NAME**  
Madonna VC

**REFERRING VET**  
Dr. Cangro

**INVOICE**  
45902





The information and recommendations provided are based on the images presented by the referring veterinarian. No evaluation can be communicated regarding pathology that was not visible in the image/video clips provided.

Thank you for this referral. If the clinical or image interpretation does not parallel your findings or if I can be of any further assistance, please contact me.

**Eric Lindquist**, DMV, DABVP, Cert. IVUSS, CEO of SonoPath.com  
[info@SonoPath.com](mailto:info@SonoPath.com)