



**PATIENT PRESENTING CLINICAL SIGNS**

Rexi Dattolico History: PU/PD suspect Cushing's. 2 "collapsing" episodes per owner No heart murmur or arrhythmia appreciated  
 Abnormal PE/Chem/CBC/UA Results: Elevated ALP

**SPECIES**

Canine

**ULTRASONOGRAPHIC EXAMINATION OF THE HEART**

**BREED**

Puggle

**SEX**

Neutered male

**AGE**

12 years

**WEIGHT**

28 lbs

The echocardiogram in this patient demonstrated normal **left atrial** size based on 3 separate methods of LA evaluation. The cranial and caudal **mitral** valve leaflets presented normal linear structure, extension in systole, and union in diastole with normal kinesis. The **left ventricle** presented thicknesses with linear contour and was not dilated nor restricted. The **myocardium** presented normal echogenicity without subjective evidence of significant fibrotic or ischemic disease. **Contractility** of the ventricular walls was adequate and in normal range for this patient evidenced by the fractional shortening measurement and subjective evaluation of the different regions of the myocardium. The **left ventricular outflow** tract demonstrated normal laminar flow and subjective structural integrity. The **right atrium** and auricle revealed normal size, structure and content. No evidence of masses was noted. **Tricuspid** valvular assessment demonstrated adequate linear morphology and kinesis. The **right ventricle** was of normal size (1/3 diameter of LV), chordae structure, myocardial echogenicity and thickness. **Pulmonary outflow** tract assessment revealed normal valve structure, laminar flow, and diameter (approx.1:1 pa/ao ratio). No visible **pericardial** or free pleura fluid was noted. The cranial **mediastinum and pericardial and extra-cardiac** regions were free of masses in the visible window.

**INTERPRETED BY**

Eric Lindquist, DMV  
 DABVP, Cert. IVUSS

**IMAGING PERFORMED BY**

Dr. Petrone

**HOSPITAL NAME**

Long Branch AH

**REFERRING VET**

Dr. Petrone

**INVOICE**

31479

**DATE**

7/5/22

CANINE CARDIAC PARAMETERS	MR VMAX (m/s)	TR VMAX (m/s)	LA/AO (Boon method)	LA/AO (Heart Base; Swe)	FS (%)	EF (%)	EPSS (cm)
NORMAL PARAMETER	4.5-5.5	<2.7	1.3	<1.3	28-40	40-100	<0.6
PATIENT			1.15	1.4	35	95	NM
CANINE CARDIAC PARAMETERS	HR (BPM)	AV VMAX (m/s)	PV MAX (m/s)	BODY WEIGHT	LA (2D short axis Base view)	LVIDd (Avg; 2D and m-mode short axis)	LVIDs (Avg; 2D and m-mode short axis)
NORMAL PARAMETER	50-100	0.7-1.7	0.7-1.6		(cm)	(cm)	(cm)
PATIENT	110	1.2	0.9	28 lbs	2.4	2.7	



**PATIENT** **ULTRASONOGRAPHIC EXAMINATION OF THE ABDOMEN**

Rexi Dattolico

**Urinary System**

**SPECIES**

Canine

The **urinary bladder** and visible pelvic urethra were unremarkable for the level of repletion presented. The urine, however, did present some mildly echogenic debris consistent with mucous, exfoliated cells from renal or bladder origin, and/or blood clots as these echogenic changes can all present similarly. This is often related to urinary tract infection but may represent simple evidence of exfoliated debris or sterile inflammation. Cystocentesis, urinalysis, +/- culture would be recommended to rule out and define any UTI.

**BREED**

Puggle

**SEX**

Neutered male

The **kidneys** revealed largely normal size and structure, corticomedullary definition and ratio (cortex 1/3 of medulla) were essentially maintained with some age-related loss of curvilinear patterns regarding the capsule and C/M junction. The cortices presented largely uniform texture with some increased echogenicity expected for this age patient. Medullary structure differed distinctly from that of the cortex and no evidence of pelvic dilation was present. The right kidney measured 4.6 cm. The left kidney measured 4.75 cm.

**AGE**

12 years

**Adrenal Glands**

**WEIGHT**

28 lbs

Both **adrenal glands** were visualized and recognized as having normal shape, size, position and echogenicity for this breed. The phrenic vasculature, glandular echogenicity and detail were unremarkable. Capsule, cortex, and medullary definition were normal for this age patient. The right adrenal gland measured 0.58 cm. The left adrenal gland measured 0.7 cm.

**INTERPRETED BY**

Eric Lindquist, DMV  
DABVP, Cert. IVUSS

**Spleen**

**IMAGING PERFORMED BY**

Dr. Petrone

The **spleen** presented a smooth homogeneous parenchyma hyperechoic to liver and renal cortical parenchyma. The capsule was smooth without noticeable expansion or deviation from within the spleen or adjacent pathology. The splenic vasculature demonstrated normal volume without signs of congestion or thrombosis. No sonographic evidence of acute or chronic inflammatory, neoplastic, or infarctual changes was noted.

**HOSPITAL NAME**

Long Branch AH

**Liver**

**REFERRING VET**

Dr. Petrone

The **liver** was uniformly swollen with minor, excessive gallbladder debris and over distension with dependent and suspended bile without evidence of overt mucocele formation. However, excessive sludge was present. Heterogenous parenchymal changes were noted in the liver. The liver presented coarse architecture with mildly increased portal markings and subtle, mixed echogenic changes. This is consistent with vacuolar hepatopathy and some level of remodeling and history of inflammatory component. There was no overt suspicion of neoplasia.

**INVOICE**

31479

**Gastrointestinal**

**DATE**

7/5/22

Examination of the **gastrointestinal tract** revealed a stomach and intestine free of stasis, of normal wall thickness, acceptable curvilinear mural detail, and peristaltic activity. Small and large intestine



**PATIENT** demonstrated normal luminal chyme and stool consistency respectively. No obstructive or overt infiltrative disease was noted. No associated abnormal lymphatic activity was noted.

Rexi Dattolico

**SPECIES** *Pancreas*

Canine The base and limbs of the **pancreas** were observed to be largely isoechoic to surrounding omental fat. Pancreatic duct and capsular contour were acceptably normal and parenchyma respected normal curvilinear patterns. No overt evidence of active inflammatory or neoplastic disease was noted.

**BREED**

Puggle

**ULTRASONOGRAPHIC FINDINGS**

**SEX** Benign hepatopathy with remodeling.

Neutered male Bladder debris and a minor amount of sand a slight polyp was noted at the apical dorsal wall.  
Stable abdomen.

**AGE** Structurally unremarkable adrenal glands.

12 years Normal echocardiogram.

**WEIGHT**

28 lbs

**INTERPRETATION OF THE FINDINGS & FURTHER RECOMMENDATIONS**

Ursodiol therapy is warranted given the excessive gallbladder debris. I recommend establishing very solid Cushingoid parameters including urine specific gravity persistently less than < 1.020, ruling out underlying UTI or other causes of PU/PD prior to addressing any Cushingoid parameters. This type of hepatopathy can be present independent of Cushing's as the adrenal gland size is normal. Ensuring Isosthenuria/urine specific gravity is persistently < 1.020 and urine cortisol to creatinine ratio is elevated as well as potentially elevated LDDST. If any inflammatory sediment is noted in the urine the culture would be indicated.

**INTERPRETED BY**

Eric Lindquist, DMV  
DABVP, Cert. IVUSS

**IMAGING PERFORMED BY**

Dr. Petrone

**Efficient & Accurate Cushing's Work up-Lindquist**

**HOSPITAL NAME**

Long Branch AH

**Notes regarding Cushing's Clinical Presentations:**

*Nearly all Cushing's dogs have SAP elevations and true PU/PD (USG < 1.025) and most are polyphagic. Cushing's dogs are > 6 years and usually > 9 years old, usually have poor skin coats, body scores > 3/5, and are usually sedentary animals.*

**REFERRING VET**

Dr. Petrone

*Its important to remember that Cushing's dogs usually look and play the part and other diseases cause false + stress related cortisol spikes. On rare occasion a Cushing's dog will not follow the rules but this is truly an exception.*

**INVOICE**

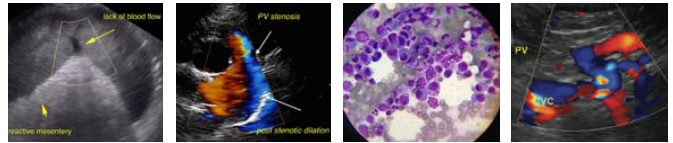
31479

*Potential Cushing's patient workups can be costly and frustrating if not definitive and, in my experience, the non-definitive patient usually has something else going on that may be contributing to some of the clinical signs a Cushing's dog will have, especially SAP elevations or PU/PD. Based on this prelude of information I came up with the following algorithm in the spirit of diagnostic efficiency.*

**DATE**

7/5/22

*The following suggested protocol is based on current available literature on Cushing's disease and extensive clinical-sonographic experience evaluation + Cushing's and False + LDDST & ACTH stim. cases in order to maximize the efficiency of a Cushing's workup in practice.*



**PATIENT** Screen first, workup second

Rexi Dattolico 1) **UA:** Repeatable (2-3 urine samples) Urine specific gravity & urine cortisol/creatinine ratio (UCCR): If **repeatable USG < 10.20 and + UCCR** move to next step 2.

**SPECIES** Note: UA is inexpensive and easy to obtain and if UA criteria is not met for Cushing's then resources can be spent into other more pertinent diagnostics or left on hold until the UA criteria is met in emerging Cushing's cases.  
Canine

**BREED** 2) **Sonogram:** Does the patient **have concurrent disease** clinically or sonographically as non-Cushing's illness will influence the potential false + LDDST or even ACTH stim. The sonogram gives a global perspective of the internal health of the patient to be considered in the Cushing's workup as an assessment of concurrent disease. Is there a concurrent neoplastic process, UTI pancreatitis, mucocele....? Are the adrenals enlarged (Cushing's-PDH, stress, age related or breed variant), or atrophied (iatrogenic Cushing's or adrenal burnout), have asymmetric enlargement (Adrenal tumor, hyperplasia, adenoma, age related variant), or is there vascular invasion (Invasive pheo with false + UA criteria or adenocarcinoma or phrenic thrombosis)? The sonogram answers these questions proactively.  
Puggle

**SEX** Neutered male

**AGE** 3) **LDDST** (0.01 D-Sodium phosphate mg/kg IV) (Better screening test but plagued with false +) Use if there is potential early Cushing's or if adrenal asymmetry present on sonogram suspecting tumor. Use LDDST in cats at a higher dose (0.1 mg/kg IV).  
12 years

OR

**WEIGHT** 4) **ACTH stim.** (Better confirming test but can have false +) Use if the patient "looks" Cushingoid or if bilateral adrenal enlargement is present, or high normal width on sonogram, or if iatrogenic Cushing's suspected (Cortisone Tx in past).  
28 lbs

5) If **diabetic** then run both LDDST & ACTH stim.

**INTERPRETED BY**

Eric Lindquist, DMV  
DABVP, Cert. IVUSS

5) Run a **serial blood pressure** in a BP friendly non "white coat effect" atmosphere. Run at least 3 at different times over a few hours or when eating as the patient tends to be calm when eating or give Torbutrol when entering the facility.

**IMAGING PERFORMED BY**

Dr. Petrone

6) **Perform CT** of the pituitary to identify macro adenoma expansion if any lethargy or dullness or other central clinical CNS signs are minimally present.

Suggested reading:

**HOSPITAL NAME**

Long Branch AH

Behrend EN, Kooistra HS, Nelson R, et al. Diagnosis of Spontaneous Canine Hyperadrenocorticism: 2012 ACVIM Consensus Statement (Small Animal). J Vet Intern Med 2013;27:1292-1304.

**REFERRING VET**

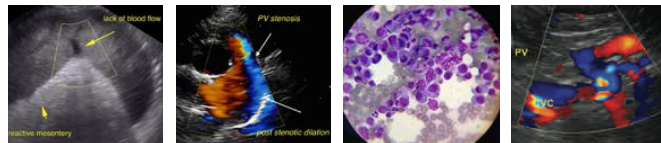
Dr. Petrone

**INVOICE**

31479

**DATE**

7/5/22



**PATIENT**

Rexi Dattolico

**SPECIES**

Canine

**BREED**

Puggle

**SEX**

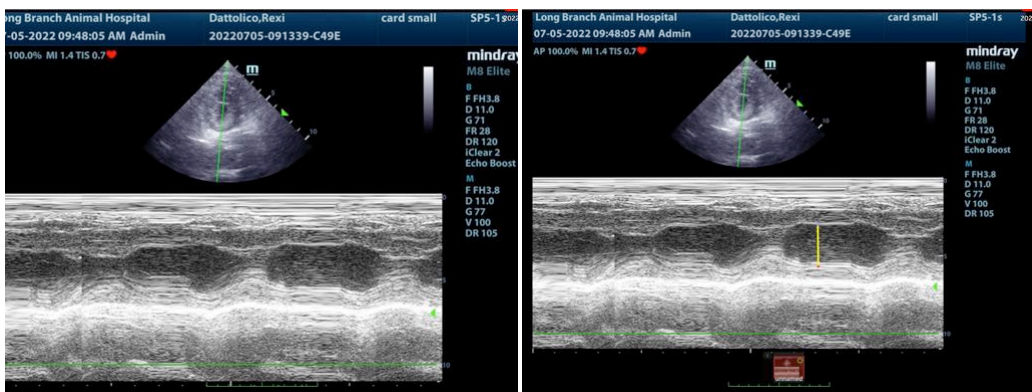
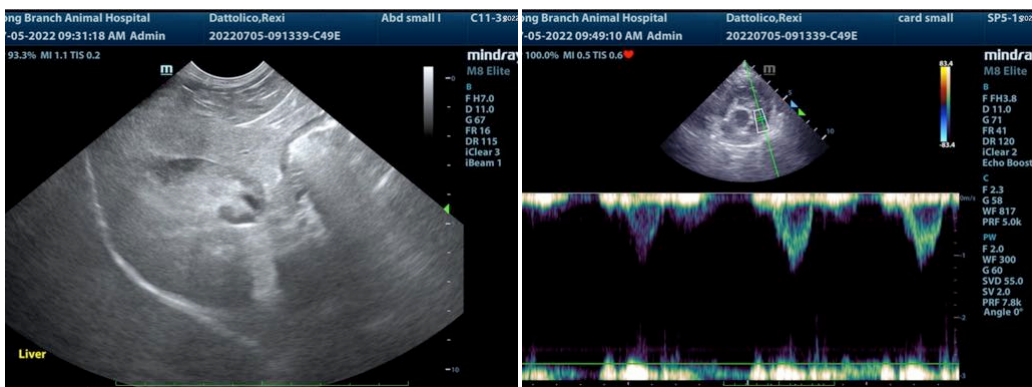
Neutered male

**AGE**

12 years

**WEIGHT**

28 lbs



**INTERPRETED BY**

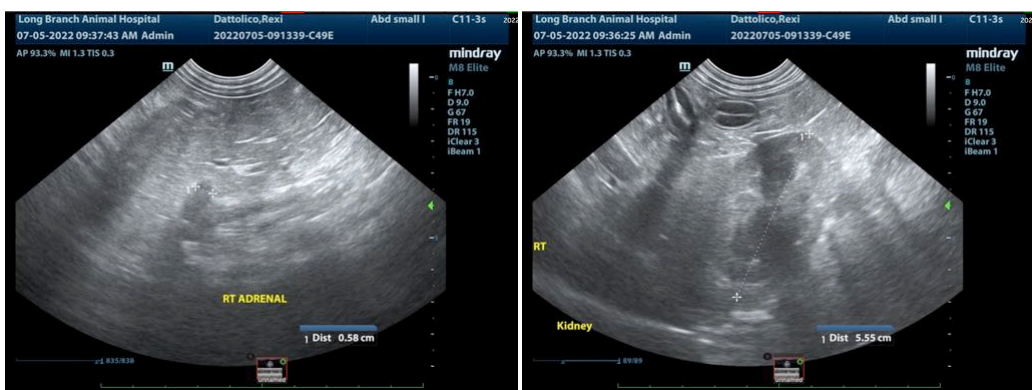
Eric Lindquist, DMV  
DABVP, Cert. IVUSS

**IMAGING PERFORMED BY**

Dr. Petrone

**HOSPITAL NAME**

Long Branch AH



**REFERRING VET**

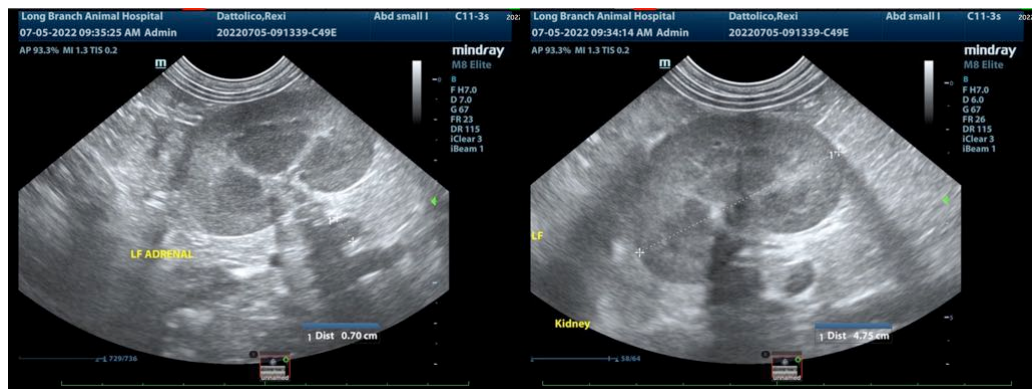
Dr. Petrone

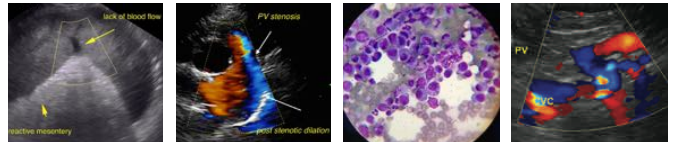
**INVOICE**

31479

**DATE**

7/5/22





**PATIENT**

Rexi Dattolico

**SPECIES**

Canine

**BREED**

Puggle

**SEX**

Neutered male

**AGE**

12 years

**WEIGHT**

28 lbs

**INTERPRETED BY**

Eric Lindquist, DMV  
DABVP, Cert. IVUSS

**IMAGING PERFORMED BY**

Dr. Petrone

**HOSPITAL NAME**

Long Branch AH

**REFERRING VET**

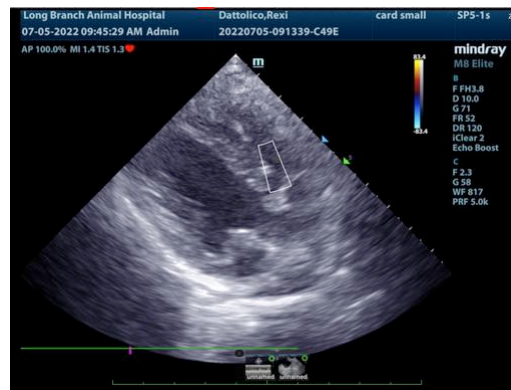
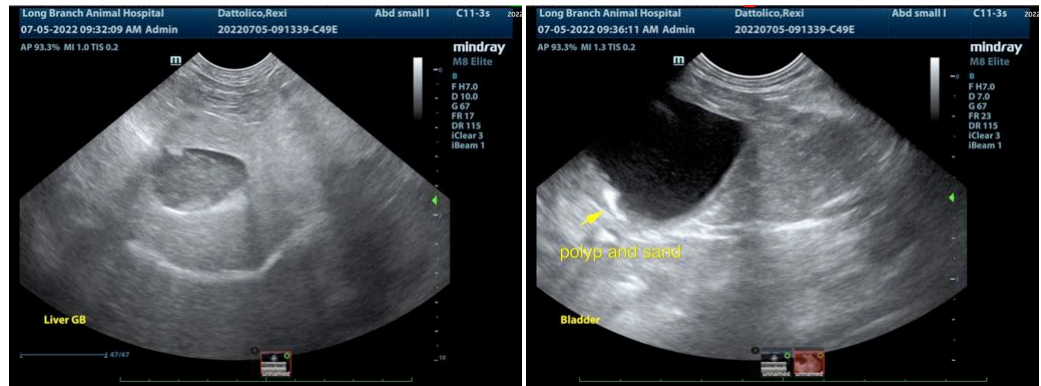
Dr. Petrone

**INVOICE**

31479

**DATE**

7/5/22



The information and recommendations provided are based on the images presented by the referring veterinarian/sonographer. No evaluation can be communicated regarding pathology that was not visible in the image/video clips provided.

Thank you for this referral. If the clinical or image interpretation does not parallel your findings or if I can be of any further assistance please contact me.

**Eric Lindquist, DMV, DABVP, Cert. IVUSS, CEO of SonoPath.com**  
info@SonoPath.com