



**PATIENT PRESENTING CLINICAL SIGNS**

Emily Kuiken History: Grade 4 left sided systolic murmur. On pimobendan and hydrocodone. History of CKD, increased coughing. Blood pressures averaging 150 systolic.

**SPECIES BREED ULTRASONOGRAPHIC EXAMINATION OF THE HEART**

Canine

Poodle Toy

SEX

Spayed Female

AGE

20 years

WEIGHT

9 lbs

INTERPRETED BY

Eric Lindquist, DMV  
DABVP, Cert. IVUSS

IMAGING PERFORMED BY

Dr. Petrone

HOSPITAL NAME

Long Branch AH

REFERRING VET

Dr. Petrone

The echocardiogram in this patient demonstrated enlarged **left atrial** size based on 3 different LA measurement methods. Chamber volumes and echogenicity were normal. The cranial and caudal **mitral** valve leaflets presented vegetative thickening consistent with endocardiosis. Severe prolapse of the anterior mitral valve leaflet was noted. Doppler indicated measurable insufficiency. The **left ventricle** presented thicknesses with linear contour and was not dilated nor restricted. The **myocardium** presented normal echogenicity without subjective evidence of significant fibrotic or ischemic disease. **Contractility** of the ventricular walls was adequate and in normal range for this patient evidenced by the fractional shortening measurement and subjective evaluation of the different regions of the myocardium. The **left ventricular outflow** tract demonstrated normal laminar flow and subjective structural integrity. The **right atrium** and auricle revealed normal size, structure and content. No evidence of masses was noted or chamber overload. **Tricuspid** valvular assessment demonstrated adequate linear morphology. The **right ventricle** was of normal size (1/3 diameter of LV), chordae structure, myocardial echogenicity and thickness. **Pulmonic** tract assessment revealed normal valve structure, laminar flow, and diameter (approx. 1:1 pa/ao ratio). No visible **pericardial** or free pleura fluid was noted. No echographically detectable evidence of infiltrative disease was visible. The cranial **mediastinum and pericardial regions** were free of masses in the visible window.

CANINE	MR	TR	LA/AO	LA/AO	FS	EF	EPSS
<b>CARDIAC PARAMETERS</b>	<b>VMAX</b> (m/s)	<b>VMAX</b> (m/s)	(Boon method)	(Heart Base; Swe)	(%)	(%)	(cm)
<b>NORMAL PARAMETER</b>	4.5-5.5	<2.7	1.3	<1.3	28-40	40-100	<0.6
<b>PATIENT</b>	6.0		NM	1.8	35	80	NM
CANINE	HR	AV	PV	BODY WEIGHT	LA	LVIDd	LVIDs
<b>CARDIAC PARAMETERS</b>	(BPM)	<b>VMAX</b> (m/s)	<b>MAX</b> (m/s)		2D short axis Base view (cm)	Avg; 2D and m-mode short axis (cm)	Avg; 2D and m-mode short axis (cm)
<b>NORMAL PARAMETER</b>	50-100	0.7-1.7	0.7-1.6				
<b>PATIENT</b>	130			9 lbs	3.25 max	3.4	

**ULTRASONOGRAPHIC FINDINGS**

Mitral valve prolapse.

Advanced stage B2 valvular disease with chronic left atrial enlargement.

INVOICE

31478

DATE

7/5/22



**PATIENT**

Emily Kuiken

**SPECIES**

Canine

**BREED**

Poodle Toy

**SEX**

Spayed Female

**AGE**

20 years

**WEIGHT**

9 lbs

**INTERPRETED BY**

Eric Lindquist, DMV  
DABVP, Cert. IVUS

**IMAGING PERFORMED BY**

Dr. Petrone

**HOSPITAL NAME**

Long Branch AH

**REFERRING VET**

Dr. Petrone

**INVOICE**

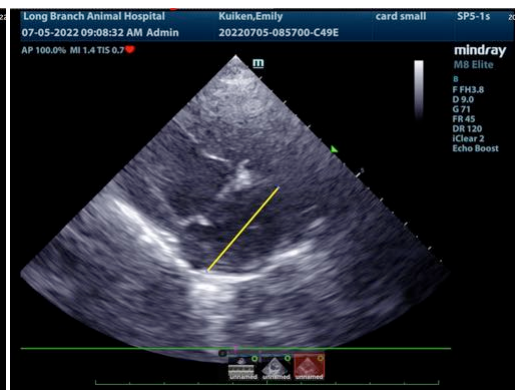
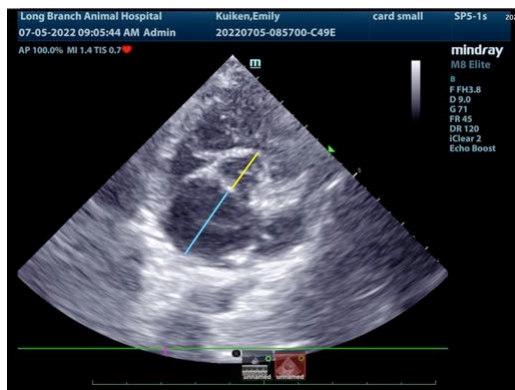
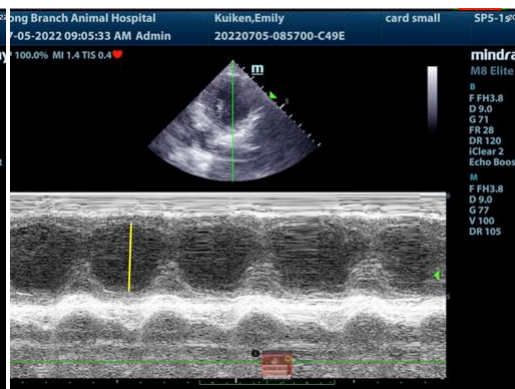
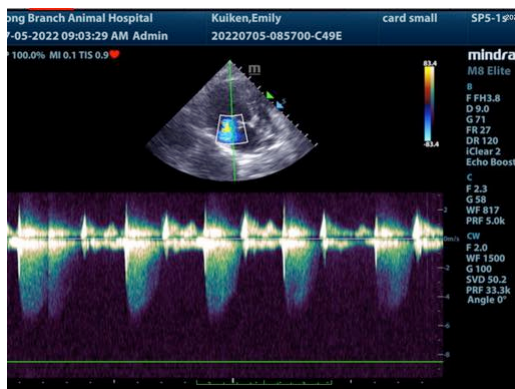
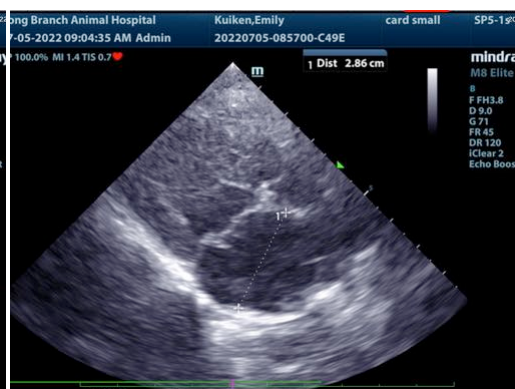
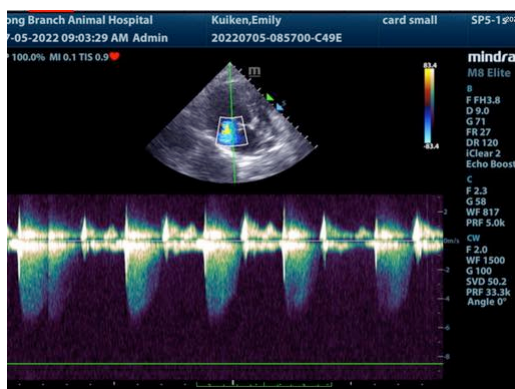
31478

**DATE**

7/5/22

**INTERPRETATION OF THE FINDINGS & FURTHER RECOMMENDATIONS**

I recommend refinement of therapy with the addition of Pimobendan adding ace inhibitor at 0.5 mg/kg s.i.d. progressing to b.i.d. and Spironolactone at 1-2 mg/kg b.i.d. A recheck echocardiogram is recommended in a month. The target respiratory rate is < 20/ minute. The main stem bronchus impingement may be an issue in this patient given the left atrial size. Assessment of radiographs are indicated. Concurrent bronchial disease may also be present. Primary respiratory protocol may be necessary.





**PATIENT**

Emily Kuiken

**SPECIES**

Canine

**BREED**

Poodle Toy

**SEX**

Spayed Female

**AGE**

20 years

**WEIGHT**

9 lbs

**INTERPRETED BY**

Eric Lindquist, DMV  
DABVP, Cert. IVUSS

**IMAGING  
PERFORMED BY**

Dr. Petrone

**HOSPITAL NAME**

Long Branch AH

**REFERRING VET**

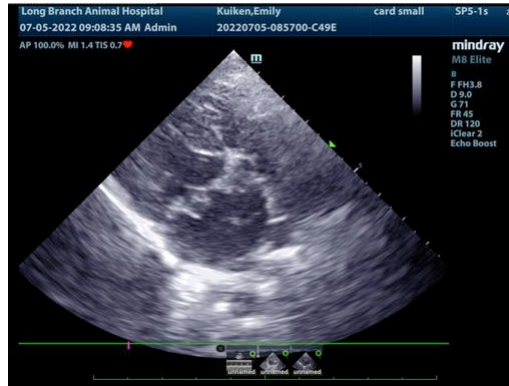
Dr. Petrone

**INVOICE**

31478

**DATE**

7/5/22



The information and recommendations provided are based on the images presented by the referring veterinarian/sonographer. No evaluation can be communicated regarding pathology that was not visible in the image/video clips provided.

Thank you for this referral. If the clinical or image interpretation does not parallel your findings or if I can be of any further assistance please contact me.

**Eric Lindquist**, DMV, DABVP, Cert. IVUSS, CEO of SonoPath.com  
info@SonoPath.com