



PATIENT

Layla O'Neill

SPECIES

Canine

BREED

Coonhound x

SEX

Spayed Female

AGE

6 Years

WEIGHT

112.6

INTERPRETED BY

Eric Lindquist, DMV

DABVP, Cert. IVUSS

IMAGING PERFORMED BY

Dr. Travis Cerf

HOSPITAL NAME

Vet Center of
Hardyston

REFERRING VET

Dr. Travis Cerf

INVOICE

44488

DATE

7/29/23

PRESENTING CLINICAL SIGNS

Asymptomatic

Abnormal PE/Chem/CBC/UA Results: elevated liver value, ALT (279)

ULTRASONOGRAPHIC EXAMINATION OF THE ABDOMEN

Urinary System

The **urinary bladder**, trigone, and pelvic urethra presented normal thicknesses and normal tone. The ureters were not visible which is normal. No uroliths or sediment were visualized and anechoic urine was present. No evidence of inflammatory or neoplastic changes were noted. Ureteral papillae were normal.

The **kidneys** revealed normal size and structure, corticomedullary definition and ratio for this age. The cortices presented largely uniform texture with normal echogenic relationship to liver and spleen. Medullary structure differed distinctly from the cortex and no evidence of pelvic dilation was present. The capsules were acceptably uniform without significant irregularities. The left kidney measured 7.9 cm. The right kidney measured 8.8 cm.

Adrenal Glands

The **left adrenal gland** was visualized and recognized as having normal shape, size, position and echogenicity for this breed. The phrenic vasculature, glandular echogenicity and detail were unremarkable. Capsule, cortex, and medullary definition were normal for this age patient. The left adrenal gland measured 2.78 cm x 0.50 cm.

The region of the **right adrenal gland** was imaged, no evident pathology.

Spleen

The **spleen** was mildly swollen at the cranial pole, not overtly pathological, positional variant. The spleen was folded upon itself cranially.

Liver

The **liver** presented mild uniform enlargement and slight coarse architecture. The gallbladder and common bile duct were unremarkable.

Gastrointestinal

Examination of the **gastrointestinal tract** revealed a stomach and intestine free of stasis, of normal wall thickness, acceptable curvilinear mural detail, and peristaltic activity. Small and large intestine demonstrated normal luminal chyme and stool consistency respectively. No obstructive or overt infiltrative disease was noted. No associated abnormal lymphatic activity was noted.

Pancreas

The base and limbs of the **pancreas** were observed to be largely isoechoic to surrounding omental fat. Pancreatic duct and capsular contour were acceptably normal and parenchyma respected normal curvilinear patterns. No overt evidence of active inflammatory or neoplastic disease was noted.



PATIENT

Layla O'Neill

SPECIES

Canine

BREED

Coonhound x

SEX

Spayed Female

AGE

6 Years

WEIGHT

112.6

INTERPRETED BY

Eric Lindquist, DMV
DABVP, Cert. IVUSS

IMAGING PERFORMED BY

Dr. Travis Cerf

HOSPITAL NAME

Vet Center of
Hardyston

REFERRING VET

Dr. Travis Cerf

INVOICE

44488

DATE

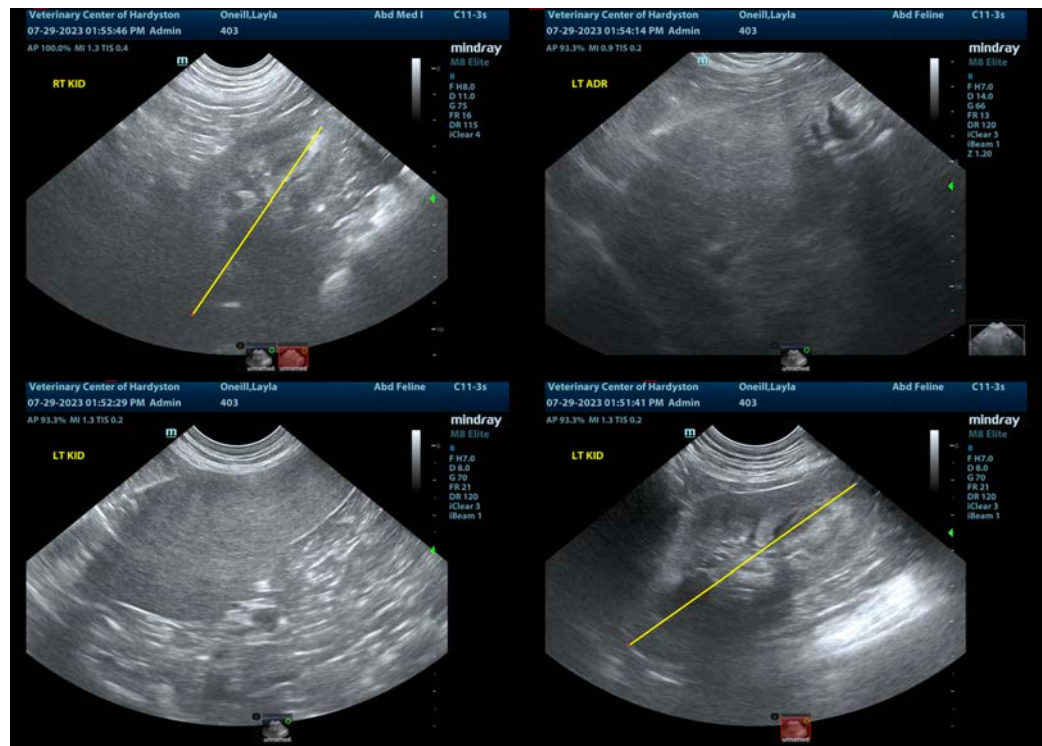
7/29/23

ULTRASONOGRAPHIC FINDINGS

- Structurally unremarkable abdomen with minor non-specific Splenohepatic enlargement, likely reactive hepatopathy

INTERPRETATION OF THE FINDINGS & FURTHER RECOMMENDATIONS

The hepatic clinical sonographic presentation is most consistent with Reactive Hepatopathy which is the most common cause of liver enzyme elevation in dogs and cats. The presumption is that gut and other organ antigen stimuli may be causing a low-grade immune response through portal system with which the liver is reacting to causing low-grade enzyme elevations. US-guided FNA could be performed to assess if low grade lymphoplasmacytic inflammation is present that would support this theory. If FNA is performed, please ask the cytologist to emphasize the primary inflammatory cell type. Empirical treatment measures to address this issue can include diet change to hydrolyzed diet, probiotics, deworming, nutraceuticals (SAMe, Actigall...), dental exam and cleaning, and potentially antibiotics such as Clavamox. Metronidazole and Tylosin have traditionally been utilized for this purpose but new studies show that both these antibiotics can disrupt the normal intestinal bacterial flora (intestinal dysbiosis) for weeks and up to 4-6 months. Therefore, Metronidazole and Tylosin should be utilized as a last resort if other efforts have not been effective and sonographic organ appearance remains benign.





PATIENT

Layla O'Neill

SPECIES

Canine

BREED

Coonhound x

SEX

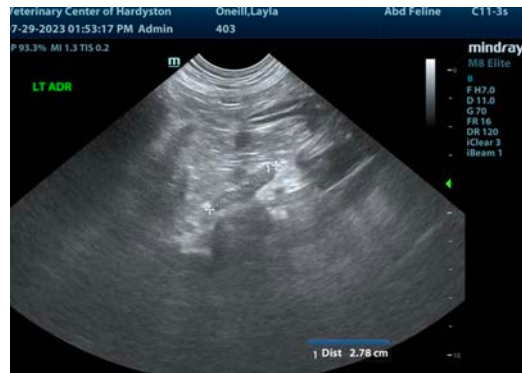Spayed Female

AGE

6 Years

WEIGHT

112.6



The information and recommendations provided are based on the images presented by the referring veterinarian/sonographer. No evaluation can be communicated regarding pathology that was not visible in the image/video clips provided.

Thank you for this referral. If the clinical or image interpretation does not parallel your findings or if I can be of any further assistance please contact me.

Eric Lindquist, DMV, DABVP, Cert. IVUSS, CEO of SonoPath.com

info@SonoPath.com

INTERPRETED BY

Eric Lindquist, DMV

DABVP, Cert. IVUSS

IMAGING PERFORMED BY

Dr. Travis Cerf

HOSPITAL NAME

Vet Center of Hardyston

REFERRING VET

Dr. Travis Cerf

INVOICE

44488

DATE

7/29/23