



PATIENT

Sawyer Zimmerman

SPECIES

Canine

BREED

Border Collie

SEX

Neutered male

AGE

7 years

WEIGHT

45.8 lbs

INTERPRETED BY

Eric Lindquist, DMV
DABVP, Cert. IVUSS

IMAGING PERFORMED BY

Carissa Rhoades

HOSPITAL NAME

Elizabeth AH

REFERRING VET

Dr. Anderson

INVOICE

32085

DATE

7/29/22

PRESENTING CLINICAL SIGNS

History: Oral ulcerations, sores on the trunk about 3 weeks ago they seem to respond to steroids. There was a recurrence of lesions. Biopsy and culture revealed 3 different bacteria, 1 resistant. In addition it revealed what appeared to be a cytotoxic reaction to medication, even though we were on no medications when it started, and an autoimmune disease. The dog is currently on chloramphenicol and immunosuppressive doses of Prednisone and cyclosporine. There has been great response in the oral cavity, but the skin seems slow to follow. X-rays and ultrasound done to look for possible underlying cancer that could be causing a paraneoplastic dermatitis.

Abnormal PE/Chem/CBC/UA Results: EXAM: NO ULCERS OR EROSIONS OR DISCOLORATION NOTED. STAGE I DENTAL DISEASE. OOZING, PAINFUL, SCABBING SORES ON FACE, PROXIMAL LIMBS, TRUNK. NO RECENT LABS

ULTRASONOGRAPHIC EXAMINATION OF THE ABDOMEN

Urinary System

The **urinary bladder**, trigone, and pelvic urethra presented normal thicknesses and normal tone. The ureters were not visible which is normal. No uroliths or sediment were visualized and anechoic urine was present. No evidence of inflammatory or neoplastic changes was noted. Ureteral papillae were normal.

The **kidneys** revealed largely normal size and structure, corticomedullary definition and ratio (cortex 1/3 of medulla) were essentially maintained with some age-related loss of curvilinear patterns regarding the capsule and C/M junction. The cortices presented largely uniform texture with some increased echogenicity expected for his age patient. Medullary structure differed distinctly from that of the cortex and no evidence of pelvic dilation was present. The left kidney measured 5.66 cm. The right kidney measured 5.5 cm.

Adrenal Glands

Both **adrenal glands** were visualized and recognized as having normal shape, size, position and echogenicity for this breed. The phrenic vasculature, glandular echogenicity and detail were unremarkable. Capsule, cortex, and medullary definition were normal for this age patient. The right adrenal gland measured 2.44 x 0.55 cm at the caudal pole and 0.76 cm at the cranial pole. The left adrenal gland measured 2.5 x 0.63 cm at the cranial pole and 0.38 cm at the caudal pole.

Spleen

The **spleen** presented a smooth homogeneous parenchyma hyperechoic to liver and renal cortical parenchyma. The capsule was smooth without noticeable expansion or deviation from within the spleen or adjacent pathology. The splenic vasculature demonstrated normal volume without signs of congestion or thrombosis. No sonographic evidence of acute or chronic inflammatory, neoplastic, or infarctual changes was noted.

Liver

The **liver** was uniformly swollen with minor, excessive gallbladder debris and over distension with dependent and suspended bile without evidence of overt mucocele formation. However, excessive



PATIENT

Sawyer Zimmerman

sludge was present. The liver presented coarse architecture with mildly increased portal markings and subtle, mixed echogenic changes. This is consistent with vacuolar hepatopathy and some level of remodeling and history of inflammatory component. There was no overt suspicion of neoplasia.

SPECIES

Canine

Gastrointestinal

A minor amount of non-shadowing, non-obstructive ingesta was noted in the stomach. Transit of chyme into the small intestine was normal. Curvilinear patterns were maintained throughout the GI tract. No evidence of pathology. Small and large intestine demonstrated normal luminal chyme and stool consistency respectively. No obstructive or overt infiltrative disease was noted. No associated abnormal lymphatic activity was noted.

BREED

Border Collie

SEX

Neutered male

Pancreas

The base and limbs of the **pancreas** were observed to be largely isoechoic to surrounding omental fat. Pancreatic duct and capsular contour were acceptably normal and parenchyma respected normal curvilinear patterns. No overt evidence of active inflammatory or neoplastic disease was noted.

AGE

7 years

ULTRASONOGRAPHIC FINDINGS

WEIGHT

45.8 lbs

Benign hepatopathy.

Unremarkable abdomen otherwise.

INTERPRETED BY

Eric Lindquist, DMV
DABVP, Cert. IVUSS

INTERPRETATION OF THE FINDINGS & FURTHER RECOMMENDATIONS

There was no evidence of significant disease. The hepatic presentation may be related to the Prednisone therapy.

IMAGING PERFORMED BY

Carissa Rhoades

HOSPITAL NAME

Elizabeth AH

REFERRING VET

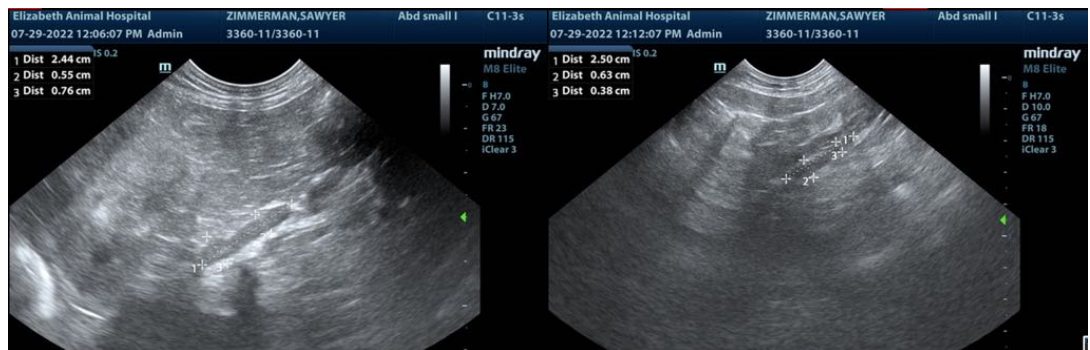
Dr. Anderson

INVOICE

32085

DATE

7/29/22





PATIENT

Sawyer Zimmerman

SPECIES

Canine

BREED

Border Collie

SEX

Neutered male

AGE

7 years

WEIGHT

45.8 lbs

INTERPRETED BY

Eric Lindquist, DMV
DABVP, Cert. IVUSS

IMAGING PERFORMED BY

Carissa Rhoades

HOSPITAL NAME

Elizabeth AH

REFERRING VET

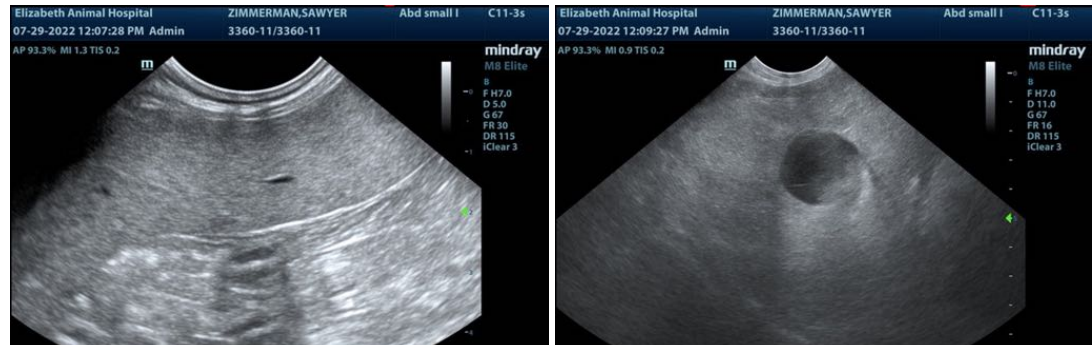
Dr. Anderson

INVOICE

32085

DATE

7/29/22



The information and recommendations provided are based on the images presented by the referring veterinarian/sonographer. No evaluation can be communicated regarding pathology that was not visible in the image/video clips provided.

Thank you for this referral. If the clinical or image interpretation does not parallel your findings or if I can be of any further assistance please contact me.

Eric Lindquist, DMV, DABVP, Cert. IVUSS, CEO of SonoPath.com
info@SonoPath.com