



**PATIENT PRESENTING CLINICAL SIGNS**

Chloe Paiva History: Decrease appetite, lethargic, R/O abdominal neoplasia Current medications: Incurin 1mg 1 tab SID  
Abnormal PE/Chem/CBC/UA Results: Creat 1.7/ Ca #15.7 CBC AI. Hemoconcentration Abnormal U/A findings: Not done Urine specific gravity: N/A

**SPECIES**

Canine

**BREED**

Pitbull Mix

**SEX**

Female

**AGE**

11 years

**WEIGHT**

42.5 lbs

**INTERPRETED BY**

Eric Lindquist, DMV  
DABVP, Cert. IVUSS

**IMAGING PERFORMED BY**

Dr. Abdul-Chani

**HOSPITAL NAME**

Byram AH

**REFERRING VET**

Dr. Cruz

**INVOICE**

32039

**DATE**

7/28/22

**ULTRASONOGRAPHIC EXAMINATION OF THE ABDOMEN**

**Urinary System**

The **urinary bladder**, trigone, and pelvic urethra presented normal thicknesses and normal tone. The ureters were not visible which is normal. No uroliths or sediment were visualized and anechoic urine was present. No evidence of inflammatory or neoplastic changes was noted. Ureteral papillae were normal.

The **kidneys** revealed normal size and structure, corticomedullary definition and ratio for this age. The cortices presented largely uniform texture with normal echogenic relationship to liver and spleen. Medullary structure differed distinctly from the cortex and no evidence of pelvic dilatation was present. The capsules were acceptably uniform without significant irregularities. The right kidney measured 5.95 cm. The left kidney measured 5.57 cm.

**Adrenal Glands**

Both **adrenal glands** were visualized and recognized as having normal shape, size, position and echogenicity for this breed. The phrenic vasculature, glandular echogenicity and detail were unremarkable. Capsule, cortex, and medullary definition were normal for this age patient. The left adrenal gland measured 2.5 x 0.61 cm at the caudal pole and 0.45 cm at the cranial pole. The right adrenal gland measured 2.97 x 0.88 cm at the cranial pole and 0.55 cm at the caudal pole.

**Spleen**

The **spleen** was mildly enlarged and slightly folded upon itself with uniform parenchyma.

**Liver**

The **liver** images submitted revealed subjectively normal liver size, contour, and structure. Parenchymal echogenicity was naturally coarse and hypoechoic to the spleen. Vascular and biliary tracts were of normal volume with no evidence of congestion. The gallbladder presented acceptably thin walls with primarily anechoic content. The cystic and common bile ducts were normal. No pathological hepatic lymphadenopathy was evident. No overt structural evidence of inflammatory, infiltrative or regenerative pathology was evident.



**PATIENT**

**Gastrointestinal**

Chloe Paiva

Examination of the **gastrointestinal tract** revealed a stomach and intestine free of stasis, of normal wall thickness, acceptable curvilinear mural detail, and peristaltic activity. Small and large intestine demonstrated normal luminal chyme and stool consistency respectively. No obstructive or overt infiltrative disease was noted. No associated abnormal lymphatic activity was noted.

**SPECIES**

Canine

**Pancreas**

**BREED**

Pitbull Mix

The base and limbs of the **pancreas** were observed to be largely isoechoic to surrounding omental fat. Pancreatic duct and capsular contour were acceptably normal and parenchyma respected normal curvilinear patterns. No overt evidence of active inflammatory or neoplastic disease was noted.

**SEX**

Female

**ULTRASONOGRAPHIC FINDINGS**

Normal abdomen with minor hypersplenism.

**AGE**

11 years

**INTERPRETATION OF THE FINDINGS & FURTHER RECOMMENDATIONS**

There is no evidence of significant disease.

**WEIGHT**

42.5 lbs

**INTERPRETED BY**

Eric Lindquist, DMV  
DABVP, Cert. IVUSS

**IMAGING PERFORMED BY**

Dr. Abdul-Chani

**HOSPITAL NAME**

Byram AH

**REFERRING VET**

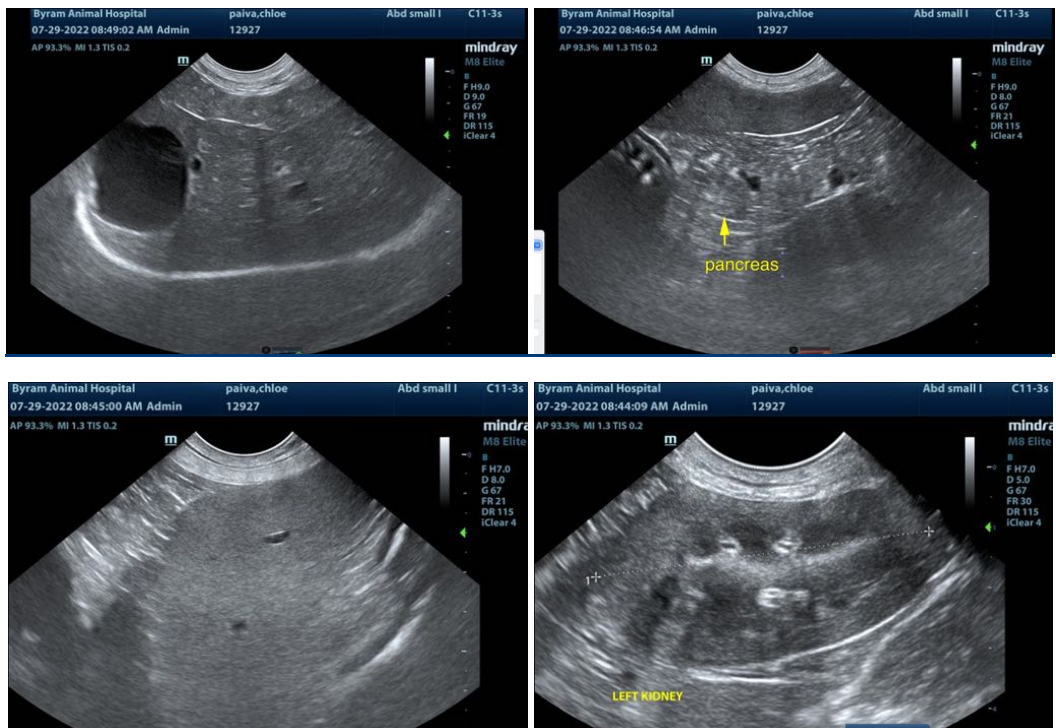
Dr. Cruz

**INVOICE**

32039

**DATE**

7/28/22





**PATIENT**

Chloe Paiva

**SPECIES**

Canine

**BREED**

Pitbull Mix

**SEX**

Female

**AGE**

11 years

**WEIGHT**

42.5 lbs

**INTERPRETED BY**

Eric Lindquist, DMV  
DABVP, Cert. IVUSS

**IMAGING PERFORMED BY**

Dr. Abdul-Chani

**HOSPITAL NAME**

Byram AH

**REFERRING VET**

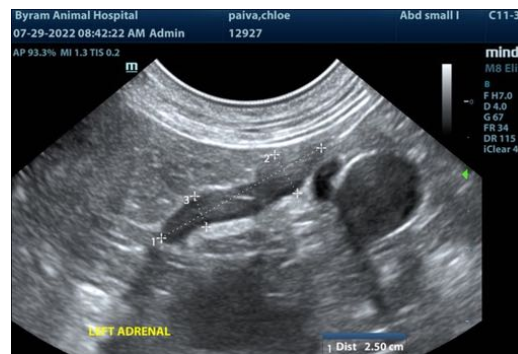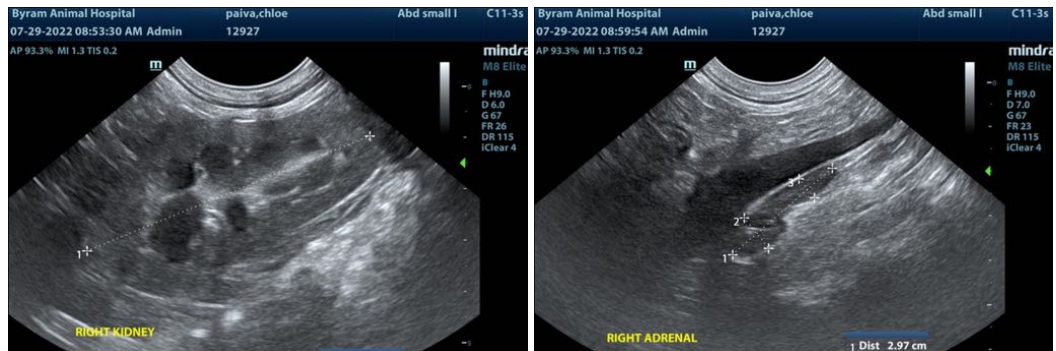
Dr. Cruz

**INVOICE**

32039

**DATE**

7/28/22



The information and recommendations provided are based on the images presented by the referring veterinarian/sonographer. No evaluation can be communicated regarding pathology that was not visible in the image/video clips provided.

Thank you for this referral. If the clinical or image interpretation does not parallel your findings or if I can be of any further assistance please contact me.

**Eric Lindquist**, DMV, DABVP, Cert. IVUSS, CEO of SonoPath.com  
info@SonoPath.com