



PATIENT

Monica Garofalo

SPECIES

Feline

BREED

DSH

SEX

Spayed Female

AGE

14 Years 9 Months

WEIGHT

3.96 kg

PRESENTING CLINICAL SIGNS

History: O noted distended abdomen over the previous week. Still doing well overall.

Abnormal PE/Chem/CBC/UA Results: Normal chemistry, CBC showed mild monocytosis, neutrophilia, and basophilia

ULTRASONOGRAPHIC EXAMINATION OF THE HEART & ABDOMEN

FELINE CARDIAC PARAMETERS	BODY WEIGHT (kg)	HR (BPM)	IVSd (cm)	LVIDd (cm)	LVWd (cm)	FS (%)	EF (%)
NORMAL PARAMETER	-----	150-240	0.3-0.6	1.0-2.1	0.25-0.6	35-67	80-100
PATIENT	--	NM	0.45	1.2	0.45	50	--
FELINE CARDIAC PARAMETERS	LA/AO (Boon)	LA/AO HEART BASE (Sisson)	LA 2D 4-chamber long axis AS to FW (Sisson) (cm)	LVOT VEL. (m/s)	RVOT VEL. (m/s)	IVRT (m/)	
NORMAL PARAMETER	<1.5	0.88-1.79	0.7-1.7	<1.6	<1.3	40-60	
PATIENT	1.0	1.1	1.15	--	1.50	NM	
Adapted from June Boon, Veterinary Echocardiography, 1998							
Sisson D et al. JVIM 1991; 5: 232, Jacobs et al. Am J Vet Res 1985; 46:1705							

INTERPRETED BY

Eric Lindquist, DMV
DABVP, Cert. IVUSS

IMAGING PERFORMED BY

Megan Odgers, VMD

HOSPITAL NAME

Pennsauken AH & UC

REFERRING VET

Megan Odgers, VMD

INVOICE

23666

DATE

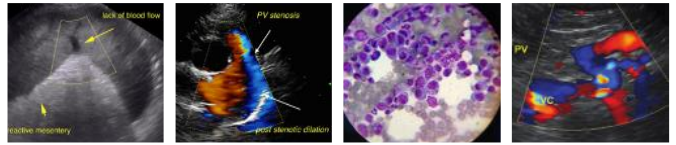
7/29/23

Cardiac Presentation

The echocardiogram in this patient demonstrated normal **left atrial** size based on 3 separate LA measurements. The cranial and caudal **mitral** valve leaflets presented normal linear structure and kinetics. The **left ventricle** presented normal thicknesses with linear contour and was not dilated nor restricted. The **myocardium** presented normal echogenicity without subjective evidence of significant fibrotic or ischemic disease. **Contractility** of the ventricular walls was adequate and in normal range for this patient evidenced by the fractional shortening measurement and subjective evaluation of the different regions and angles of the myocardium. The **left ventricular outflow** tract demonstrated normal laminar flow and subjective structural integrity. The **right atrium** and auricle revealed normal size, structure and content. No evidence of masses was noted or chamber overload. **Tricuspid** valvular assessment demonstrated adequate linear morphology and kinetics. The **right ventricle** was of normal size (1/3 diameter of LV), chordae structure, myocardial echogenicity and thickness. **Pulmonic** tract assessment revealed normal valve structure, laminar flow, and diameter (approx. 1:1 pa/ao ratio). No visible **pericardial** or free pleura fluid was noted or extra cardiac pathology in the visible planes. The cranial **mediastinum and pericardial regions** were free of masses in the visible window.

Urinary System

The **urinary bladder**, trigone, and pelvic urethra presented normal thicknesses and normal tone. The ureters were not visible which is normal. No uroliths or sediment were visualized and anechoic urine was present. No evidence of inflammatory or neoplastic changes were noted. Ureteral papillae were normal.



PATIENT

Monica Garofalo

SPECIES

Feline

BREED

DSH

SEX

Spayed Female

AGE

14 Years 9 Months

WEIGHT

3.96 kg

INTERPRETED BY

Eric Lindquist, DMV
DABVP, Cert. IVUSS

IMAGING PERFORMED BY

Megan Odgers, VMD

HOSPITAL NAME

Pennsauken AH & UC

REFERRING VET

Megan Odgers, VMD

INVOICE

23666

DATE

7/29/23

The **kidneys** revealed largely normal size and structure, corticomedullary definition and ratio (cortex 1/3 of medulla) were essentially maintained with some age-related loss of curvilinear patterns regarding the capsule and C/M junction. The cortices presented largely uniform texture with some increased echogenicity expected for his age patient. Medullary structure differed distinctly from that of the cortex and no evidence of pelvic dilation was present. The left kidney measured 4.0 cm. The right kidney measured 4.2 cm.

Adrenal Glands

The regions of the **adrenal glands** revealed no evident pathology.

Spleen

The **spleen** in this patient was uniform, yet volume contracted. Hydration status should be assessed.

Liver

The **liver** images submitted revealed subjectively normal liver size, contour, and structure. Parenchymal echogenicity was naturally coarse and hypoechoic to the spleen. Vascular and biliary tracts were of normal volume. The gallbladder presented acceptably thin walls with primarily anechoic content. The cystic and common bile ducts were normal. No pathological hepatic lymphadenopathy was evident. No overt structural evidence of inflammatory, infiltrative or regenerative pathology was evident. No evidence of passive congestion that would suggest ascites secondary to thoracic disease.

Gastrointestinal

Examination of the **gastrointestinal tract** revealed a stomach and intestine free of stasis, of normal wall thickness, acceptable curvilinear mural detail, and peristaltic activity. Small and large intestine demonstrated normal luminal chyme and stool consistency respectively. No obstructive or overt infiltrative disease was noted. No associated abnormal lymphatic activity was noted.

Pancreas

A mixed hypoechoic nodular mass was noted in the region of the right **pancreatic** limb, measuring 3.45 cm. Regional lymph nodes were also enlarged.

Free Abdomen

A large amount of echogenic **free fluid** was noted in the abdomen. Nodular omentum was noted throughout the mid abdomen, enveloping the upper gastrointestinal tract.

ULTRASONOGRAPHIC FINDINGS

- Normal echocardiogram- no evidence of cardiac disease.
- Nodular omental and pancreatic masses, strongly consistent with carcinomatosis, lymphomatosis, mastocytosis or similar
- Free fluid
- Volume contracted spleen

INTERPRETATION OF THE FINDINGS & FURTHER RECOMMENDATIONS

Abdominocentesis and cytospin with immediate slide preparation are recommended to assess neoplastic cells. FIP is a remote potential yet unlikely given the age. Prognosis is poor.



PATIENT

Monica Garofalo

SPECIES

Feline

BREED

DSH

SEX

Spayed Female

AGE

14 Years 9 Months

WEIGHT

3.96 kg

INTERPRETED BY

Eric Lindquist, DMV
DABVP, Cert. IVUSS

IMAGING PERFORMED BY

Megan Odgers, VMD

HOSPITAL NAME

Pennsauken AH & UC

REFERRING VET

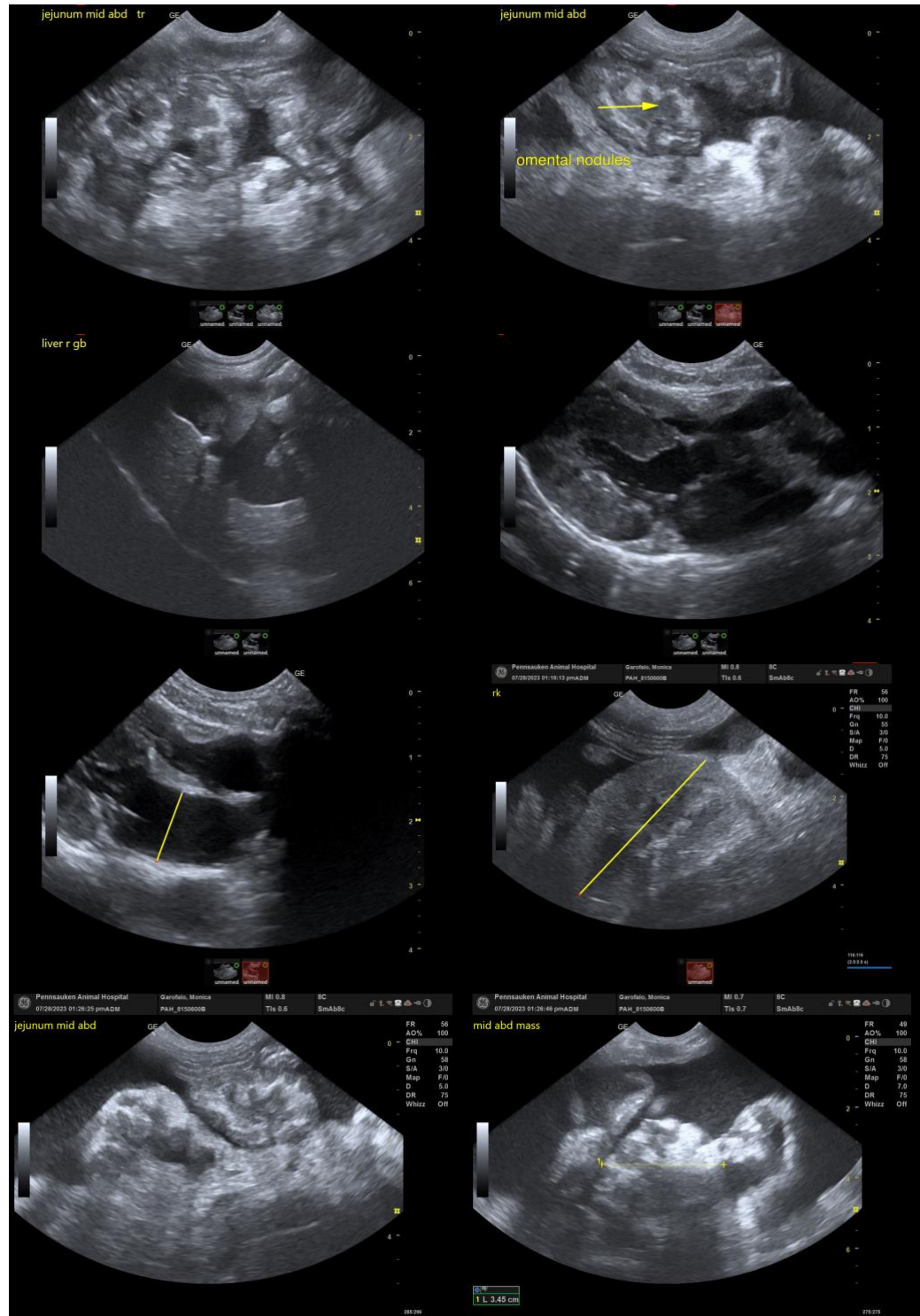
Megan Odgers, VMD

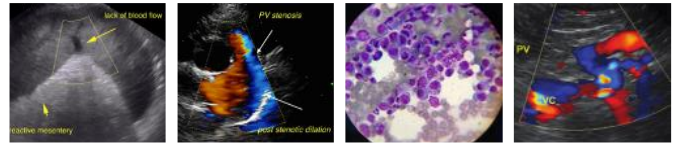
INVOICE

23666

DATE

7/29/23





PATIENT

Monica Garofalo

SPECIES

Feline

BREED

DSH

SEX

Spayed Female

AGE

14 Years 9 Months

WEIGHT

3.96 kg

INTERPRETED BY

Eric Lindquist, DMV
DABVP, Cert. IVUSS

IMAGING PERFORMED BY

Megan Odgers, VMD

HOSPITAL NAME

Pennsauken AH & UC

REFERRING VET

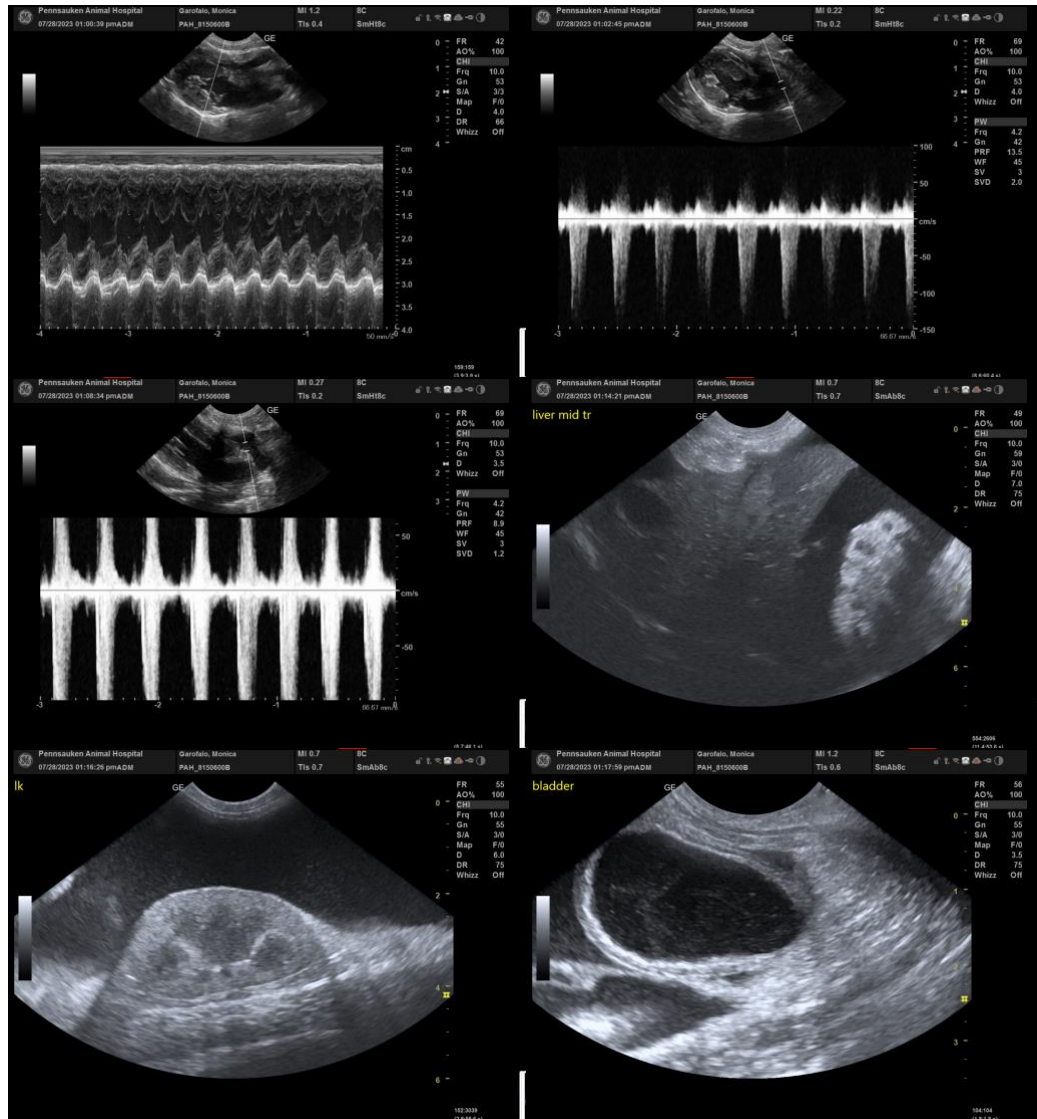
Megan Odgers, VMD

INVOICE

23666

DATE

7/29/23



The information and recommendations provided are based on the images presented by the referring veterinarian. No evaluation can be communicated regarding pathology that was not visible in the image/video clips provided.

Thank you for this referral. If the clinical or image interpretation does not parallel your findings or if I can be of any further assistance please contact me.

Eric Lindquist, DMV, DABVP, Cert. IVUSS, CEO of SonoPath.com
info@SonoPath.com