



PATIENT

Elmo Kang

SPECIES

Canine

BREED

Bichon Frise

SEX

Neutered Male

AGE

6 Years

WEIGHT

6.4 kg

INTERPRETED BY

Eric Lindquist, DMV
DABVP, Cert. IVUSS

IMAGING PERFORMED BY

Dr. Sarah Barthelemy

HOSPITAL NAME

Fish Creek PH

REFERRING VET

Fish Creek PH

INVOICE

23645

DATE

7/28/23

PRESENTING CLINICAL SIGNS

History of epilepsy which is normally managed with anti-convulsants. Recent seizure activity as owner couldn't admin meds to her due to inappetence. Episodes of vomiting.

ULTRASONOGRAPHIC EXAMINATION OF THE ABDOMEN

Urinary System

The **urinary bladder**, trigone, and pelvic urethra presented normal thicknesses and normal tone. The ureters were not visible which is normal. No uroliths or sediment were visualized and anechoic urine was present. No evidence of inflammatory or neoplastic changes were noted. Ureteral papillae were normal.

The **kidneys** revealed normal size and structure, corticomedullary definition and ratio for this age. The cortices presented largely uniform texture with normal echogenic relationship to liver and spleen. Medullary structure differed distinctly from the cortex and no evidence of pelvic dilation was present. The capsules were acceptably uniform without significant irregularities. The right kidney measured 4.04 cm. The left kidney measured 3.88 cm.

Adrenal Glands

Both **adrenal glands** were visualized and recognized as having normal shape, size, position and echogenicity for this breed. The phrenic vasculature, glandular echogenicity and detail were unremarkable. Capsule, cortex, and medullary definition were normal for this age patient. The left adrenal gland measured 0.32 cm at the cranial pole and 0.49 cm at the caudal pole. The right adrenal gland measured 0.49 cm at the caudal pole and 0.6 cm at the cranial pole.

Spleen

The **spleen** presented a smooth homogeneous parenchyma hyperechoic to liver and renal cortical parenchyma. The capsule was smooth without noticeable expansion or deviation from within the spleen or adjacent pathology. The splenic vasculature demonstrated normal volume without signs of congestion or thrombosis. No sonographic evidence of acute or chronic inflammatory, neoplastic, or infarctual changes were noted. Caudal folding of the spleen was noted.

Liver

The **liver** images submitted revealed subjectively normal liver size, contour, and structure. Parenchymal echogenicity was naturally coarse and hypoechoic to the spleen. Vascular and biliary tracts were of normal volume with no evidence of congestion. The gallbladder presented acceptably thin walls with primarily anechoic content. The cystic and common bile ducts were normal. No pathological hepatic lymphadenopathy was evident. No overt structural evidence of inflammatory, infiltrative or regenerative pathology was evident.

Gastrointestinal

The **stomach** in this patient revealed a gastric wall thickening with a linear foreign body attachment, continuing from the stomach through the pylorus, into the upper duodenum with accordion pleating at the mid jejunum. The proximal attachment of the foreign body could not be ascertained. I recommend assessing the base on the tongue at the time of sedation. Variable intestinal thickening was noted without loss of mural detail. Regional lymph node enlargement was noted adjacent to the stomach.

Pancreas



PATIENT

Elmo Kang

The base and limbs of the **pancreas** were observed to be largely isoechoic to surrounding omental fat. Pancreatic duct and capsular contour were acceptably normal and parenchyma respected normal curvilinear patterns. No overt evidence of active inflammatory or neoplastic disease was noted.

SPECIES

Canine

ULTRASONOGRAPHIC FINDINGS

- Linear foreign body obstruction with upper gastrointestinal thickening- Chronic gastritis, along with foreign body is likely. Mild potential for underlying GI neoplasia.

BREED

Bichon Frise

INTERPRETATION OF THE FINDINGS & FURTHER RECOMMENDATIONS

I recommend assessing the base of the tongue at the time of sedation. GI biopsies are essential in this patient.

SEX

GI Foreign Body Research

Neutered Male

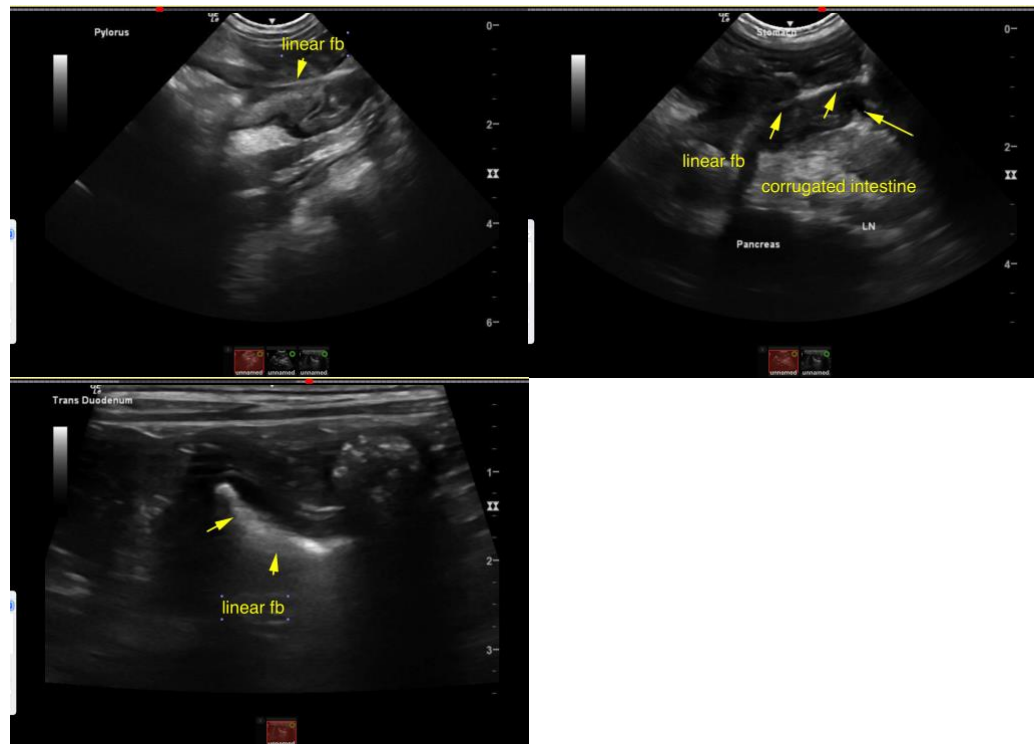
According to Sonopath research presented at ECVIM 2016 (Stockholm, Sweden), Advances in Small Animal Medicine and Surgery (May 2017), and EVDI 2017 (Verona, Italy), concurrent underlying chronic inflammatory neoplastic intestinal disease can often reside in PICA patients. Therefore, surgical biopsies are essential in this case regardless of the exploratory findings.

AGE

6 Years

WEIGHT

6.4 kg



INTERPRETED BY

Eric Lindquist, DMV
DABVP, Cert. IVUSS

IMAGING PERFORMED BY

Dr. Sarah Barthelemy

HOSPITAL NAME

Fish Creek PH

REFERRING VET

Fish Creek PH

INVOICE

23645

The information and recommendations provided are based on the images presented by the referring veterinarian. No evaluation can be communicated regarding pathology that was not visible in the image/video clips provided.

DATE

7/28/23

Thank you for this referral. If the clinical or image interpretation does not parallel your findings or if I can be of any further assistance please contact me.



PATIENT

Eric Lindquist, DMV, DABVP, Cert. IVUSS, CEO of SonoPath.com
info@SonoPath.com

Elmo Kang

SPECIES

Canine

BREED

Bichon Frise

SEX

Neutered Male

AGE

6 Years

WEIGHT

6.4 kg

INTERPRETED BY

Eric Lindquist, DMV
DABVP, Cert. IVUSS

**IMAGING
PERFORMED BY**

Dr. Sarah Barthelemy

HOSPITAL NAME

Fish Creek PH

REFERRING VET

Fish Creek PH

INVOICE

23645

DATE

7/28/23