



## PATIENT

Darby Elgin

## SPECIES

Canine

## BREED

Corgi

## SEX

Spayed Female

## AGE

9

## WEIGHT

31

## INTERPRETED BY

Eric Lindquist, DMV  
DABVP, Cert. IVUSS

## IMAGING PERFORMED BY

Torch River VMS

## HOSPITAL NAME

East Bay PH

## REFERRING VET

Dr. Karen Seiple

## INVOICE

23658

## DATE

7/28/23

## PRESENTING CLINICAL SIGNS

History: Presented for personality changes barking more; increased anxiety; increased herding behavior

Abnormal PE/Chem/CBC/UA Results: Bloodwork pending Cardiomegaly (stable since 2021) L apex of heart has possible pericardial mass

## ULTRASONOGRAPHIC EXAMINATION OF THE HEART

CANINE CARDIAC PARAMETERS	MR VMAX (m/s)	TR VMAX (m/s)	LA/AO (Boon method)	LA/AO (Heart Base; Swe)	FS (%)	EF (%)	EPSS (cm)
NORMAL PARAMETER	4.5-5.5	<2.7	1.3	<1.6	28-40	40-100	<0.6
PATIENT	--	--	NM	1.1	35	--	0.2
CANINE CARDIAC PARAMETERS	HR (BPM)	AV VMAX (m/s)	PV MAX (m/s)	BODY WEIGHT (kg)	LA 2D short axis Base view (cm)	LVIDd Avg; 2D and m-mode short axis (cm)	LVIDs Avg; 2D and m-mode short axis (cm)
NORMAL PARAMETER	50-100	0.7-1.7	0.7-1.6				
PATIENT	--	1.50	.80	--	2.4	2.7	--

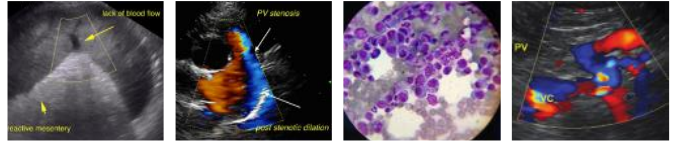
## Cardiac Presentation

The echocardiogram in this patient demonstrated normal **left atrial** size based on 3 separate methods of LA evaluation. The cranial and caudal **mitral** valve leaflets presented normal linear structure, extension in systole, and union in diastole with normal kinesis. The **left ventricle** presented thicknesses with linear contour and was not dilated nor restricted. The **myocardium** presented normal echogenicity without subjective evidence of significant fibrotic or ischemic disease.

**Contractility** of the ventricular walls was adequate and in normal range for this patient evidenced by the fractional shortening measurement and subjective evaluation of the different regions of the myocardium. The **left ventricular outflow** tract demonstrated normal laminar flow and subjective structural integrity. The **right atrium** and auricle revealed normal size, structure and content. No evidence of masses was noted. **Tricuspid** valvular assessment demonstrated adequate linear morphology and kinesis. The **right ventricle** was of normal size (1/3 diameter of LV), chordae structure, myocardial echogenicity and thickness. **Pulmonary outflow** tract assessment revealed normal valve structure, laminar flow, and diameter (approx. 1:1 pa/ao ratio). No visible **pericardial** or free pleura fluid was noted. The cranial **mediastinum and pericardial and extra-cardiac regions** were free of masses in the visible window.

## ULTRASONOGRAPHIC FINDINGS

- Normal echocardiogram



**PATIENT**

Darby Elgin

**INTERPRETATION OF THE FINDINGS & FURTHER RECOMMENDATIONS**

No evidence of pathology. No evidence of cardiac neoplasia.

**SPECIES**

Canine

**BREED**

Corgi

**SEX**

Spayed Female

**AGE**

9

**WEIGHT**

31

**INTERPRETED BY**

Eric Lindquist, DMV  
DABVP, Cert. IVUSS

**IMAGING PERFORMED BY**

Torch River VMS

**HOSPITAL NAME**

East Bay PH

**REFERRING VET**

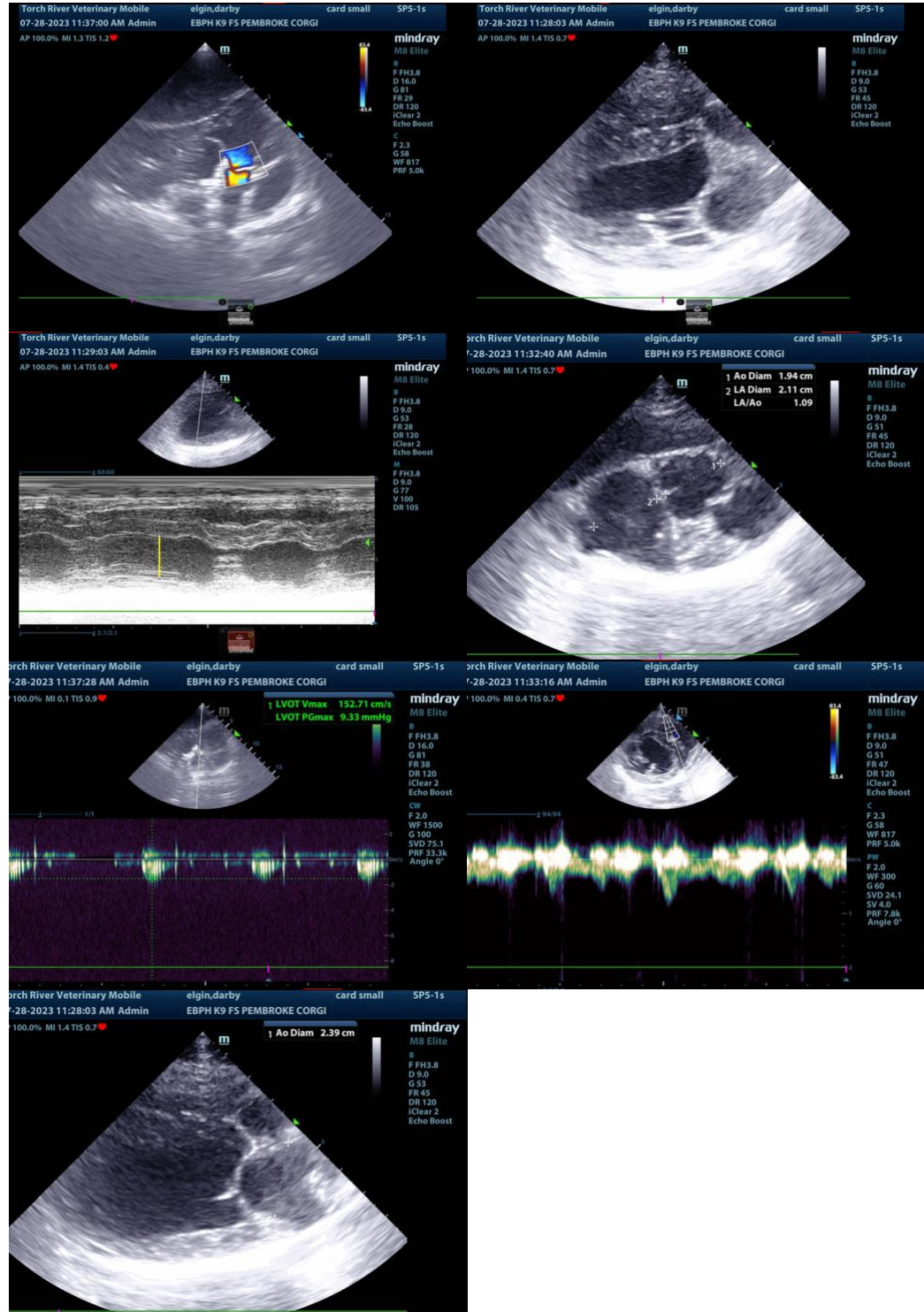
Dr. Karen Seiple

**INVOICE**

23658

**DATE**

7/28/23



The information and recommendations provided are based on the images presented by the



**PATIENT**

Darby Elgin

**referring veterinarian. No evaluation can be communicated regarding pathology that was not visible in the image/video clips provided.**

Thank you for this referral. If the clinical or image interpretation does not parallel your findings or if I can be of any further assistance please contact me.

**SPECIES**

Canine

**Eric Lindquist**, DMV, DABVP, Cert. IVUSS, CEO of SonoPath.com

info@SonoPath.com

**BREED**

Corgi

**SEX**

Spayed Female

**AGE**

9

**WEIGHT**

31

**INTERPRETED BY**

Eric Lindquist, DMV  
DABVP, Cert. IVUSS

**IMAGING  
PERFORMED BY**

Torch River VMS

**HOSPITAL NAME**

East Bay PH

**REFERRING VET**

Dr. Karen Seiple

**INVOICE**

23658

**DATE**

7/28/23