



PATIENT

Sayanna Griffin

SPECIES

Canine

BREED

Shih Tzu

SEX

Spayed female

AGE

8 years

WEIGHT

7.9 kg

PRESENTING CLINICAL SIGNS

History: ****Single organ**** Present recumbent in clinic - Owner noted intense vomiting starting at 10:30p last night, inappetence yesterday evening, Liquid/bloody diarrhea starting at 2:00a . Was fine yesterday am. No known toxin exp though I am very suspicious due to symptoms/results from lab
 Abnormal PE/Chem/CBC/UA Results: Cannot hold up head, severely dehydrated, bloody stool on rectal exam. Hct 74.4%, monos2.42 (0.16-1.12) Creat 2.4, sdma, bun normal. Glucose 27, has been getting dextrose infusion, 3ml corn syrup po, and bg remains low (2,4mmol/L). Glob 5.1, tp 8.7, alkP 1536, remainder of liver vals normal. chol 358. Na/K 27, cortisol pending

ULTRASONOGRAPHIC EXAMINATION

Gastrointestinal

Tissue thickening was noted in the jejunum occupying the lumen and measured approximately 1.0 cm. Dilated bowel was noted prior to the structure and was repeatable. The tissue thickening was noted in multiple views and appears to be a prominent, ileocecal junction. This measured approximately 1.0 cm. It appears to be ileocecal junction with a fluid filled colon. I recommend a recheck sonogram in a week.

ULTRASONOGRAPHIC FINDINGS

Tissue thickening in the intestine. Suspect ileocecolic junction.

INTERPRETATION OF THE FINDINGS & FURTHER RECOMMENDATIONS

This should be monitored.

INTERPRETED BY

Eric Lindquist, DMV
DABVP, Cert. IVUSS

IMAGING PERFORMED BY

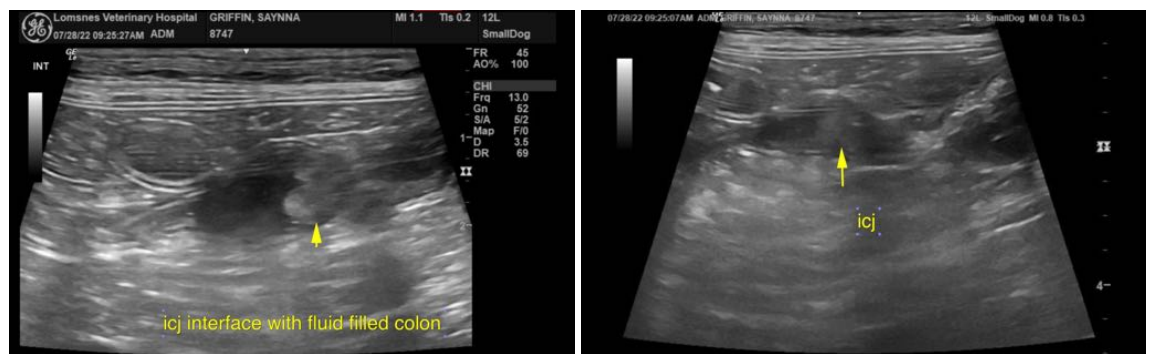
Dr. Biederbeck

HOSPITAL NAME

Lomsnes VH

REFERRING VET

Dr. Biederbeck



INVOICE

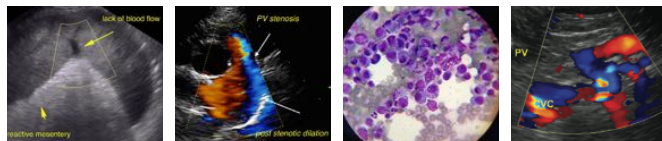
32040

DATE

7/28/22

The information and recommendations provided are based on the images presented by the referring veterinarian/sonographer. No evaluation can be communicated regarding pathology that was not visible in the image/video clips provided.

Thank you for this referral. If the clinical or image interpretation does not parallel your findings or if I can be of any further assistance please contact me.



PATIENT

Eric Lindquist, DMV, DABVP, Cert. IVUSS, CEO of SonoPath.com
info@SonoPath.com

Sayanna Griffin

SPECIES

Canine

BREED

Shih Tzu

SEX

Spayed female

AGE

8 years

WEIGHT

7.9 kg

INTERPRETED BY

Eric Lindquist, DMV
DABVP, Cert. IVUSS

**IMAGING
PERFORMED BY**

Dr. Biederbeck

HOSPITAL NAME

Lomsnes VH

REFERRING VET

Dr. Biederbeck

INVOICE

32040

DATE

7/28/22