



## PATIENT

Sunny Humphreys  
Drysdale

## SPECIES

Feline

## BREED

Domestic Shorthair

## SEX

Neutered male

## AGE

14 years

## WEIGHT

4.53 kg

## INTERPRETED BY

Eric Lindquist, DMV  
DABVP, Cert. IVUSS

## IMAGING PERFORMED BY

Dr. Varga

## HOSPITAL NAME

Shuswap VC

## REFERRING VET

Dr. Varga

## INVOICE

76292

## DATE

7/27/23

## PRESENTING CLINICAL SIGNS

History: Presented to emergency clinic Friday July 21st with pleural effusion. 200mls of serosanguinous effusion removed via thoracocentesis which stabilized patient. Bloodwork showed moderate non-regenerative anemia (anemia was previously present on bloodwork from May from referring clinic). Pro BNP was "abnormal" per emerg clinic. Started on furosemide 10mg PO q 12hrs and was reportedly markedly improved on presentation to me on Monday.- improved energy level and appetite and O reports normal respiratory effort and RRR of ~36 breaths/minute.  
Abnormal PE/Chem/CBC/UA Results: Exam on Monday- pulses weak but synchronous. No murmur appreciated on initial exam but was reported by emerg vet. BCS= 3/9. MM= pale pink. patient is fractious during exam. Sedated IM butorphanol 0.4mg/kg to place IV catheter.

## ULTRASONOGRAPHIC EXAMINATION OF THE HEART

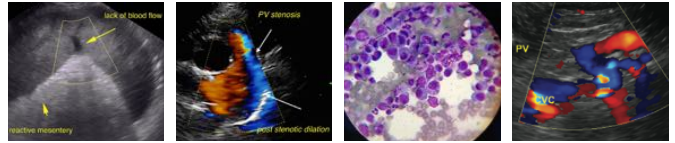
The echocardiogram in this patient presented moderate to severe volume overload in all four chambers. Right and left atrial enlargement was noted with hypocontractility and mild pericardial and moderate to severe pleural effusion. Septal and free wall thicknesses were fairly normal, yet contractility was subnormal. A minor amount of smoke was noted in the base of the left atrium.

FELINE CARDIAC PARAMETERS	BODY WEIGHT (kg)	HR (BPM)	IVSd (cm)	LVIDd (cm)	LVWd (cm)	FS (%)	EF (%)
NORMAL PARAMETER	-----	150-240	0.3-0.6	1.0-2.1	0.25-0.6	35-67	80-100
PATIENT	4.53 kg	NM	0.67	1.22	0.6	25-30%	70
FELINE CARDIAC PARAMETERS	LA/AO (Boon)	LA/AO HEART BASE (Sisson)	LA 2D 4-chamber long axis AS to FW (Sisson) (cm)		LVOT VEL. (m/s)	RVOT VEL. (m/s)	IVRT (m/)
NORMAL PARAMETER	<1.5	0.88-1.79	0.7-1.7		<1.6	<1.3	40-60
PATIENT	2.5	>2.2	2.0			0.5	NM
Adapted from June Boon, Veterinary Echocardiography, 1998 Sisson D et al. JVIM 1991; 5: 232, Jacobs et al. Am J Vet Res 1985; 46:1705							

## ULTRASONOGRAPHIC FINDINGS

Consistent with unclassified cardiomyopathy with left and right sided failure.

Pleural and minor pericardial effusion.



## INTERPRETATION OF THE FINDINGS & FURTHER RECOMMENDATIONS

### PATIENT

Sunny Humphreys  
Drysdale

### SPECIES

Feline

### BREED

Domestic Shorthair

### SEX

Neutered male

### AGE

14 years

### WEIGHT

4.53 kg

### INTERPRETED BY

Eric Lindquist, DMV  
DABVP, Cert. IVUSS

### IMAGING PERFORMED BY

Dr. Varga

### HOSPITAL NAME

Shuswap VC

### REFERRING VET

Dr. Varga

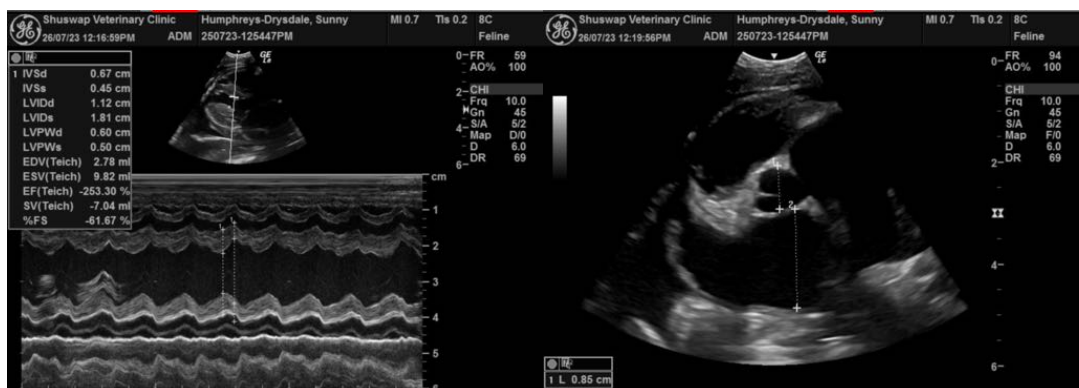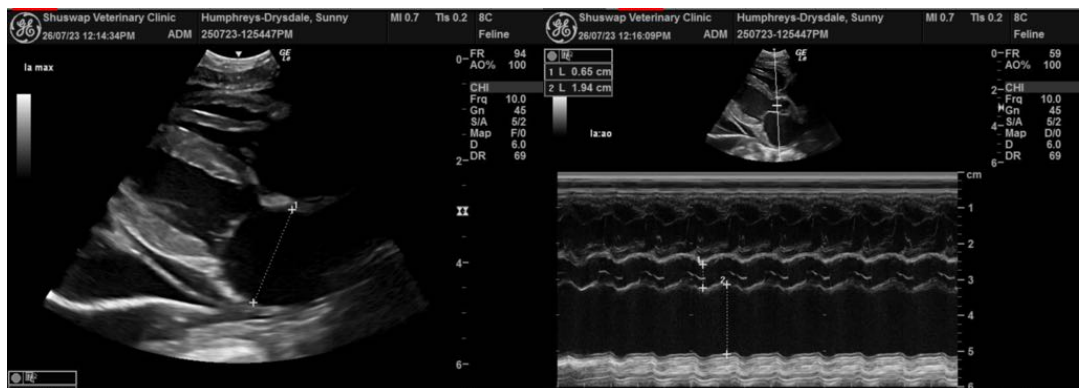
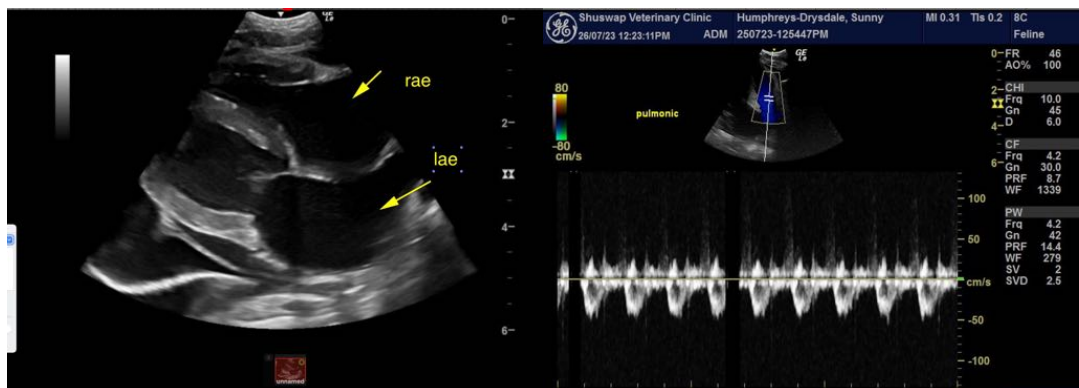
### INVOICE

76292

### DATE

7/27/23

No thrombosis is noted in this patient; however, a minor amount of smoke is present in this patient. I recommend Quadro therapy is recommended with Lasix 12.5 mg b.i.d. adjusting based on respiratory rate, radiographs and azotemia as well as hydration status. Pimobendan is indicated at 0.3 mg/kg b.i.d. along with Plavix. Eventual ace inhibitor therapy can be considered once the patient is out of crisis. Palliative pleurocentesis is indicated. Assessment for infectious agents and taurine levels should be considered. The prognosis is very guarded. Recheck echocardiogram is recommended if the patient is able to stabilize over the next 2 weeks for refinement of therapy. Blood pressure measurements and body temperature should be monitored. Oxygen therapy may be appropriate based on clinical status.





**PATIENT**

Sunny Humphreys  
Drysdale

**SPECIES**

Feline

**BREED**

Domestic Shorthair

**SEX**

Neutered male

**AGE**

14 years

**WEIGHT**

4.53 kg

**INTERPRETED BY**

Eric Lindquist, DMV  
DABVP, Cert. IVUSS

**IMAGING  
PERFORMED BY**

Dr. Varga

**HOSPITAL NAME**

Shuswap VC

**REFERRING VET**

Dr. Varga

**INVOICE**

76292

**DATE**

7/27/23

The information and recommendations provided are based on the images presented by the referring veterinarian/sonographer. No evaluation can be communicated regarding pathology that was not visible in the image/video clips provided.

Thank you for this referral. If the clinical or image interpretation does not parallel your findings or if I can be of any further assistance please contact me.

**Eric Lindquist**, DMV, DABVP, Cert. IVUSS, CEO of SonoPath.com  
info@SonoPath.com