



**PATIENT PRESENTING CLINICAL SIGNS**

Sadie Pavlicek

**SPECIES**

Feline

**BREED**

DSH

**SEX**

Spayed Female

**AGE**

13 Years 1 Month

**WEIGHT**

4.91

**INTERPRETED BY**

Eric Lindquist, DMV

DABVP, Cert. IVUSS

**IMAGING PERFORMED BY**

Dr. Jessie Evoniuk

**HOSPITAL NAME**

State Ave Vet Clinic

**REFERRING VET**

Dr. Jessie Evoniuk

**INVOICE**

44359

**DATE**

7/27/23

Hx of bladder stones/bladder infections- last issue was maybe a couple of months ago. Couldn't go before and was a slight stone and infection. Responded initially to medication First time to have an accident. Litterbox urination just once. Defecating in the litter box Last week or so P has been hiding Will come up to eat, not eating her dry food (z/d dry) but still eating the fancy feast Not drinking much Urinating outside of litter box which P has never done before Still defecating in litter box V/D- none Meds- prednisolone, only gives every so often, only given when P seems really itchy Using fine litter. Same litter no changes. Defecates in the box. No changes to style box. Cleaned regularly. Owner has been out of home more in the last 2 weeks, gone more from the home. Only cat in the home. Using the same spot in the bedroom- small spots. Fresh water in AM, bowl is still full- will paw it but rare to see her mouth in it. Likes fancy feast- chunky chicken and Z/D. Eats that well PE Notes: General Appearance: BAR, very active/vocal. BCS 5/9 CRT/MM: WNL Eyes: Corneas clear, pupils normal size, symmetrical, sclera white, no ocular discharge, periocular erythema and alopecia. Ears: No exudate observed, no redness present, mild hair thinning ear pinna Oral Cavity: Mod tarter/gingivitis; Grade 2 Nasal Cavity: No nasal drainage, nares WNL Cardiovascular: Regular rhythm; no murmur detected Respiratory: Lungs auscultate clear bilaterally; trachea clear Abdomen: Abdomen palpates normally; no pain, tenderness or masses on palpation Rectal: Did not perform rectal exam Musculoskeletal: Normal ambulation/no lameness reported Integument: Alopecia/erythema of the ventral abdomen, lateral thighs show some alopecia/hair thinning. Actively stopped to lick during her exam. Lymph Nodes: Lymph nodes normal in size Urogenital: External genitalia appears normal Neurologic: No apparent abnormalities noted Assessment Inappropriate urination- RO cystitis, uroliths, other. Noted fluid filled structure parallel to bladder structure. Cysto urine collection. Atopy- seemingly controlled with Z/D diet and pred PRN (unsure last dosage) Sr pet

Abnormal PE/Chem/CBC/UA Results: BUN: 32 \* mg/dL UA: Blood / Hemoglobin- 250 Ery/ $\mu$ L, Red Blood Cells >50 /HPF

**LIMITED ULTRASONOGRAPHIC EXAMINATION**

The region of the uterine stump revealed a dilated tubular structure measuring 1.45 cm x 3.1 cm, deviating the urinary bladder itself, which appeared normal. The pelvic urethra was unremarkable.

The left kidney revealed largely normal size and structure, corticomedullary definition and ratio (cortex 1/3 of medulla) were essentially maintained with some age-related loss of curvilinear patterns regarding the capsule and C/M junction. The cortex presented largely uniform texture with some increased echogenicity expected for his age patient. Medullary structure differed distinctly from that of the cortex and no evidence of pelvic dilation was present. The left kidney measured 3.6 cm.

**ULTRASONOGRAPHIC FINDINGS**

- Concern for stump pyometra or mucometra
- Structurally normal urinary bladder and left kidney

**INTERPRETATION OF THE FINDINGS & FURTHER RECOMMENDATIONS**

Full abdominal sonogram recommended. Only 14 images were submitted and evaluated.



**PATIENT**

Sadie Pavlicek

**SPECIES**

Feline

**BREED**

DSH

**SEX**

Spayed Female

**AGE**

13 Years 1 Month

**WEIGHT**

4.91

**INTERPRETED BY**

Eric Lindquist, DMV

DABVP, Cert. IVUSS

**IMAGING PERFORMED BY**

Dr. Jessie Evoniuk

**HOSPITAL NAME**

State Ave Vet Clinic

**REFERRING VET**

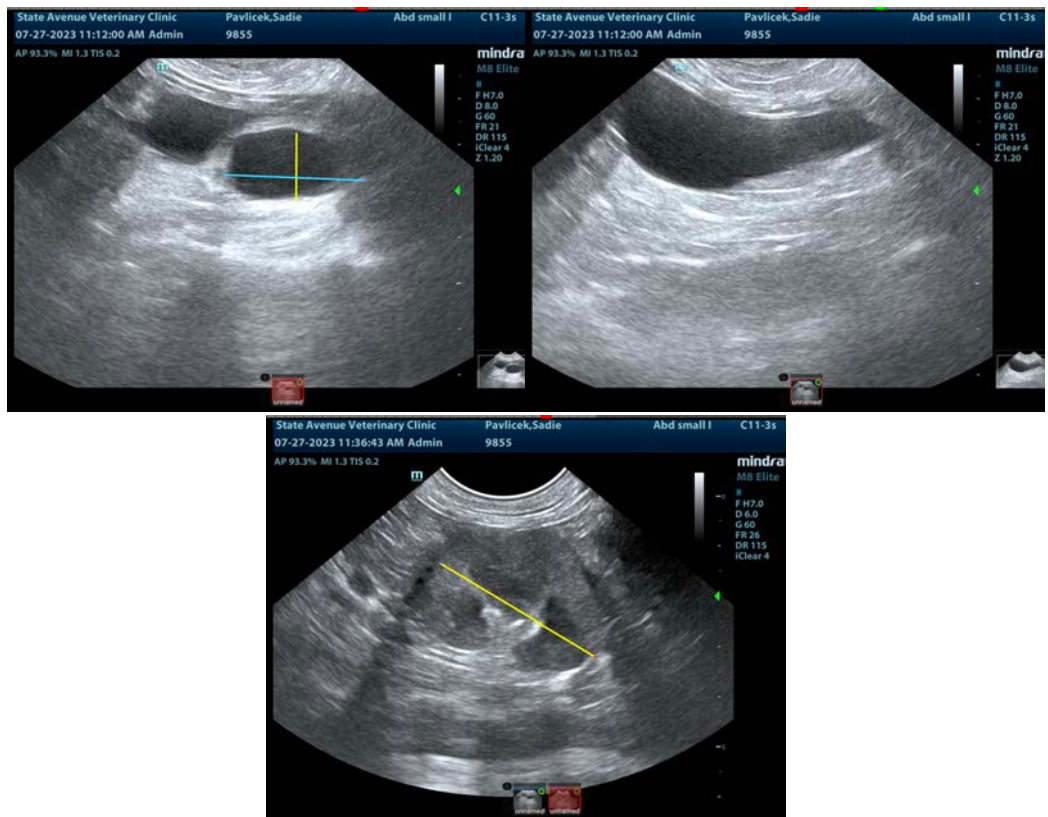
Dr. Jessie Evoniuk

**INVOICE**

44359

**DATE**

7/27/23



The information and recommendations provided are based on the images presented by the referring veterinarian/sonographer. No evaluation can be communicated regarding pathology that was not visible in the image/video clips provided.

Thank you for this referral. If the clinical or image interpretation does not parallel your findings or if I can be of any further assistance please contact me.

**Eric Lindquist, DMV, DABVP, Cert. IVUSS, CEO of SonoPath.com**

[info@SonoPath.com](mailto:info@SonoPath.com)