



PATIENT

Jax Ocampo

PRESENTING CLINICAL SIGNS

History: HGE black tarry stool ate a grape vomited once

SPECIES

Canine

ULTRASONOGRAPHIC EXAMINATION OF THE ABDOMEN

Urinary System

BREED

Jack Russell

The **urinary bladder** and visible pelvic urethra were unremarkable for the level of repletion presented. The urine, however, did present some mildly echogenic debris consistent with mucous, exfoliated cells from renal or bladder origin, and/or blood clots as these echogenic changes can all present similarly. This is often related to urinary tract infection but may represent simple evidence of exfoliated debris or sterile inflammation. Cystocentesis, urinalysis, +/- culture would be recommended to rule out and define any UTI.

SEX

Male

The **kidneys** revealed normal size and structure, corticomedullary definition and ratio for this age. The cortices presented largely uniform texture with normal echogenic relationship to liver and spleen. Medullary structure differed distinctly from the cortex and no evidence of pelvic dilation was present. The capsules were acceptably uniform without significant irregularities. The right kidney measured 4.04 cm. The left kidney measured 4.04 cm.

AGE

3 years

Adrenal Glands

WEIGHT

9.6 lbs

Both **adrenal glands** were visualized and recognized as having normal shape, size, position and echogenicity for this breed. The phrenic vasculature, glandular echogenicity and detail were unremarkable. Capsule, cortex, and medullary definition were normal for this age patient. The right adrenal gland measured 1.4 x 0.56 cm at the caudal and 0.83 cm at the cranial pole. The left adrenal gland measured 2.5 x 0.54 cm at the caudal pole and 0.52 cm at the cranial pole.

INTERPRETED BY

Eric Lindquist, DMV
DABVP, Cert. IVUSS

Spleen

IMAGING PERFORMED BY

Jenn

The **spleen** presented a smooth homogeneous parenchyma hyperechoic to liver and renal cortical parenchyma. The capsule was smooth without noticeable expansion or deviation from within the spleen or adjacent pathology. The splenic vasculature demonstrated normal volume without signs of congestion or thrombosis. No sonographic evidence of acute or chronic inflammatory, neoplastic, or infarctual changes was noted.

HOSPITAL NAME

Rockaway AH

Liver

REFERRING VET

Dr. Maniar

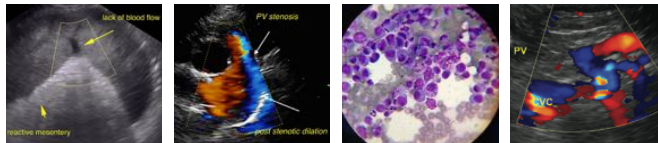
The **liver** images submitted revealed subjectively normal liver size, contour, and structure. Parenchymal echogenicity was naturally coarse and hypoechoic to the spleen. Vascular and biliary tracts were of normal volume with no evidence of congestion. The gallbladder presented acceptably thin walls with primarily anechoic content. The cystic and common bile ducts were normal. No pathological hepatic lymphadenopathy was evident. No overt structural evidence of inflammatory, infiltrative or regenerative pathology was evident.

INVOICE

76465

DATE

7/27/23



PATIENT

Jax Ocampo

SPECIES

Canine

BREED

Jack Russell

SEX

Male

AGE

3 years

WEIGHT

9.6 lbs

INTERPRETED BY

Eric Lindquist, DMV
DABVP, Cert. IVUSS

IMAGING PERFORMED BY

Jenn

HOSPITAL NAME

Rockaway AH

REFERRING VET

Dr. Maniar

INVOICE

76465

DATE

7/27/23

Gastrointestinal

Examination of the **gastrointestinal tract** revealed a stomach and intestine free of stasis, of normal wall thickness, acceptable curvilinear mural detail, and peristaltic activity. Small and large intestine demonstrated normal luminal chyme and stool consistency respectively. No obstructive or overt infiltrative disease was noted. No associated abnormal lymphatic activity was noted.

Pancreas

The base and limbs of the **pancreas** were observed to be largely isoechoic to surrounding omental fat. Pancreatic duct and capsular contour were acceptably normal and parenchyma respected normal curvilinear patterns. No overt evidence of active inflammatory or neoplastic disease was noted.

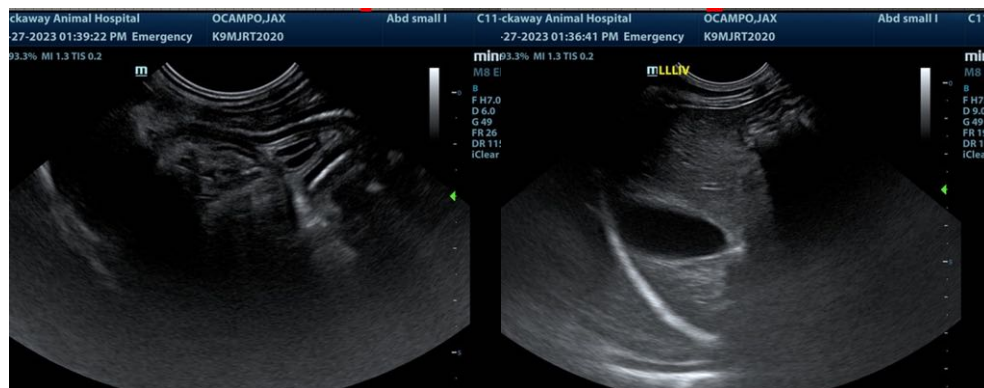
ULTRASONOGRAPHIC FINDINGS

Structurally unremarkable abdomen.

Bladder debris.

INTERPRETATION OF THE FINDINGS & FURTHER RECOMMENDATIONS

There was no evidence of pathology. Urinary work up is warranted if not already performed. Differentials for diarrhea include occult parasitism. Dietary indiscretion, dietary intolerance, antibiotic responsive colitis, intestinal dysbiosis and occult Addison's should all be considered as causes of diarrhea in this patient. A hydrolyzed diet trial may be in this patient's best interest +/- probiotics. 24-hour NPO and reintroduction of bland diet indicated. I recommend a baseline cortisol or ACTH stimulation test, a fresh fecal smear and fecal floatation analysis if not already performed.





PATIENT

Jax Ocampo

SPECIES

Canine

BREED

Jack Russell

SEX

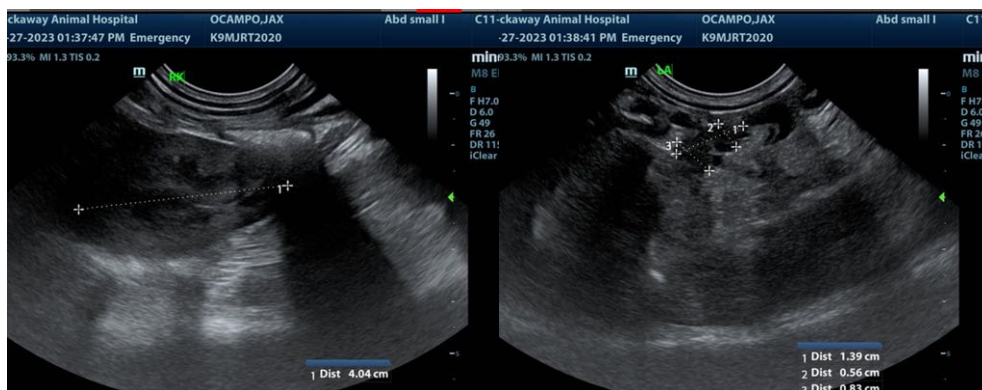
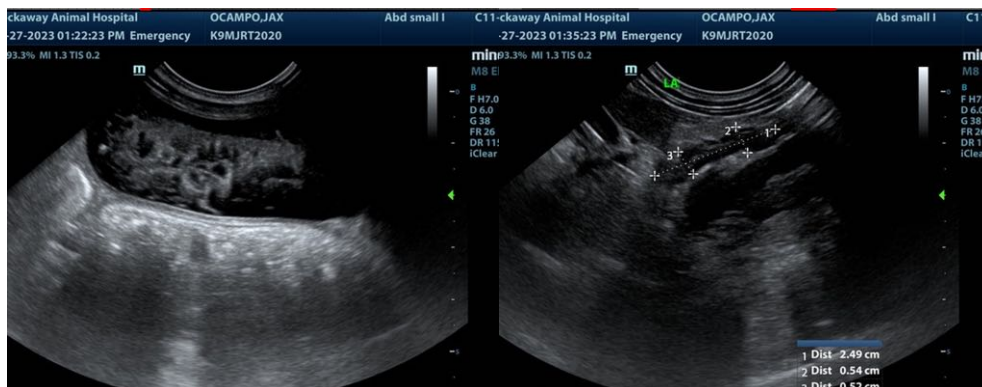
Male

AGE

3 years

WEIGHT

9.6 lbs



INTERPRETED BY

Eric Lindquist, DMV
DABVP, Cert. IVUSS

IMAGING PERFORMED BY

Jenn

HOSPITAL NAME

Rockaway AH

REFERRING VET

Dr. Maniar

INVOICE

76465

DATE

7/27/23

The information and recommendations provided are based on the images presented by the referring veterinarian/sonographer. No evaluation can be communicated regarding pathology that was not visible in the image/video clips provided.

Thank you for this referral. If the clinical or image interpretation does not parallel your findings or if I can be of any further assistance please contact me.

Eric Lindquist, DMV, DABVP, Cert. IVUSS, CEO of SonoPath.com
info@SonoPath.com