

**PATIENT**

Hyla Winckhofer

**PRESENTING CLINICAL SIGNS**

History: recheck adrenal glands 3/29 adrenal glands small bilateral

**SPECIES**

Canine

**ULTRASONOGRAPHIC EXAMINATION OF THE ABDOMEN**

**Urinary System**

**BREED**

Labrador Mix

The **urinary bladder**, trigone, and pelvic urethra presented normal thicknesses and normal tone. A minimal amount of urine was noted at the time of the sonogram. The ureters were not visible which is normal. No uroliths or sediment were visualized and anechoic urine was present. No evidence of inflammatory or neoplastic changes was noted. Ureteral papillae were normal.

**SEX**

Spayed female

The **kidneys** revealed normal size and structure, corticomedullary definition and ratio for this age. The cortices presented largely uniform texture with normal echogenic relationship to liver and spleen. Medullary structure differed distinctly from the cortex and no evidence of pelvic dilation was present. The capsules were acceptably uniform without significant irregularities. The right kidney measured 5.63 cm. The left kidney measured 6.33 cm.

**AGE**

1 year

**Adrenal Glands**

**WEIGHT**

46 lbs

The right adrenal gland was flattened and technically normal in size at 2.5 x 1.06 cm at the cranial pole and 0.58 cm at the caudal pole. The left adrenal gland was subjectively flattened and low normal in size for this breed measuring 1.77 x 0.33 cm at the caudal pole and 0.37 cm at the cranial pole.

**INTERPRETED BY**

Eric Lindquist, DMV  
DABVP, Cert. IVUSS

**Spleen**

**IMAGING PERFORMED BY**

Jenn

The **spleen** presented a smooth homogeneous parenchyma hyperechoic to liver and renal cortical parenchyma. The capsule was smooth without noticeable expansion or deviation from within the spleen or adjacent pathology. The splenic vasculature demonstrated normal volume without signs of congestion or thrombosis. No sonographic evidence of acute or chronic inflammatory, neoplastic, or infarctual changes was noted.

**HOSPITAL NAME**

Rockaway AH

**Liver**

**REFERRING VET**

Dr. Bednar

The **liver** images submitted revealed subjectively normal liver size, contour, and structure. Parenchymal echogenicity was naturally coarse and hypoechoic to the spleen. Vascular and biliary tracts were of normal volume with no evidence of congestion. The gallbladder presented acceptably thin walls with primarily anechoic content. The cystic and common bile ducts were normal. No pathological hepatic lymphadenopathy was evident. No overt structural evidence of inflammatory, infiltrative or regenerative pathology was evident.

**INVOICE**

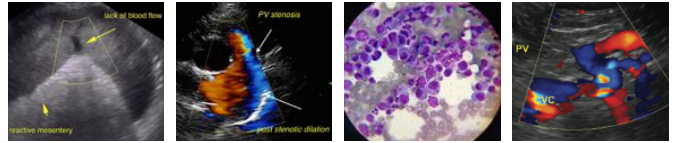
76264

**Gastrointestinal**

**DATE**

7/27/23

Examination of the **gastrointestinal tract** revealed a stomach and intestine free of stasis, of normal wall thickness, acceptable curvilinear mural detail, and peristaltic activity. Small and large intestine



**PATIENT**

Hyla Winckhofer

demonstrated normal luminal chyme and stool consistency respectively. No obstructive or overt infiltrative disease was noted. No associated abnormal lymphatic activity was noted.

**SPECIES**

Canine

**Pancreas**

The base and limbs of the **pancreas** were observed to be largely isoechoic to surrounding omental fat. Pancreatic duct and capsular contour were acceptably normal and parenchyma respected normal curvilinear patterns. No overt evidence of active inflammatory or neoplastic disease was noted.

**BREED**

Labrador Mix

**ULTRASONOGRAPHIC FINDINGS**

Structurally normal abdomen.

**SEX**

Spayed female

**INTERPRETATION OF THE FINDINGS & FURTHER RECOMMENDATIONS**

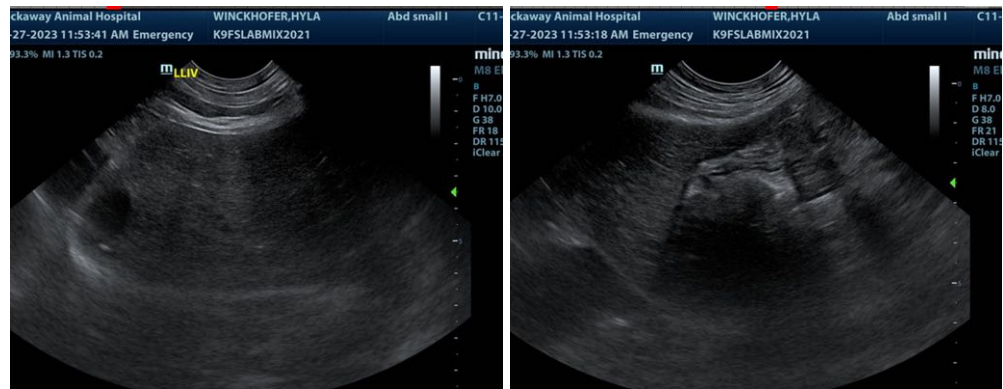
**AGE**

1 year

If any clinical signs of Addison's is present such as unexplained lethargy, exercise intolerance, GI signs then full ACTH stimulation is warranted especially if the baseline cortisol is less than 2.0.

**WEIGHT**

46 lbs

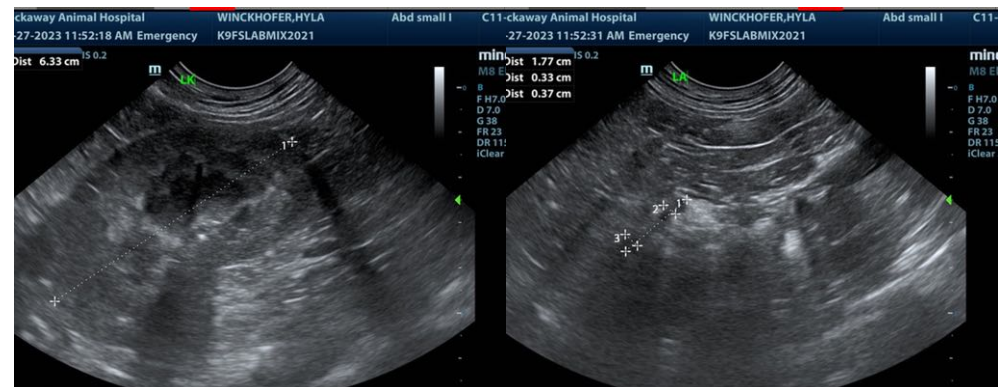


**INTERPRETED BY**

Eric Lindquist, DMV  
DABVP, Cert. IVUSS

**IMAGING PERFORMED BY**

Jenn



**HOSPITAL NAME**

Rockaway AH

**REFERRING VET**

Dr. Bednar

**INVOICE**

76264

**DATE**

7/27/23



**PATIENT**

Hyla Winckhofer

**SPECIES**

Canine

**BREED**

Labrador Mix

**SEX**

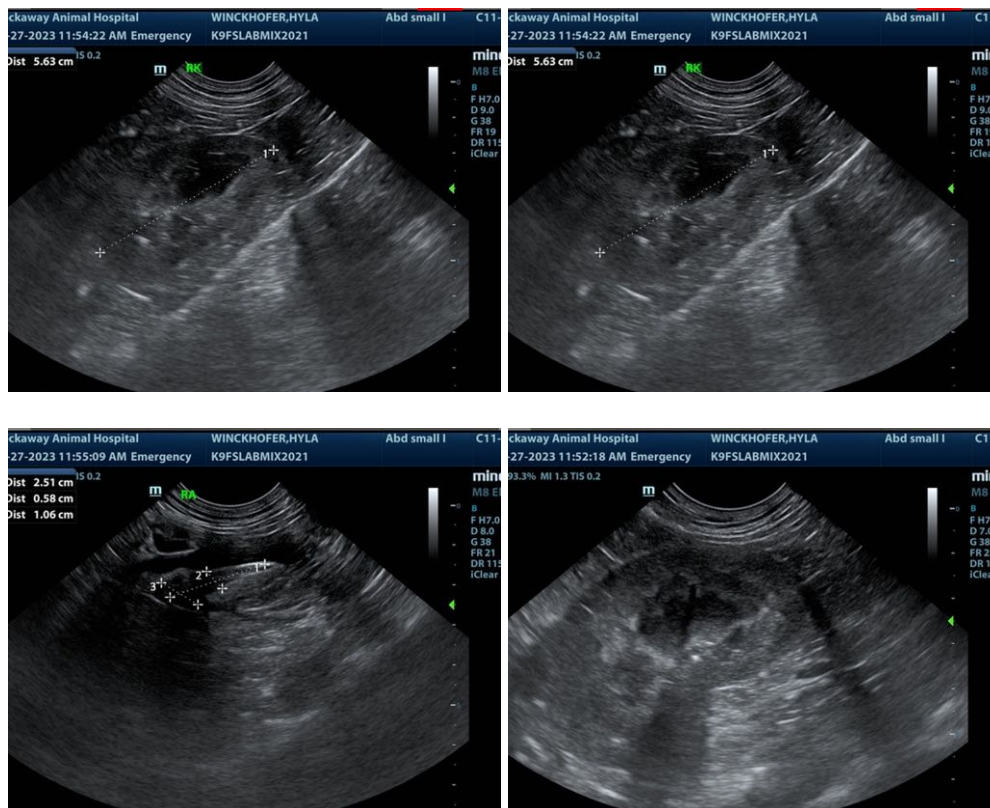
Spayed female

**AGE**

1 year

**WEIGHT**

46 lbs



**INTERPRETED BY**

Eric Lindquist, DMV  
DABVP, Cert. IVUSS

**IMAGING PERFORMED BY**

Jenn

**HOSPITAL NAME**

Rockaway AH

**REFERRING VET**

Dr. Bednar

**INVOICE**

76264

**DATE**

7/27/23

The information and recommendations provided are based on the images presented by the referring veterinarian/sonographer. No evaluation can be communicated regarding pathology that was not visible in the image/video clips provided.

Thank you for this referral. If the clinical or image interpretation does not parallel your findings or if I can be of any further assistance please contact me.

**Eric Lindquist, DMV, DABVP, Cert. IVUSS, CEO of SonoPath.com**  
info@SonoPath.com