



**PATIENT PRESENTING CLINICAL SIGNS**

Chance Doyle FB sx at another vet in May, for impaled piece of wood left chest area. Abscess formed, was treated. Still ADR, inappetence for the last couple of days, hx of fever but normal today. Onsior 7/25 and convenia injection 7/22

**SPECIES**

Feline

**ULTRASONOGRAPHIC EXAMINATION OF THE ABDOMEN**

**BREED**

DSH

**Urinary System**

The **urinary bladder**, trigone, and pelvic urethra presented normal thicknesses and normal tone. The ureters were not visible which is normal. No uroliths or sediment were visualized and anechoic urine was present. No evidence of inflammatory or neoplastic changes were noted. Ureteral papillae were normal. The pelvic urethra was imaged 2.0 cm beyond the cystourethral junction.

**SEX**

Neutered Male

The **kidneys** revealed largely normal size and structure, corticomedullary definition and ratio (cortex 1/3 of medulla) were essentially maintained with some age-related loss of curvilinear patterns regarding the capsule and C/M junction. The cortices presented largely uniform texture with some increased echogenicity expected for his age patient. Medullary structure differed distinctly from that of the cortex and no evidence of pelvic dilation was present. The left kidney measured 4.18 cm. The right kidney measured 4.8 cm.

**AGE**

11 Years

**WEIGHT**

15.2 Pounds

**Adrenal Glands**

Both **adrenal glands** were visualized and recognized as having normal shape, size, position and echogenicity for this breed. The phrenic vasculature, glandular echogenicity and detail were unremarkable. Capsule, cortex, and medullary definition were normal for this age patient. The right adrenal gland measured 0.36 cm. The left adrenal gland measured 0.42 cm.

**INTERPRETED BY**

Eric Lindquist, DMV

DABVP, Cert. IVUSS

**Spleen**

The **spleen** presented a smooth homogeneous parenchyma hyperechoic to liver and renal cortical parenchyma. The capsule was smooth without noticeable expansion or deviation from within the spleen or adjacent pathology. The splenic vasculature demonstrated normal volume without signs of congestion or thrombosis. No sonographic evidence of acute or chronic inflammatory, neoplastic, or infarctual changes were noted.

**IMAGING PERFORMED BY**

Diane McFadden

**HOSPITAL NAME**

ACC Landing

**Liver**

The area of the left **liver** revealed mixed echogenic body wall granulomatous type changes with cellulitis pattern. It appears to occupy the entire body wall. The hypoechoic portions of the subcutaneous area are concerning and are surrounded by hyperechoic inflamed fat. This extends for approximately 2.0 cm deep x at least 6.0 cm in length. There is one tubular area creating a fistula in the deeper area approximately 2.0-3.0 cm yet does not appear to invade the body wall.

**REFERRING VET**

Dr. Wegley

**INVOICE**

44358

**Gastrointestinal**

**DATE**

7/27/23

The **stomach** was filled with progressively shadowing material such as hairball accumulation, which may be contributing to the anorexia. The small intestine and colon were unremarkable.



**PATIENT** *Pancreas*

Chance Doyle

The base and limbs of the **pancreas** were observed to be largely isoechoic to surrounding omental fat. Pancreatic duct and capsular contour were acceptably normal and parenchyma respected normal curvilinear patterns. No overt evidence of active inflammatory or neoplastic disease was noted.

**SPECIES**

Feline

**ULTRASONOGRAPHIC FINDINGS**

**BREED**

DSH

- Fistulating cellulitis pattern with potential underlying neoplasia
- Hairball density in the stomach
- Age related renal changes

**SEX**

Neutered Male

**INTERPRETATION OF THE FINDINGS & FURTHER RECOMMENDATIONS**

FNA, cytology and culture indicated. CT with contrast strongly recommended for potential surgical planning, yet cytology and culture indicated to ensure an underlying neoplastic event is not playing a role. Hairball therapy warranted, yet further diagnostics necessary regarding the cellulitis/body wall granulomatous type change to ensure this is not a neoplastic event. No overt foreign body noted, yet a broken-up portion of wood chip cannot be completely ruled out. Aerobic and anaerobic culture indicated.

**WEIGHT**

15.2 Pounds

**INTERPRETED BY**

Eric Lindquist, DMV

DABVP, Cert. IVUSS

**IMAGING PERFORMED BY**

Diane McFadden

**HOSPITAL NAME**

ACC Landing

**REFERRING VET**

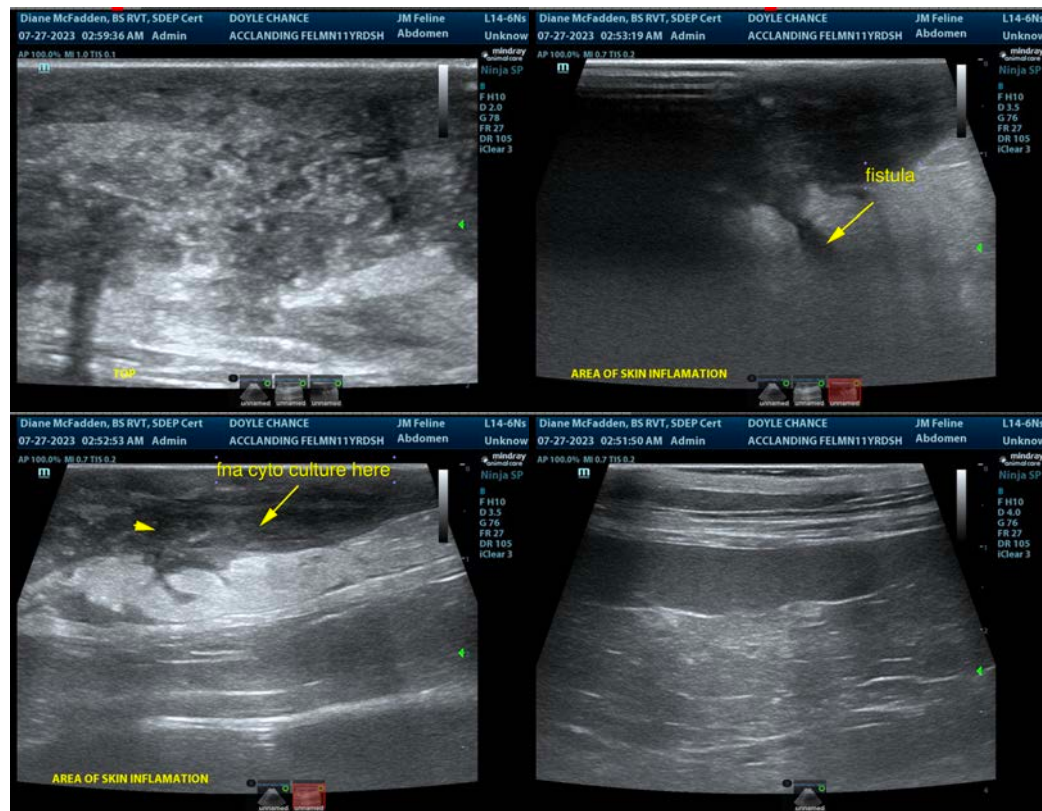
Dr. Wegley

**INVOICE**

44358

**DATE**

7/27/23





**PATIENT**

Chance Doyle

**SPECIES**

Feline

**BREED**

DSH

**SEX**

Neutered Male

**AGE**

11 Years

**WEIGHT**

15.2 Pounds

**INTERPRETED BY**

Eric Lindquist, DMV

DABVP, Cert. IVUSS

**IMAGING PERFORMED BY**

Diane McFadden

**HOSPITAL NAME**

ACC Landing

**REFERRING VET**

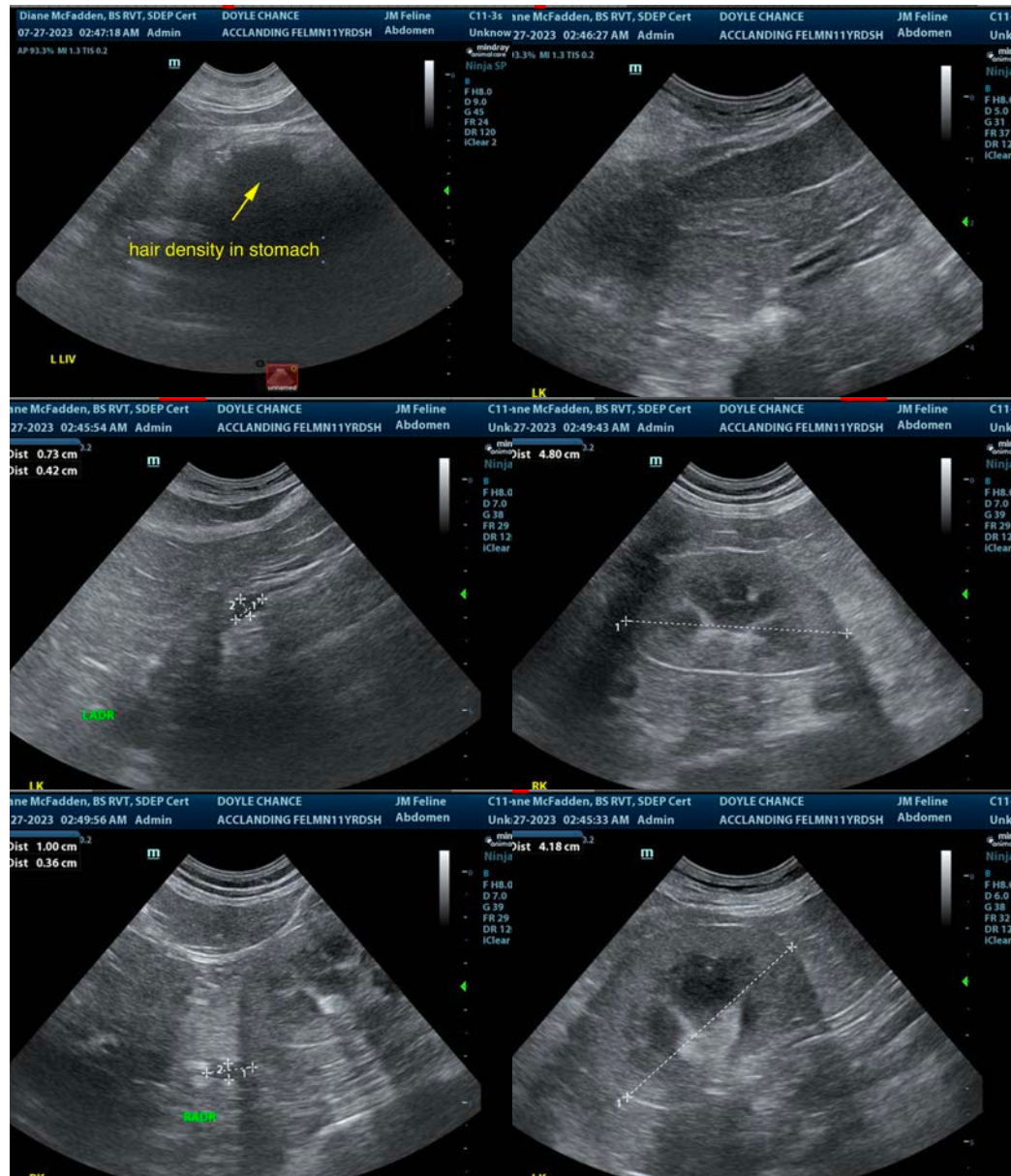
Dr. Wegley

**INVOICE**

44358

**DATE**

7/27/23



The information and recommendations provided are based on the images presented by the referring veterinarian/sonographer. No evaluation can be communicated regarding pathology that was not visible in the image/video clips provided.

Thank you for this referral. If the clinical or image interpretation does not parallel your findings or if I can be of any further assistance please contact me.

**Eric Lindquist, DMV, DABVP, Cert. IVUSS, CEO of SonoPath.com**

[info@SonoPath.com](mailto:info@SonoPath.com)