



PATIENT

Ziggy Lamorte

PRESENTING CLINICAL SIGNS

Follow up echo, last one performed 12/10/2021. Diagnosed with Stage B2 valvular disease. 1/5/22 Grade 2/6 heart murmur - no symptoms. Current meds: Vetmedin 5 mgs BID. BP today: 144/73.

SPECIES

Canine

ULTRASONOGRAPHIC EXAMINATION OF THE HEART

BREED

Beagle X

SEX

Spayed Female

AGE

9 Years

WEIGHT

40 Pounds

CANINE CARDIAC PARAMETERS	MR VMAX (m/s)	TR VMAX (m/s)	LA/AO (Boon method)	LA/AO (Heart Base; Swe)	FS (%)	EF (%)	EPSS (cm)
NORMAL PARAMETER	4.5-5.5	<2.7	1.3	<1.6	28-40	40-100	<0.6
PATIENT	6.0		NM	1.3	27	53	0.1
CANINE CARDIAC PARAMETERS	HR (BPM)	AV VMAX (m/s)	PV MAX (m/s)	BODY WEIGHT (kg)	LA 2D short axis Base view (cm)	LVIDd Avg; 2D and m-mode short axis (cm)	LVIDs Avg; 2D and m-mode short axis (cm)
NORMAL PARAMETER	50-100	0.7-1.7	0.7-1.6	BELOW	BELOW	BELOW	BELOW
PATIENT	93	2.0	1.21		4.9	3.91	

Cardiac Presentation

The cardiac presentation revealed persistent mitral and tricuspid insufficiency with mild left atrial enlargement and complete filling of the left atrium noted. Tricuspid insufficiency noted at 2.5 m/sec. Contractility appeared adequate. Left ventricular internal diameter was mildly excessive. The right atrium, right ventricle and pulmonary artery were unremarkable. No pleural or pericardial effusion noted.

INTERPRETED BY

Eric Lindquist, DMV
DABVP, Cert. IVUSS

ULTRASONOGRAPHIC FINDINGS

- Persistent mitral insufficiency with mild left atrial enlargement

IMAGING PERFORMED BY

Kelly Vazquez

INTERPRETATION OF THE FINDINGS & FURTHER RECOMMENDATIONS

There may be some value to adding ACE inhibitor at 0.5 mg/kg SID progressing to BID and Spironolactone 1-2 mg/kg BID, given the mild persistent chronic left atrial enlargement. However, it is debatable on this implementation and approach without consensus. Recheck echo in 6 months if the patient is stable, earlier if murmur grade increases or clinical signs initiate.

HOSPITAL NAME

Northvale Vet Clinic

REFERRING VET

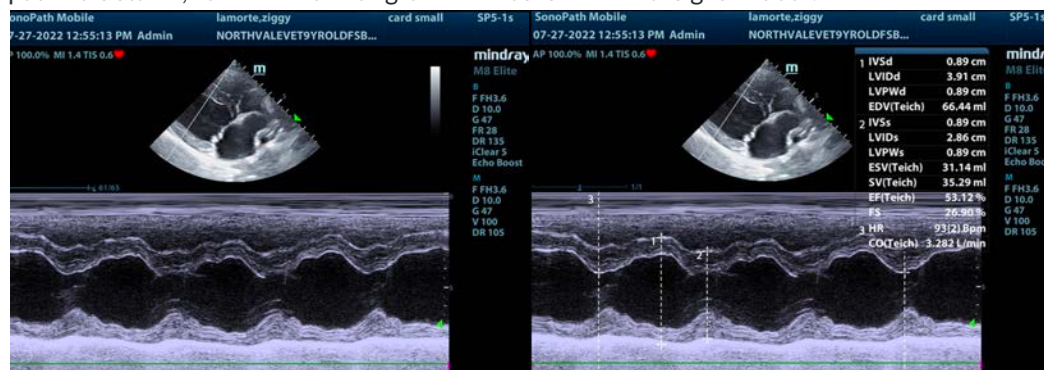
Dr. Stefanie Simon

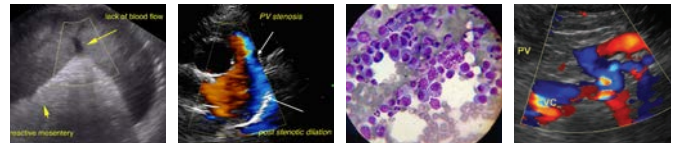
INVOICE

39880

DATE

7/27/22





PATIENT

Ziggy Lamorte

SPECIES

Canine

BREED

Beagle X

SEX

Spayed Female

AGE

9 Years

WEIGHT

40 Pounds

INTERPRETED BY

Eric Lindquist, DMV

DABVP, Cert. IVUSS

IMAGING PERFORMED BY

Kelly Vazquez

HOSPITAL NAME

Northvale Vet Clinic

REFERRING VET

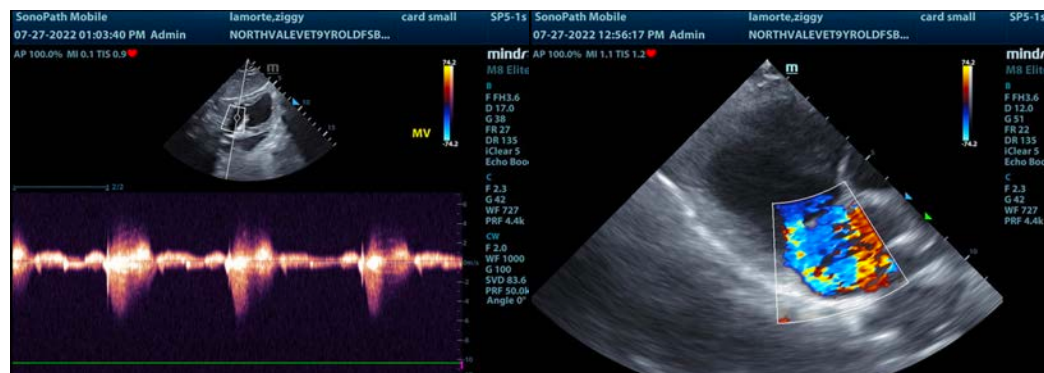
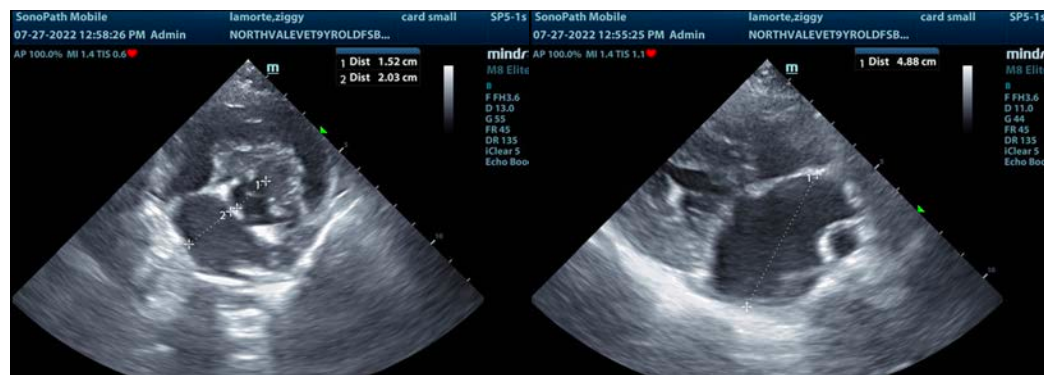
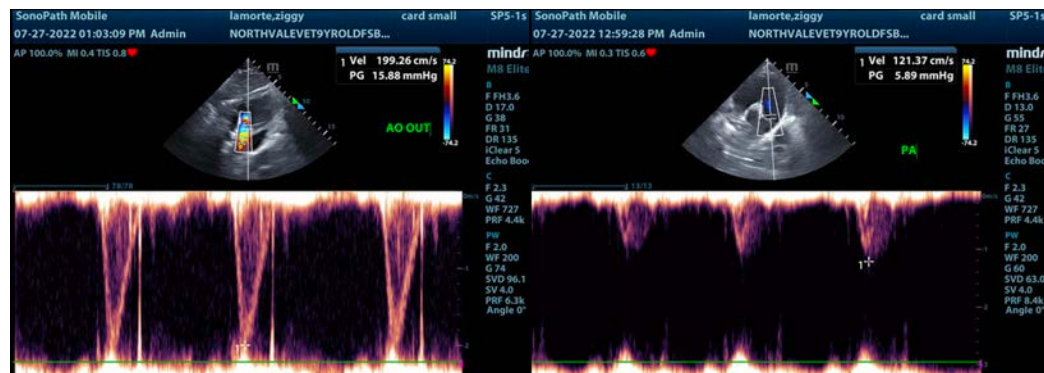Dr. Stefanie Simon

INVOICE

39880

DATE

7/27/22



The information and recommendations provided are based on the images presented by the referring veterinarian/sonographer. No evaluation can be communicated regarding pathology that was not visible in the image/video clips provided.

Thank you for this referral. If the clinical or image interpretation does not parallel your findings or if I can be of any further assistance please contact me.

Eric Lindquist, DMV, DABVP, Cert. IVUSS, CEO of SonoPath.com

info@SonoPath.com