



PATIENT PRESENTING CLINICAL SIGNS

Tamika Franken

History: Tamika had screening thoracic x-rays taken at the orthopedic surgeons as a screen before Cranial Cruciate Surgery. They had concern for tracheal deviation potentially signaling a heart issue. She is normal otherwise.

SPECIES

Abnormal PE/Chem/CBC/UA Results: PE: Stage I dental disease, Left stifle effusion and medial buttress. Remainder WNL. No recent labs done.

Canine

BREED ULTRASONOGRAPHIC EXAMINATION OF THE HEART

Blue Heeler Mix

The echocardiogram in this patient demonstrated normal **left atrial** size based on 3 separate methods of LA evaluation. The cranial and caudal **mitral** valve leaflets presented normal linear structure, extension in systole, and union in diastole with normal kinesis. The **left ventricle** presented thicknesses with linear contour and was not dilated nor restricted. The **myocardium** presented normal echogenicity without subjective evidence of significant fibrotic or ischemic disease. **Contractility** of the ventricular walls was adequate and in normal range for this patient evidenced by the fractional shortening measurement and subjective evaluation of the different regions of the myocardium. The **left ventricular outflow** tract demonstrated normal laminar flow and subjective structural integrity. The **right atrium** and auricle revealed normal size, structure and content. No evidence of masses was noted. **Tricuspid** valvular assessment demonstrated adequate linear morphology and kinesis. The **right ventricle** was of normal size (1/3 diameter of LV), chordae structure, myocardial echogenicity and thickness. Trivial **pulmonic** insufficiency was noted. No visible **pericardial** or free pleura fluid was noted. The cranial **mediastinum and pericardial and extra-cardiac regions** were free of masses in the visible window.

SEX

Spayed female

AGE

12 years

WEIGHT

31 lbs

INTERPRETED BY

Eric Lindquist, DMV
DABVP, Cert. IVUSS

IMAGING PERFORMED BY

Dr. Anderson

HOSPITAL NAME

Elizabeth AH

REFERRING VET

Dr. Anderson

CANINE CARDIAC PARAMETERS	MR VMAX (m/s)	TR VMAX (m/s)	LA/AO (Boon method)	LA/AO (Heart Base; Swe)	FS (%)	EF (%)	EPSS (cm)
NORMAL PARAMETER	4.5-5.5	<2.7	1.3	<1.6	28-40	40-100	<0.6
PATIENT			1.37	1.15	32	61	0.2
CANINE CARDIAC PARAMETERS	HR (BPM)	AV VMAX (m/s)	PV MAX (m/s)	BODY WEIGHT	LA (2D short axis Base view) (cm)	LVIDd (Avg; 2D and m-mode short axis) (cm)	LVIDs (Avg; 2D and m-mode short axis) (cm)
NORMAL PARAMETER	50-100	0.7-1.7	0.7-1.6	BELOW	BELOW	BELOW	BELOW
PATIENT		1.96	0.85	31 lbs	3.37	3.34	

INVOICE

32025

DATE

7/27/22

ULTRASONOGRAPHIC FINDINGS

Essentially normal echocardiogram.



PATIENT

Tamika Franken

INTERPRETATION OF THE FINDINGS & FURTHER RECOMMENDATIONS

There is no contraindication to anesthetic procedure. Normal volumes, function and structure.

SPECIES

Canine

BREED

Blue Heeler Mix

SEX

Spayed female

AGE

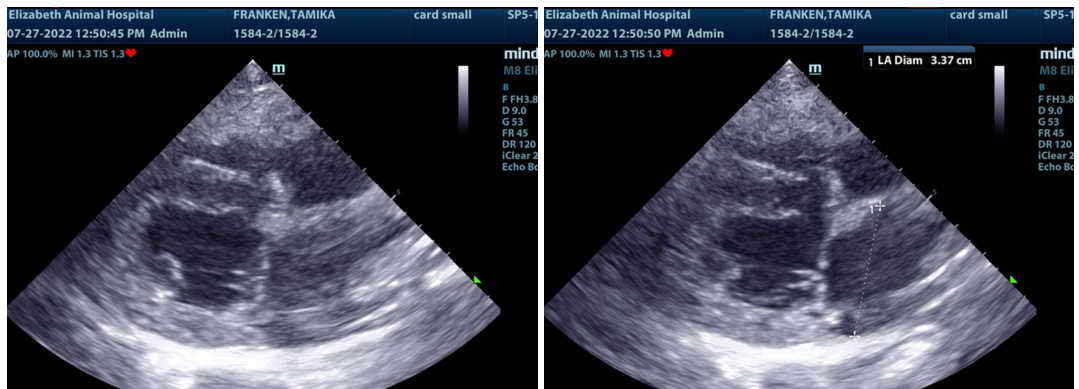
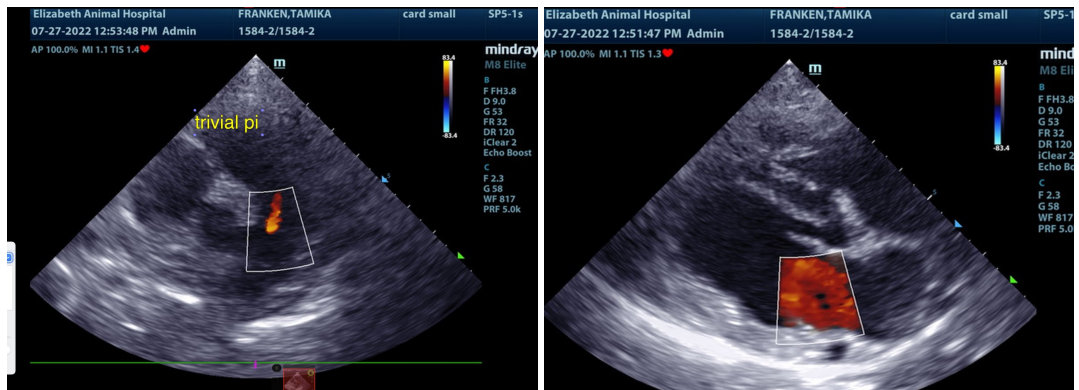
12 years

WEIGHT

31 lbs

INTERPRETED BY

Eric Lindquist, DMV
DABVP, Cert. IVUSS



IMAGING PERFORMED BY

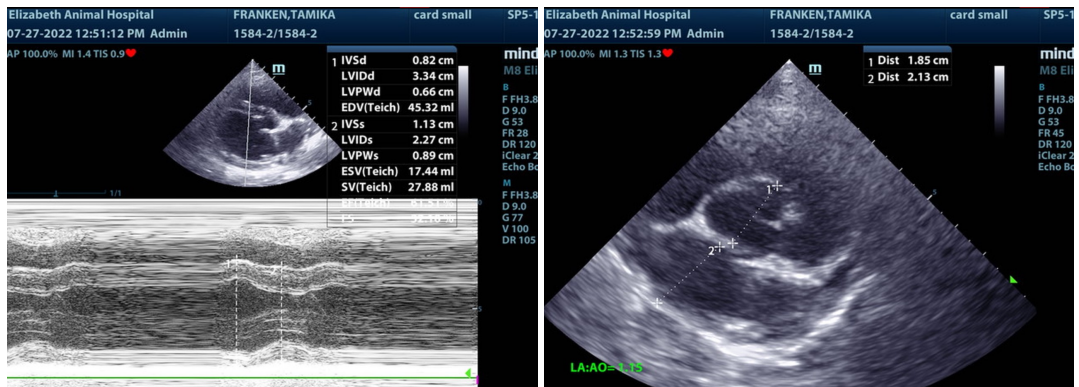
Dr. Anderson

HOSPITAL NAME

Elizabeth AH

REFERRING VET

Dr. Anderson



INVOICE

32025

DATE

7/27/22



PATIENT

Tamika Franken

SPECIES

Canine

BREED

Blue Heeler Mix

SEX

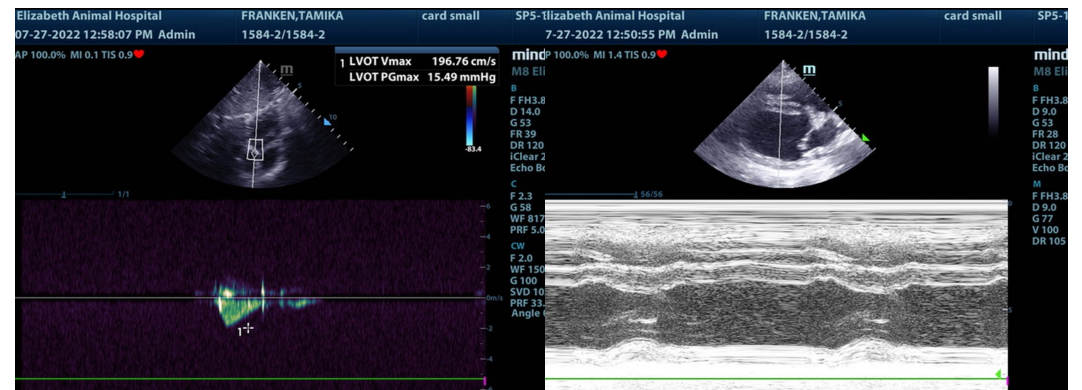
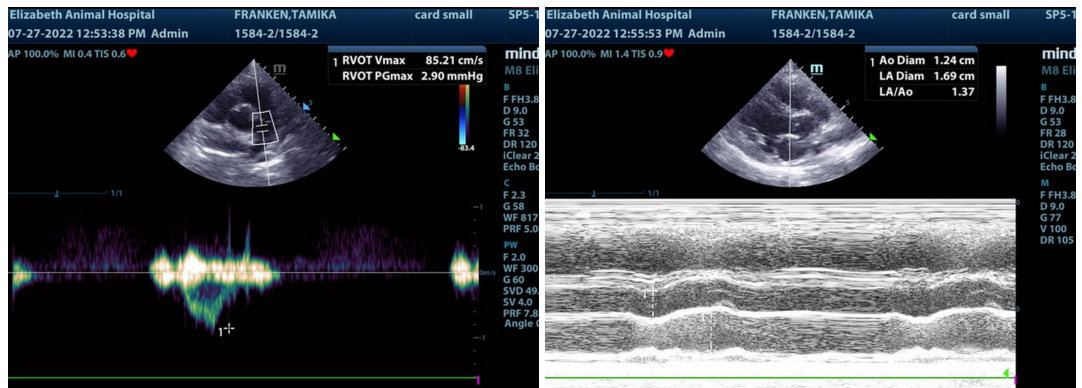
Spayed female

AGE

12 years

WEIGHT

31 lbs



INTERPRETED BY

Eric Lindquist, DMV
DABVP, Cert. IVUSS

IMAGING PERFORMED BY

Dr. Anderson

HOSPITAL NAME

Elizabeth AH

REFERRING VET

Dr. Anderson

INVOICE

32025

DATE

7/27/22

The information and recommendations provided are based on the images presented by the referring veterinarian/sonographer. No evaluation can be communicated regarding pathology that was not visible in the image/video clips provided.

Thank you for this referral. If the clinical or image interpretation does not parallel your findings or if I can be of any further assistance please contact me.

Eric Lindquist, DMV, DABVP, Cert. IVUSS, CEO of SonoPath.com
info@SonoPath.com