

PATIENT PRESENTING CLINICAL SIGNS

Sylar Cardwell Grade two periodontal disease Grade IV/VI systolic murmur. RR- panting 3 mm raised, pink, alopecic mass on left lateral flank Current Medications phycox small bites

SPECIES ULTRASONOGRAPHIC EXAMINATION OF THE HEART

Canine

BREED

Pomeranian X

SEX

Neutered Male

AGE

11 Years

WEIGHT

11.12 Pounds

INTERPRETED BY

Eric Lindquist, DMV

DABVP, Cert. IVUSS

IMAGING PERFORMED BY

Jenna Walsh, CVT

HOSPITAL NAME

Pleasant Hill AH

REFERRING VET

Dr. Supan

INVOICE

39899

DATE

7/27/22

CANINE CARDIAC PARAMETERS	MR VMAX (m/s)	TR VMAX (m/s)	LA/AO (Boon method)	LA/AO (Heart Base; Swe)	FS (%)	EF (%)	EPSS (cm)
NORMAL PARAMETER	4.5-5.5	<2.7	1.3	<1.6	28-40	40-100	<0.6
PATIENT	6.2	3.0	1.3	1.3	45	90	NM
CANINE CARDIAC PARAMETERS	HR (BPM)	AV VMAX (m/s)	PV MAX (m/s)	BODY WEIGHT (kg)	LA 2D short axis Base view (cm)	LVIDd Avg; 2D and m-mode short axis (cm)	LVIDs Avg; 2D and m-mode short axis (cm)
NORMAL PARAMETER	50-100	0.7-1.7	0.7-1.6	BELOW	BELOW	BELOW	BELOW
PATIENT	110	1.2	1.2		2.76	2.1	

Cardiac Presentation

The echocardiogram in this patient demonstrated normal **left atrial** size based on 3 different LA measurement methods. Chamber volumes and echogenicity were normal. The cranial and caudal **mitral** valve leaflets presented vegetative thickening consistent with endocardiosis. Doppler indicated measurable insufficiency. The **left ventricle** presented thicknesses with linear contour and was not dilated nor restricted. The **myocardium** presented normal echogenicity without subjective evidence of significant fibrotic or ischemic disease. **Contractility** of the ventricular walls was adequate and in normal range for this patient evidenced by the fractional shortening measurement and subjective evaluation of the different regions of the myocardium. The **left ventricular outflow** tract demonstrated normal laminar flow and subjective structural integrity. The **right atrium** and auricle revealed normal size, structure and content. No evidence of masses was noted or chamber overload. **Tricuspid** insufficiency noted. The **right ventricle** was of normal size (1/3 diameter of LV), chordae structure, myocardial echogenicity and thickness. **Pulmonic** tract assessment revealed normal valve structure, laminar flow, and diameter (approx. 1:1 pa/ao ratio). No visible **pericardial** or free pleura fluid was noted. No echographically detectable evidence of infiltrative disease was visible. The cranial **mediastinum** and **pericardial** regions were free of masses in the visible window. Hepatic veins were not dilated.

ULTRASONOGRAPHIC FINDINGS

- Mitral and tricuspid insufficiency, Stage B1 valvular disease
- Mild pulmonary hypertension, compensated at this time



PATIENT

Sylar Cardwell

SPECIES

Canine

BREED

Pomeranian X

SEX

Neutered Male

AGE

11 Years

WEIGHT

11.12 Pounds

INTERPRETED BY

Eric Lindquist, DMV
DABVP, Cert. IVUSS

IMAGING PERFORMED BY

Jenna Walsh, CVT

HOSPITAL NAME

Pleasant Hill AH

REFERRING VET

Dr. Supan

INVOICE

39899

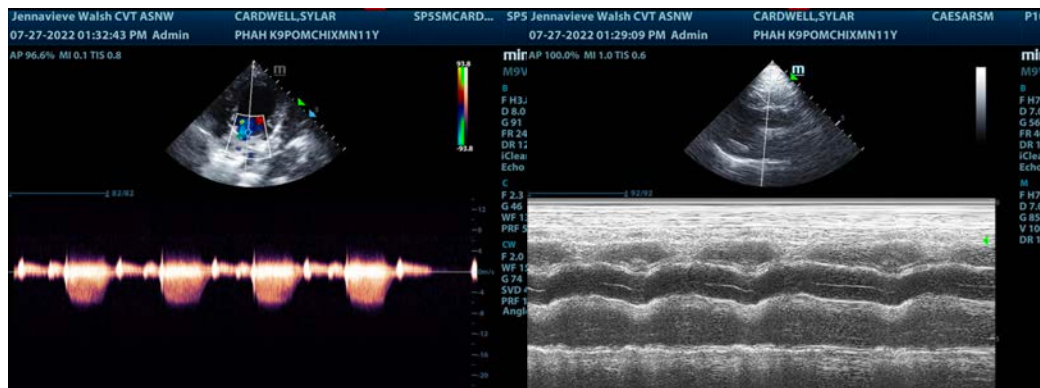
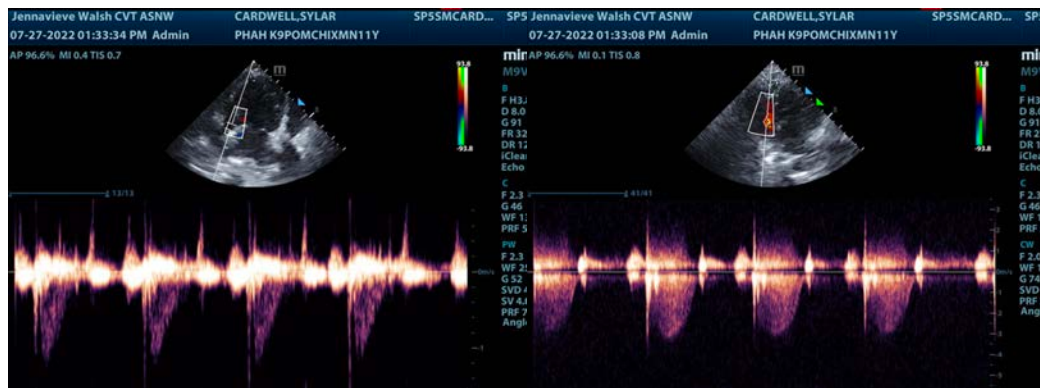
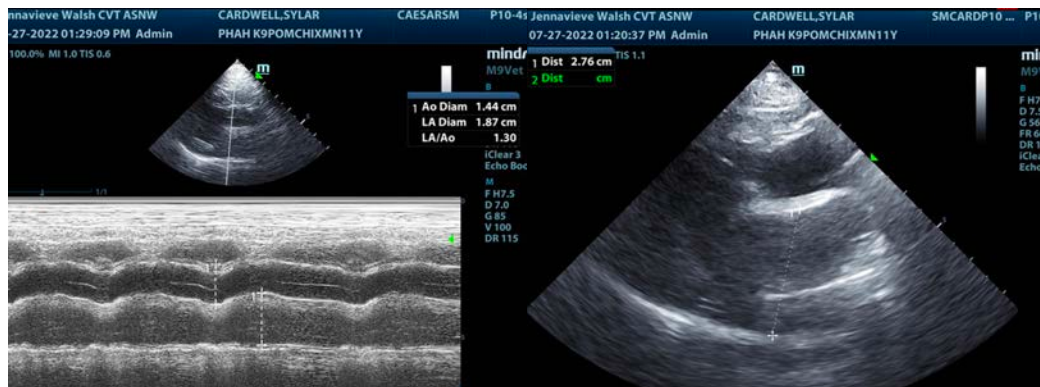
DATE

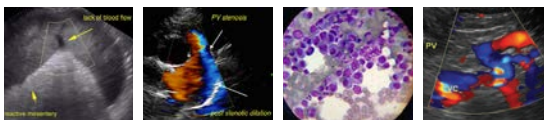
7/27/22

INTERPRETATION OF THE FINDINGS & FURTHER RECOMMENDATIONS

No significant volume overload noted in any of the LA measurements. No cardiac medications indicated. Panting may be owing to primary respiratory disease, orthopedic pain, or systemic hypertension.

The heart is stable without clinical disease. No overt contraindication for anesthesia of brief to moderate duration. I suggest Torbutrol premed, Propofol induction, Isoflo maintenance or similar protocol if anesthesia is desired. Blood pressure recommended if not already performed and target white coat negative systolic pressure of < 160 mmHg. If higher than this ACE-inhibitor is suggested to reach this level. Recheck echocardiogram is recommended in 6 months, earlier if murmur grade increases or clinical signs initiate.





PATIENT

Sylar Cardwell

SPECIES

Canine

BREED

Pomeranian X

SEX

Neutered Male

AGE

11 Years

WEIGHT

11.12 Pounds

INTERPRETED BY

Eric Lindquist, DMV

DABVP, Cert. IVUSS

IMAGING PERFORMED BY

Jenna Walsh, CVT

HOSPITAL NAME

Pleasant Hill AH

REFERRING VET

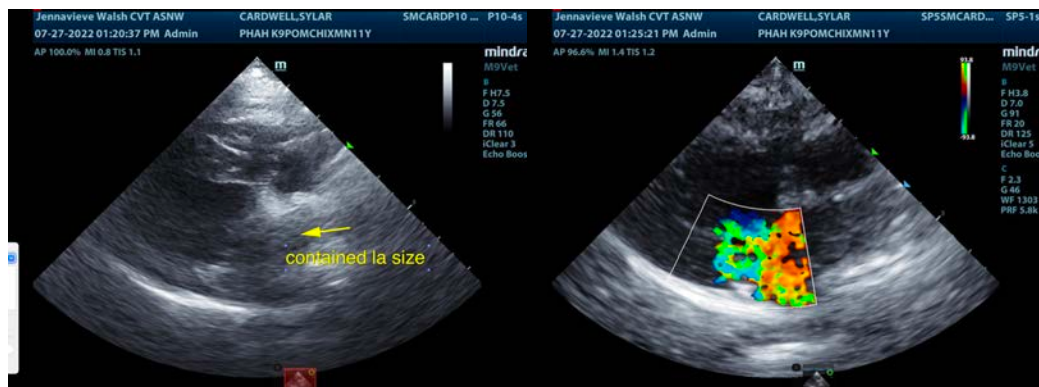
Dr. Supan

INVOICE

39899

DATE

7/27/22



The information and recommendations provided are based on the images presented by the referring veterinarian/sonographer. No evaluation can be communicated regarding pathology that was not visible in the image/video clips provided.

Thank you for this referral. If the clinical or image interpretation does not parallel your findings or if I can be of any further assistance please contact me.

Eric Lindquist, DMV, DABVP, Cert. IVUSS, CEO of SonoPath.com

info@SonoPath.com