



PATIENT

Simba Nielson

SPECIES

Feline

BREED

DSH

SEX

Neutered Male

AGE

11 Years

WEIGHT

15.4 Pounds

INTERPRETED BY

Eric Lindquist, DMV

DABVP, Cert. IVUSS

IMAGING PERFORMED BY

Dr. Brita Kiffney

HOSPITAL NAME

Northshore VH

REFERRING VET

Dr. Brita Kiffney

INVOICE

39893

DATE

7/27/22

PRESENTING CLINICAL SIGNS

Simba diagnosed with hyperthyroidism in November 2021 and referred for I131. Rechecking his TT4 prior to tmt- now normal. Has intermittent diarrhea
Abnormal PE/Chem/CBC/UA Results: TT4 was 6 in November 2021, 1.2 in May 2022 June 2022 his TT4 was 4

ULTRASONOGRAPHIC EXAMINATION OF THE ABDOMEN

Urinary System

The **urinary bladder**, trigone, and pelvic urethra presented normal thicknesses and normal tone. The ureters were not visible which is normal. No uroliths or sediment were visualized and anechoic urine was present. No evidence of inflammatory or neoplastic changes were noted. Ureteral papillae were normal.

The **kidneys** revealed largely normal size and structure, corticomedullary definition and ratio (cortex 1/3 of medulla) were essentially maintained with some age-related loss of curvilinear patterns regarding the capsule and C/M junction. The cortices presented largely uniform texture with some increased echogenicity expected for his age patient. Medullary structure differed distinctly from that of the cortex and no evidence of pelvic dilation was present. The left kidney measured 4.68 cm. Pelvic mineralization was noted in the left kidney measuring 5.0 mm, non-obstructive at the time of the sonogram. The right kidney measured 4.0 cm with pelvic mineralization of 5.0 mm. A cortical infarct was noted in the dorsal cortex of the right kidney, stable, no evidence of active inflammation.

Adrenal Glands

The **right adrenal gland** was visualized and recognized as having normal shape, size, position and echogenicity for this breed. The phrenic vasculature, glandular echogenicity and detail were unremarkable. Capsule, cortex, and medullary definition were normal for this age patient. The right adrenal gland measured 0.50 cm.

The **left adrenal gland** was slightly enlarged and mildly irregular with slight medial expansion. The left adrenal gland measured 0.60 cm.

Spleen

The **spleen** was mildly enlarged with uniform, but subtly micronodular parenchyma, and undulating capsular contour. This is consistent with reactive spleen owing to immune stimulus or early infiltrative disease such as mast cell disease or lymphoma. 25-gauge FNA would be ideal if weight loss is an issue to differentiate early round cell neoplasia versus splenitis or reactive spleen all of which can present in this manner.

Liver

The **liver** images submitted revealed subjectively normal liver size, contour, and structure. Parenchymal echogenicity was naturally coarse and hypoechoic to the spleen. Vascular and biliary tracts were of normal volume with no evidence of congestion. The gallbladder presented acceptably thin walls with primarily anechoic content. The cystic and common bile ducts were normal. No pathological hepatic lymphadenopathy was evident. No overt structural evidence of inflammatory, infiltrative or regenerative pathology was evident.

Gastrointestinal

The **stomach** was filled with progressively shadowing material, consistent with likely hairball or similar material. The small intestine was unremarkable. Intestinal wall thickness measured up to 0.30 cm.



PATIENT

Simba Nielson

Pancreas

The base and limbs of the **pancreas** were observed to be largely isoechoic to surrounding omental fat. Pancreatic duct and capsular contour were acceptably normal and parenchyma respected normal curvilinear patterns. No overt evidence of active inflammatory or neoplastic disease was noted.

SPECIES

Feline

ULTRASONOGRAPHIC FINDINGS

- Pelvic mineralization in both kidneys, non-obstructive
- Irregular left adrenal gland
- Hairball density in the stomach
- Mild splenic enlargement

BREED

DSH

INTERPRETATION OF THE FINDINGS & FURTHER RECOMMENDATIONS

SEX

Neutered Male

If sodium to potassium ratios are elevated, workup for emerging Conn's syndrome recommended, given the irregular left adrenal gland. The cause of diarrhea is unclear. If weight loss is an issue, FNA of the spleen would be indicated, given the mild enlargement. Dietary intolerance, occult parasitism, strongly insignificant inflammatory bowel all possible causes of the GI signs.

AGE

11 Years

WEIGHT

15.4 Pounds

INTERPRETED BY

Eric Lindquist, DMV

DABVP, Cert. IVUSS

IMAGING PERFORMED BY

Dr. Brita Kiffney

HOSPITAL NAME

Northshore VH

REFERRING VET

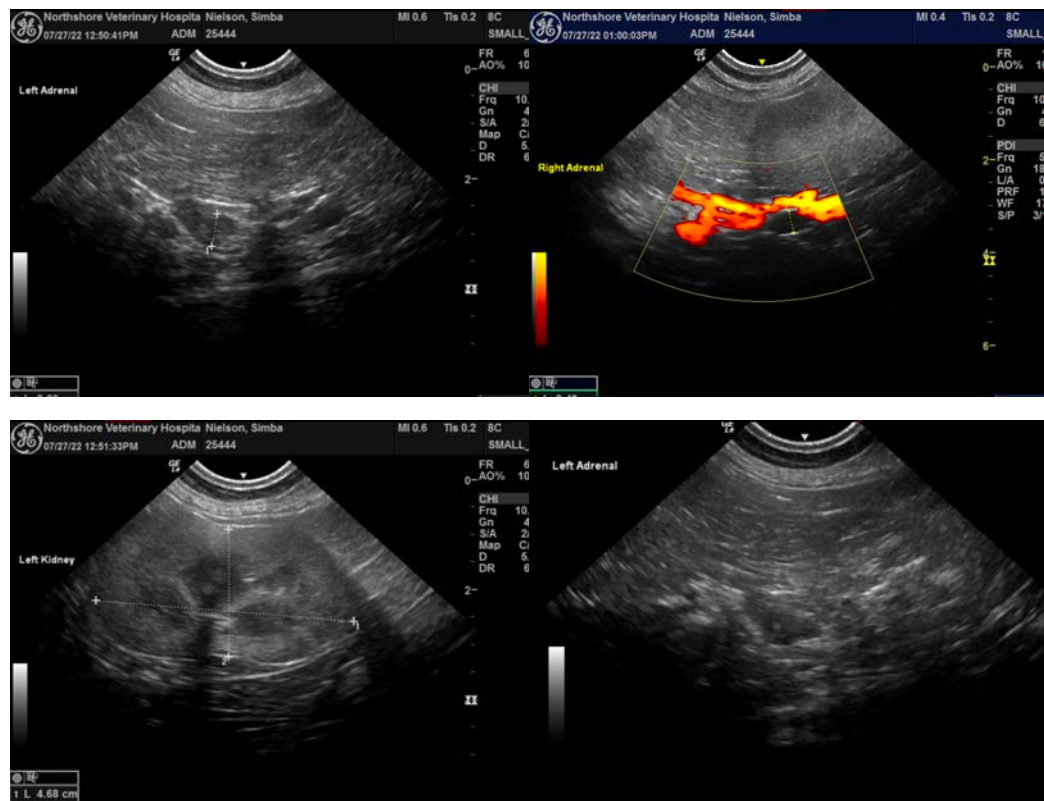
Dr. Brita Kiffney

INVOICE

39893

DATE

7/27/22





PATIENT

Simba Nielson

SPECIES

Feline

BREED

DSH

SEX

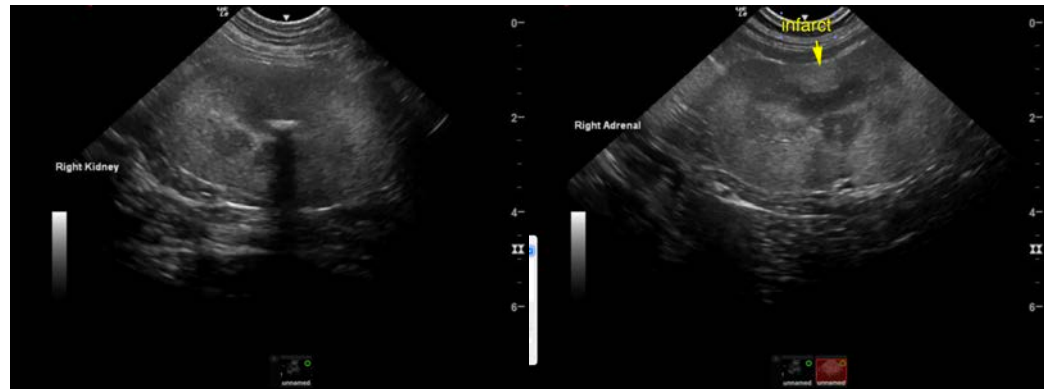
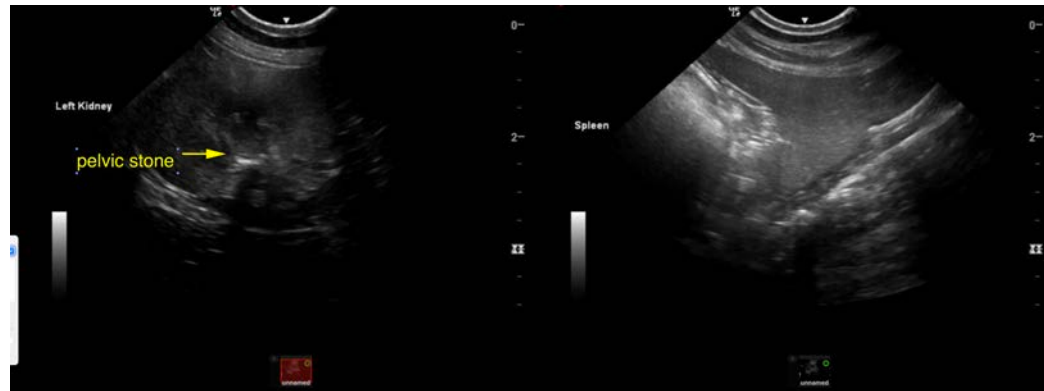
Neutered Male

AGE

11 Years

WEIGHT

15.4 Pounds



INTERPRETED BY

Eric Lindquist, DMV

DABVP, Cert. IVUSS

IMAGING PERFORMED BY

Dr. Brita Kiffney

HOSPITAL NAME

Northshore VH

REFERRING VET

Dr. Brita Kiffney

INVOICE

39893

DATE

7/27/22

The information and recommendations provided are based on the images presented by the referring veterinarian/sonographer. No evaluation can be communicated regarding pathology that was not visible in the image/video clips provided.

Thank you for this referral. If the clinical or image interpretation does not parallel your findings or if I can be of any further assistance please contact me.

Eric Lindquist, DMV, DABVP, Cert. IVUSS, CEO of SonoPath.com

info@SonoPath.com