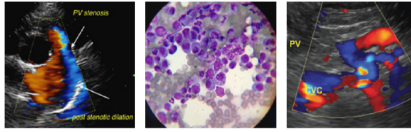



**IMAGING PERFORMED BY**

SVS Mobile Imaging KC 816-401-5010  
svsimagingkc@gmail.com



**PATIENT**

Silke McMullin

**SPECIES**

Canine

**BREED**

Labrador Mix

**SEX**

Spayed female

**AGE**

10 years

**WEIGHT**

68 Pounds

**INTERPRETED BY**

Eric Lindquist, DMV  
DABVP, Cert. IVUSS

**IMAGING PERFORMED BY**

Rachel Runnells RVT

**HOSPITAL NAME**

SVS Imaging Kansas  
City

**REFERRING VET**

Dr. Whitmon

**INVOICE**

31989

**DATE**

7/20/22

**PRESENTING CLINICAL SIGNS**

History: Patient presented for being off, drooling a lot, snoring a lot more, panting a lot. Not sleeping in normal spots and acting weird according to owner. There also seems to be a swelling of the throat. Patient is holding neck out.

Abnormal PE/Chem/CBC/UA Results: Swelling around the ventral aspect of the neck - not feeling well defined thyroid glands, more of a generalized soft tissue swelling.

**ULTRASONOGRAPHIC EXAMINATION**

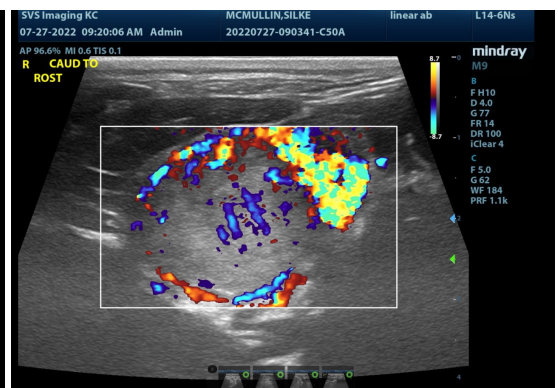
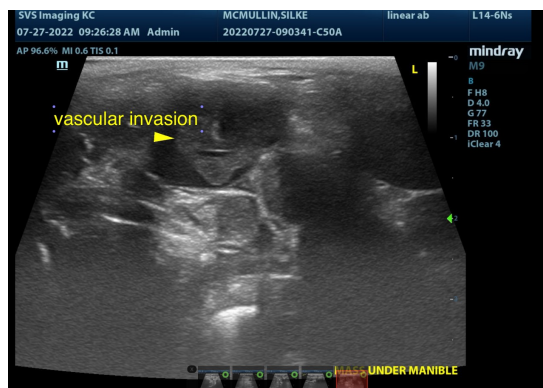
An undifferentiated, mixed, hypoechoic partially capsulated mass was noted in the region of the left thyroid lobe. The mass was highly vascular, typical of thyroid carcinoma. The right thyroid lobe was mildly heterogenous and may represent an extension of the left thyroid pathology. Cystic and nodular components were noted in the left and right thyroid lobes with regional vascular invasion and lymphadenopathy.

**ULTRASONOGRAPHIC FINDINGS**

Extensive thyroid mass deriving from the left and extending to the right with regional lymphadenopathy and vascular invasion.

**INTERPRETATION OF THE FINDINGS & FURTHER RECOMMENDATIONS**

The thyroid mass is not resectable. FNA is recommended to confirm the suspicion of thyroid carcinoma. CT of the region would be ideal with radiation and/or chemotherapy. The prognosis is poor long term. Full thyroid panel is recommended.



Rachel Runnells RVT

SVS Imaging Kansas  
City

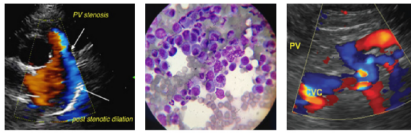

Dr. Whitmon

31989

7/20/22

IMAGING PERFORMED BY

SVS Mobile Imaging KC 816-401-5010  
svsimagingkc@gmail.com



**PATIENT**

Silke McMullin

**SPECIES**

Canine

**BREED**

Labrador Mix

**SEX**

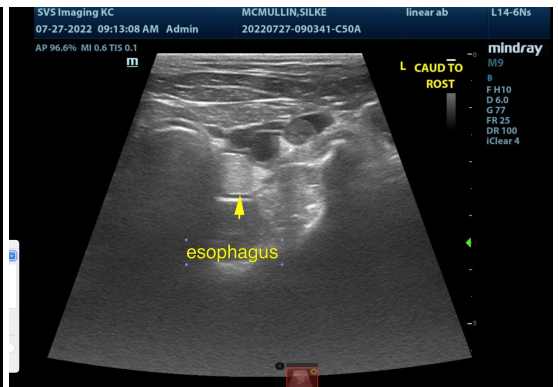
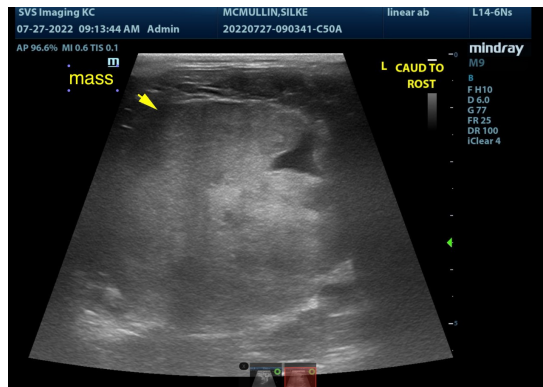
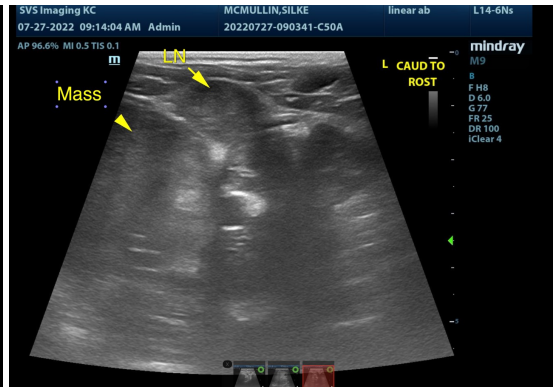
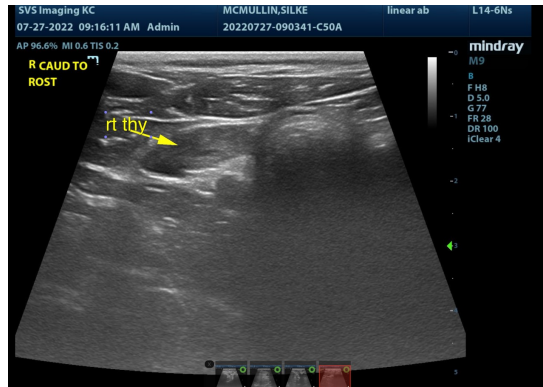
Spayed female

**AGE**

10 years

**WEIGHT**

68 Pounds



**INTERPRETED BY**

Eric Lindquist, DMV  
DABVP, Cert. IVUSS

**IMAGING PERFORMED BY**

Rachel Runnells RVT

**HOSPITAL NAME**

SVS Imaging Kansas  
City

**REFERRING VET**

Dr. Whitmon

**INVOICE**

31989

**DATE**

7/20/22

The information and recommendations provided are based on the images presented by the referring veterinarian/sonographer. No evaluation can be communicated regarding pathology that was not visible in the image/video clips provided.

Thank you for this referral. If the clinical or image interpretation does not parallel your findings or if I can be of any further assistance please contact me.

**Eric Lindquist**, DMV, DABVP, Cert. IVUSS, CEO of SonoPath.com  
Eric.Lindquist@SonoPath.com