



**PATIENT PRESENTING CLINICAL SIGNS**

Lucy Sachs Edema in throat latch area.

**SPECIES LIMITED ULTRASONOGRAPHIC EXAMINATION**

Canine Bilateral fluid filled capsules noted in this patient in the region of the salivary glands, most consistent with sialoceles, appears to be bilateral. The thyroid lobes, trachea, esophagus, and regional tissues appear unaffected.

**BREED**

Boston Terrier

**ULTRASONOGRAPHIC FINDINGS**

**SEX**

- Bilateral sialoceles, more pronounced on the left

Spayed Female

**INTERPRETATION OF THE FINDINGS & FURTHER RECOMMENDATIONS**

**AGE**

11 Years

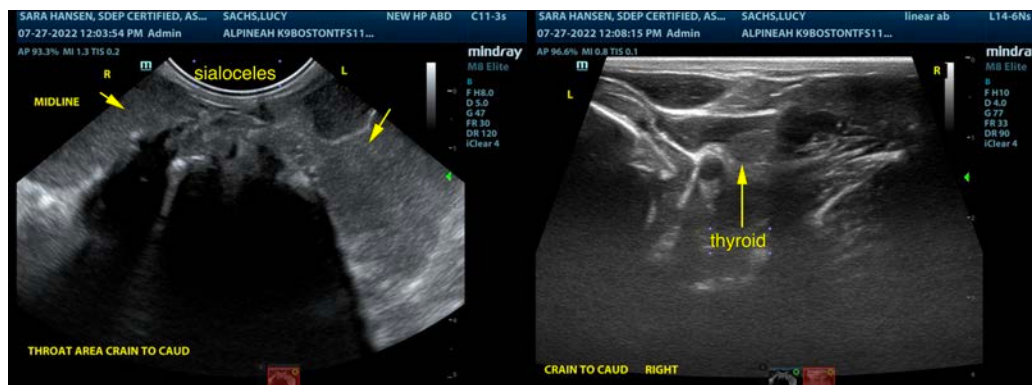
Oral examination for obstruction of the salivary ducts could be considered. Surgical consult recommended. There does not appear to be a significant component noted. Therefore, abscessation is unlikely. However, ultrasound guided drainage, cytology and culture could also be considered from a palliative standpoint.

**WEIGHT**

10.2 Pounds

**INTERPRETED BY**

Eric Lindquist, DMV  
DABVP, Cert. IVUSS

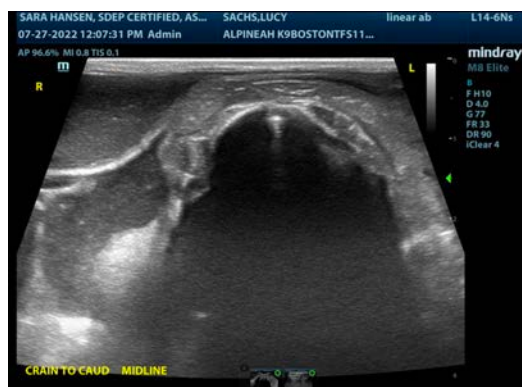

**IMAGING PERFORMED BY**

Sara Hansen

**HOSPITAL NAME**

Alpine AH



**REFERRING VET**

Dr. Clark

**INVOICE**

39898

**DATE**

7/27/22



**PATIENT**

Lucy Sachs

The information and recommendations provided are based on the images presented by the referring veterinarian/sonographer. No evaluation can be communicated regarding pathology that was not visible in the image/video clips provided.

**SPECIES**

Canine

Thank you for this referral. If the clinical or image interpretation does not parallel your findings or if I can be of any further assistance please contact me.

**BREED**

Boston Terrier

**Eric Lindquist**, DMV, DABVP, Cert. IVUSS, CEO of SonoPath.com

[info@SonoPath.com](mailto:info@SonoPath.com)

**SEX**

Spayed Female

**AGE**

11 Years

**WEIGHT**

10.2 Pounds

**INTERPRETED BY**

Eric Lindquist, DMV  
DABVP, Cert. IVUSS

**IMAGING  
PERFORMED BY**

Sara Hansen

**HOSPITAL NAME**

Alpine AH

**REFERRING VET**

Dr. Clark

**INVOICE**

39898

**DATE**

7/27/22