



**PATIENT PRESENTING CLINICAL SIGNS**

Lola Reed History: ADR since lost housemate months ago Takes cytopoint for atopy  
Abnormal PE/Chem/CBC/UA Results: unremarkable physical CBC wnl TG 647 Amylase 1554 Lipase 863

**SPECIES**

Canine

**BREED**

Mix

**SEX**

Spayed female

**AGE**

12 years

**WEIGHT**

45 lbs

**INTERPRETED BY**

Eric Lindquist, DMV  
DABVP, Cert. IVUSS

**IMAGING PERFORMED BY**

Chelsea Pastor

**HOSPITAL NAME**

Fredon AH

**REFERRING VET**

Dr. Grau

**INVOICE**

31988

**DATE**

7/27/22

**ULTRASONOGRAPHIC EXAMINATION OF THE ABDOMEN**

**Urinary System**

The **urinary bladder**, trigone, and pelvic urethra presented normal thicknesses and normal tone. The ureters were not visible which is normal. No uroliths or sediment were visualized and anechoic urine was present. No evidence of inflammatory or neoplastic changes was noted. Ureteral papillae were normal.

The **kidneys** revealed normal size and structure, corticomedullary definition and ratio for this age. The cortices presented largely uniform texture with normal echogenic relationship to liver and spleen. Medullary structure differed distinctly from the cortex and no evidence of pelvic dilation was present. The capsules were acceptably uniform without significant irregularities. The left kidney measured 5.52 cm. The right kidney measured 4.0 cm.

**Adrenal Glands**

Both **adrenal glands** were visualized and recognized as having normal shape, size, position and echogenicity for this breed. The phrenic vasculature, glandular echogenicity and detail were unremarkable. Capsule, cortex, and medullary definition were normal for this age patient. The right adrenal gland measured 1.43 x 0.5 cm.

**Spleen**

The **spleen** was largely smooth with subtle heterogeneous parenchymal changes while maintaining normal echogenic relationship to the liver and kidney. These changes are consistent with normal age-related alteration. The capsule was smooth without noticeable impingement from within the spleen or from pathology in the adjacent abdomen. The splenic vasculature demonstrated normal volume without signs of congestion or significant contraction. No evidence of active acute or chronic inflammatory, neoplastic, or infarctual changes was noted.

**Liver**

The **liver** images submitted revealed subjectively normal liver size, contour, and structure. Parenchymal echogenicity was naturally coarse and hypoechoic to the spleen. Vascular and biliary tracts were of normal volume with no evidence of congestion. The gallbladder presented acceptably thin walls with primarily anechoic content. The cystic and common bile ducts were normal. No pathological hepatic lymphadenopathy was evident. No overt structural evidence of inflammatory, infiltrative or regenerative pathology was evident.



**PATIENT**

**Gastrointestinal**

Lola Reed

The **gastrointestinal** presentation revealed mild uniform prominence of the gastric mucosa as well as areas of "ropy" small intestinal wall with slight disruption of the normal 1:3 muscularis/mucosal ratio. The intestinal submucosa was slightly irregular, thickened and hyperechoic suggestive of low grade, chronic disease. No concerning lymphadenopathy was visible. No evidence of obstruction was present. Chronic inflammatory bowel disease is likely with a low possibility of an early neoplastic event such as lymphoma. Full thickness tissue biopsies via open laparotomy, ideally guided by intraoperative ultrasound in order to obtain the most representative mural sample, would be necessary to rule out this possibility.

**SPECIES**

Canine

**BREED**

Mix

**SEX**

Spayed female

**Pancreas**

The base and limbs of the **pancreas** were observed to be largely isoechoic to surrounding omental fat. Pancreatic duct and capsular contour were acceptably normal and parenchyma respected normal curvilinear patterns. No overt evidence of active inflammatory or neoplastic disease was noted.

**AGE**

12 years

**ULTRASONOGRAPHIC FINDINGS**

Minor intestinal thickening.

**WEIGHT**

45 lbs

Structurally normal pancreas.

**INTERPRETATION OF THE FINDINGS & FURTHER RECOMMENDATIONS**

Underlying inflammatory bowel is likely. The cause of the clinical signs is not evident unless GI signs are the primary issue, then inflammatory bowel is likely. Fecal test, diet change and other causes of clinical signs such as orthopedic, CNS or thoracic disease should also be considered. Baseline cortisol is recommended to rule out underlying Addison's.

**INTERPRETED BY**

Eric Lindquist, DMV  
DABVP, Cert. IVUSS

**IMAGING PERFORMED BY**

Chelsea Pastor

**HOSPITAL NAME**

Fredon AH

**REFERRING VET**

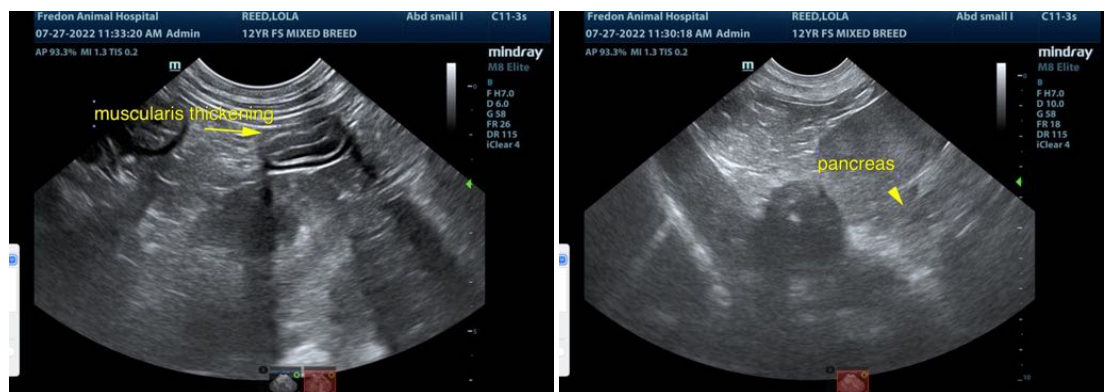
Dr. Grau

**INVOICE**

31988

**DATE**

7/27/22





**PATIENT**

Lola Reed

**SPECIES**

Canine

**BREED**

Mix

**SEX**

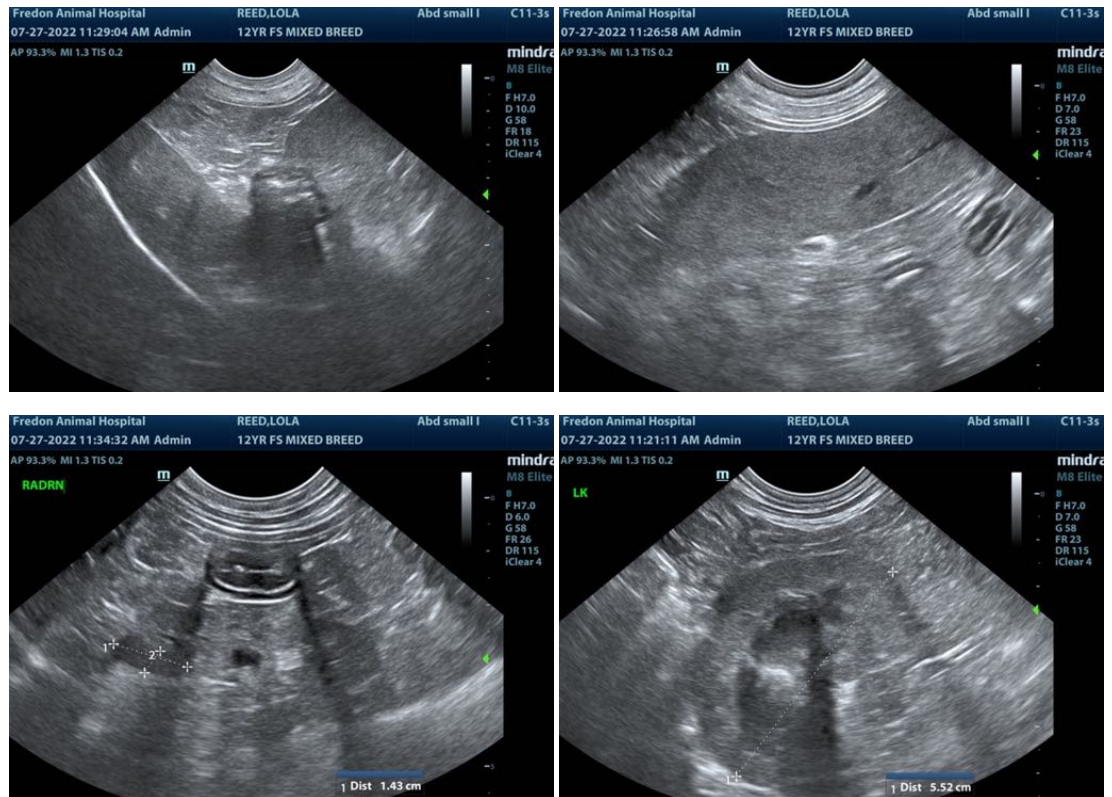
Spayed female

**AGE**

12 years

**WEIGHT**

45 lbs



**INTERPRETED BY**

Eric Lindquist, DMV  
DABVP, Cert. IVUSS

**IMAGING PERFORMED BY**

Chelsea Pastor

**HOSPITAL NAME**

Fredon AH

**REFERRING VET**

Dr. Grau

**INVOICE**

31988

**DATE**

7/27/22

The information and recommendations provided are based on the images presented by the referring veterinarian/sonographer. No evaluation can be communicated regarding pathology that was not visible in the image/video clips provided.

Thank you for this referral. If the clinical or image interpretation does not parallel your findings or if I can be of any further assistance please contact me.

Eric Lindquist, DMV, DABVP, Cert. IVUSS, CEO of SonoPath.com  
info@SonoPath.com