



PATIENT

Julius Jaheen

PRESENTING CLINICAL SIGNS

History: gastroenteritis secondary to presumed fb consumption increased hepatic enzymes, hepatopathy secondary to enteritis

SPECIES

Canine

ULTRASONOGRAPHIC EXAMINATION OF THE ABDOMEN

Urinary System

BREED

Shih Tzu

The **urinary bladder**, trigone, and pelvic urethra presented normal thicknesses and normal tone. The ureters were not visible which is normal. No uroliths or sediment were visualized and anechoic urine was present. No evidence of inflammatory or neoplastic changes was noted. Ureteral papillae were normal.

SEX

Male

The **kidneys** revealed normal size and structure, corticomedullary definition and ratio for this age. The cortices presented largely uniform texture with normal echogenic relationship to liver and spleen. Medullary structure differed distinctly from the cortex and no evidence of pelvic dilation was present. The capsules were acceptably uniform without significant irregularities. The right kidney measured 3.47 cm. The left kidney measured 3.09 cm.

AGE

17 weeks

WEIGHT

5.5 lbs

Adrenal Glands

Both **adrenal glands** were visualized and recognized as having normal shape, size, position and echogenicity for this breed. The phrenic vasculature, glandular echogenicity and detail were unremarkable. Capsule, cortex, and medullary definition were normal for this age patient. The right adrenal gland measured 1.08 x 0.36 cm at the caudal pole and 0.63 cm at the cranial pole. The left adrenal gland measured 1.13 x 0.29 cm at the caudal pole and 0.28 cm at the cranial pole.

INTERPRETED BY

Eric Lindquist, DMV
DABVP, Cert. IVUSS

IMAGING PERFORMED BY

Jenn

Spleen

The **spleen** presented a smooth homogeneous parenchyma hyperechoic to liver and renal cortical parenchyma. The capsule was smooth without noticeable expansion or deviation from within the spleen or adjacent pathology. The splenic vasculature demonstrated normal volume without signs of congestion or thrombosis. No sonographic evidence of acute or chronic inflammatory, neoplastic, or infarctual changes was noted.

HOSPITAL NAME

Rockaway AH

REFERRING VET

Dr. Maniar

Liver

The **liver** images submitted revealed subjectively normal liver size, contour, and structure. Parenchymal echogenicity was naturally coarse and hypoechoic to the spleen. Vascular and biliary tracts were of normal volume with no evidence of congestion. Portal vein to vena cava to aortic ratio was 1:1:1. There was no evidence of portosystemic shunting. The gallbladder presented acceptably thin walls with primarily anechoic content. The cystic and common bile ducts were normal. No pathological hepatic lymphadenopathy was evident. No overt structural evidence of inflammatory, infiltrative or regenerative pathology was evident.

INVOICE

31004

DATE

7/27/22



PATIENT

Julius Jaheen

Gastrointestinal

SPECIES

Canine

The **stomach** was mildly thickened with an empty lumen. There was no evidence of foreign body. The small intestine and colon were unremarkable.

BREED

Shih Tzu

Pancreas

The base and limbs of the **pancreas** were observed to be largely isoechoic to surrounding omental fat. Pancreatic duct and capsular contour were acceptably normal and parenchyma respected normal curvilinear patterns. No overt evidence of active inflammatory or neoplastic disease was noted.

SEX

Male

ULTRASONOGRAPHIC FINDINGS

Non-specific gastroenteritis, no evidence of pathology.

AGE

17 weeks

INTERPRETATION OF THE FINDINGS & FURTHER RECOMMENDATIONS

Symptomatic therapy should prove fruitful.

WEIGHT

5.5 lbs

INTERPRETED BY

Eric Lindquist, DMV
DABVP, Cert. IVUSS

IMAGING PERFORMED BY

Jenn

HOSPITAL NAME

Rockaway AH

REFERRING VET

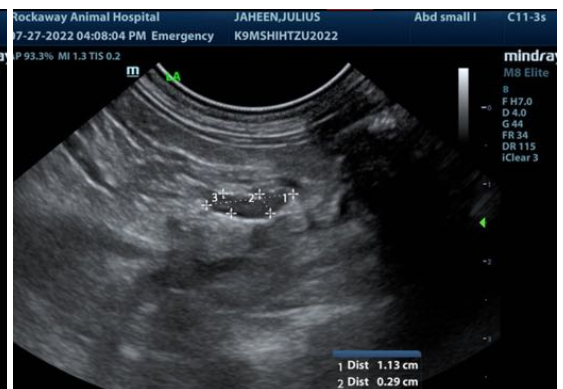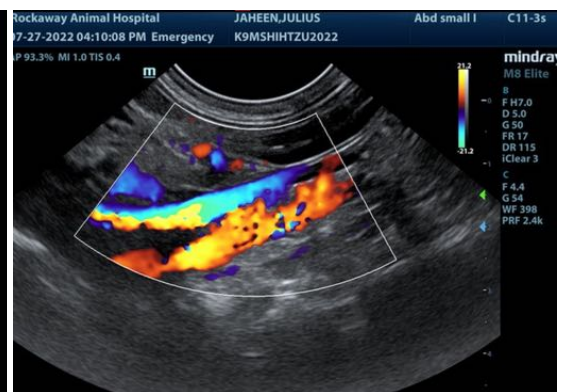
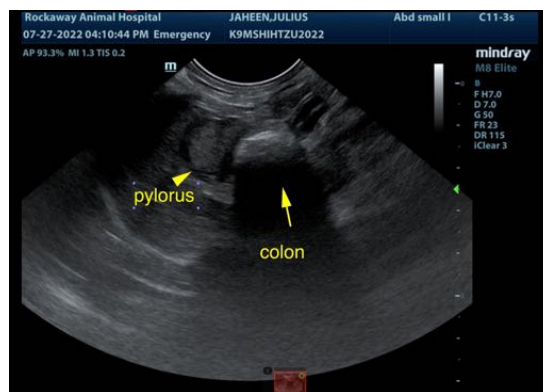
Dr. Maniar

INVOICE

31004

DATE

7/27/22





PATIENT

Julius Jaheen

SPECIES

Canine

BREED

Shih Tzu

SEX

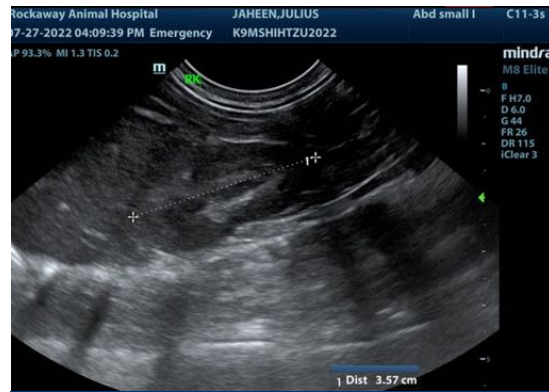
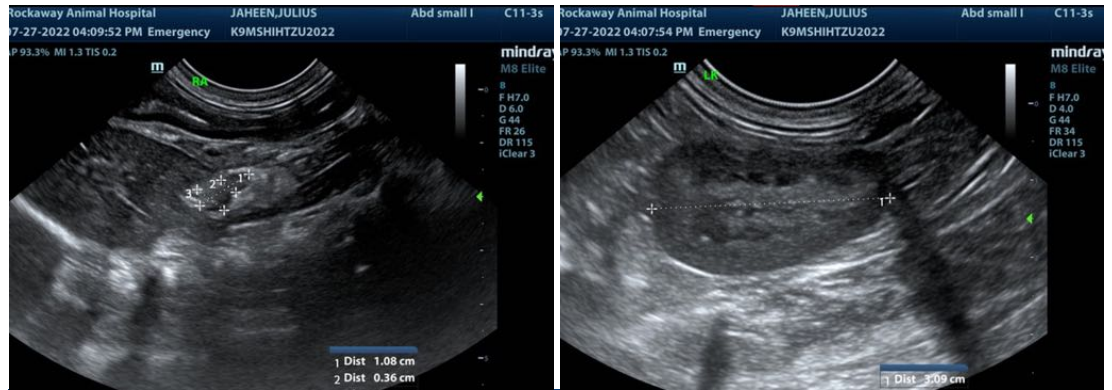
Male

AGE

17 weeks

WEIGHT

5.5 lbs



INTERPRETED BY

Eric Lindquist, DMV
DABVP, Cert. IVUSS

IMAGING PERFORMED BY

Jenn

HOSPITAL NAME

Rockaway AH

REFERRING VET

Dr. Maniar

INVOICE

31004

DATE

7/27/22

The information and recommendations provided are based on the images presented by the referring veterinarian/sonographer. No evaluation can be communicated regarding pathology that was not visible in the image/video clips provided.

Thank you for this referral. If the clinical or image interpretation does not parallel your findings or if I can be of any further assistance please contact me.

Eric Lindquist, DMV, DABVP, Cert. IVUSS, CEO of SonoPath.com
info@SonoPath.com