


PATIENT

Diesel Bellin

PRESENTING CLINICAL SIGNS

Patient with history of loud murmur, on Pimobendan, presents for initial echo. Current med: Pimobendan 3.75 (1/2 tab PO BID).

SPECIES

Canine

ULTRASONOGRAPHIC EXAMINATION OF THE HEART
BREED

Havanese

SEX

Neutered Male

AGE

12 Years

WEIGHT

11.13 Pounds

CANINE CARDIAC PARAMETERS	MR VMAX (m/s)	TR VMAX (m/s)	LA/AO (Boon method)	LA/AO (Heart Base; Swe)	FS (%)	EF (%)	EPSS (cm)
NORMAL PARAMETER	4.5-5.5	<2.7	1.3	<1.6	28-40	40-100	<0.6
PATIENT	5.5		2.3	2.2	40	72	0.1
CANINE CARDIAC PARAMETERS	HR (BPM)	AV VMAX (m/s)	PV MAX (m/s)	BODY WEIGHT (kg)	LA 2D short axis Base view (cm)	LVIDd Avg; 2D and m-mode short axis (cm)	LVIDs Avg; 2D and m-mode short axis (cm)
NORMAL PARAMETER	50-100	0.7-1.7	0.7-1.6	BELOW	BELOW	BELOW	BELOW
PATIENT	115	1.03	1.04		5.18	3.56	

Cardiac Presentation

The cardiac presentation revealed severe volume overload in the left atrium and left ventricle with mitral valve prolapse. Tricuspid insufficiency (4.2 m/sec) and right atrial enlargement also noted, consistent with severe pulmonary hypertension. Pericardial and pleural spaces were unremarkable, yet ascites noted as well as vena cava and hepatic vein dilation. Contractility was subnormal for this type of pathology and not adequately compensatory, consistent with myocardial insufficiency.

INTERPRETED BY

Eric Lindquist, DMV

DABVP, Cert. IVUSS

IMAGING PERFORMED BY

Kelly Vazquez

HOSPITAL NAME

New Bridge VP

REFERRING VET

Dr. Abina Glennon

ULTRASONOGRAPHIC FINDINGS

- C1 valvular disease with left and right-sided failure

INTERPRETATION OF THE FINDINGS & FURTHER RECOMMENDATIONS

Recommend quadrotherapy in this patient with continuation of Pimobendan and adding Lasix at 2-3 mg/kg BID, Spironolactone at 1-2 mg/kg BID, ACE inhibitor 0.5 mg/kg SID progressing to BID, and Sildenafil at 1 mg/kg BID. Recheck echo in one week. BUN, creatinine, blood pressure measurement, chest radiographs all indicated. Sleeping respiratory rate target of <25-30/min. Prognosis is guarded.

INVOICE

39865

DATE

7/27/22



PATIENT

Diesel Bellin

SPECIES

Canine

BREED

Havanese

SEX

Neutered Male

AGE

12 Years

WEIGHT

11.13 Pounds

INTERPRETED BY

Eric Lindquist, DMV
DABVP, Cert. IVUSS

IMAGING PERFORMED BY

Kelly Vazquez

HOSPITAL NAME

New Bridge VP

REFERRING VET

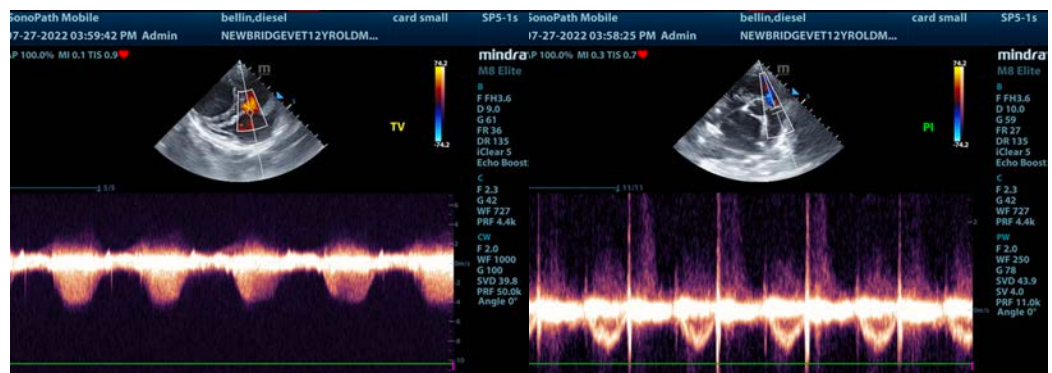
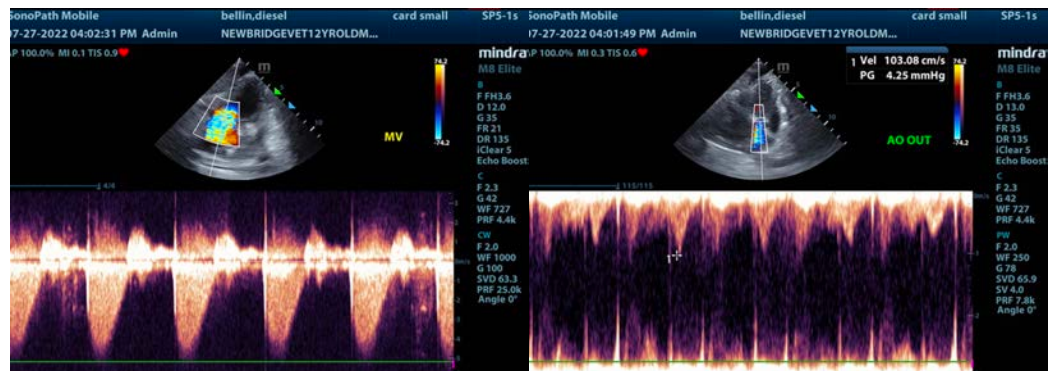
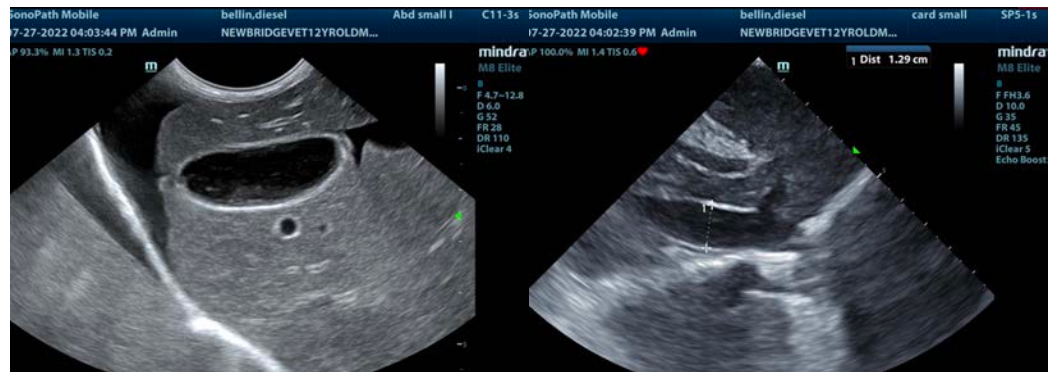
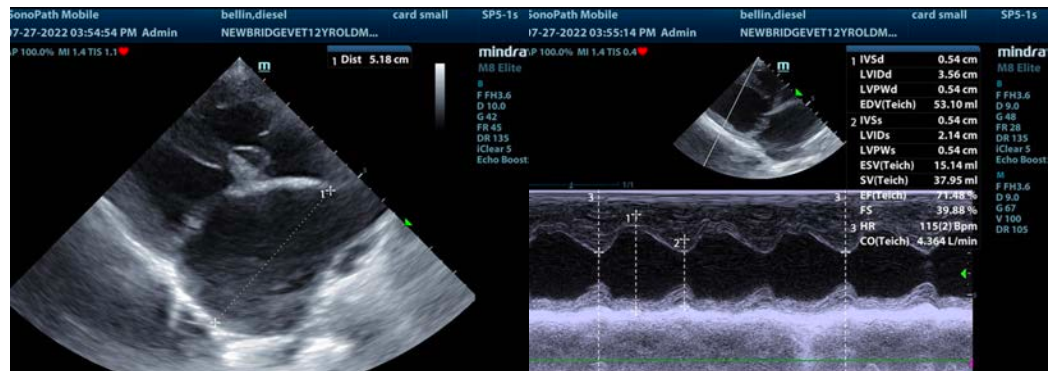
Dr. Abina Glennon

INVOICE

39865

DATE

7/27/22





PATIENT

Diesel Bellin

SPECIES

Canine

BREED

Havanese

SEX

Neutered Male

AGE

12 Years

WEIGHT

11.13 Pounds

INTERPRETED BY

Eric Lindquist, DMV

DABVP, Cert. IVUSS

IMAGING PERFORMED BY

Kelly Vazquez

HOSPITAL NAME

New Bridge VP

REFERRING VET

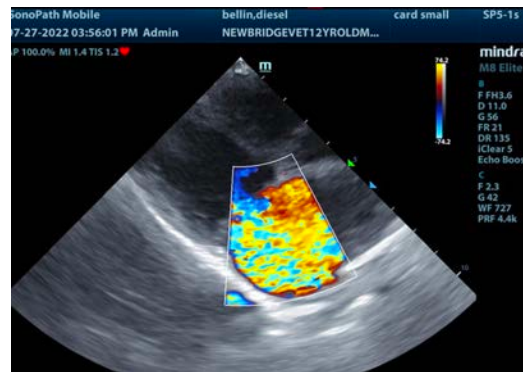
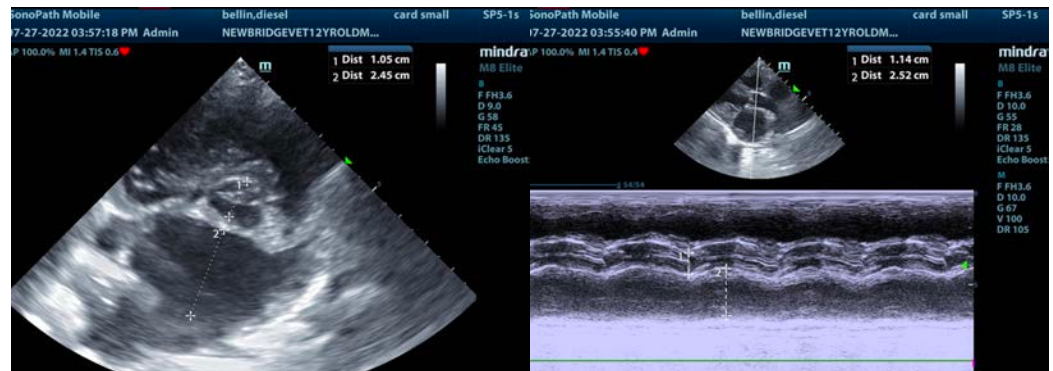
Dr. Abina Glennon

INVOICE

39865

DATE

7/27/22



The information and recommendations provided are based on the images presented by the referring veterinarian/sonographer. No evaluation can be communicated regarding pathology that was not visible in the image/video clips provided.

Thank you for this referral. If the clinical or image interpretation does not parallel your findings or if I can be of any further assistance please contact me.

Eric Lindquist, DMV, DABVP, Cert. IVUSS, CEO of SonoPath.com

info@SonoPath.com