



**PATIENT**

George Brewer  
Disarufino

**SPECIES**

Canine

**BREED**

Terrier Mix

**SEX**

Neutered male

**AGE**

10 years

**WEIGHT**

14 lbs

**INTERPRETED BY**

Eric Lindquist, DMV  
DABVP, Cert. IVUSS

**IMAGING PERFORMED BY**

Dr. McCaughan

**HOSPITAL NAME**

Marina  
VillageVeterinary and  
Integrative Care

**REFERRING VET**

Dr. McCaughan

**INVOICE**

76261

**DATE**

7/26/23

**PRESENTING CLINICAL SIGNS**

History: 10 yr old Yorkshire Terrier X Mn presents for examination prior to full COHAT and extractions (to be performed elsewhere). Dental specialists has requested CBC/Chem/T4/UA, 3view chest films and abdominal ultrasound for screening prior to anesthesia

Abnormal PE/Chem/CBC/UA Results: Labwork pending. 3v chest films - nsf on my review - DACVR report pending. PE - wnl except for severe dental disease

**ULTRASONOGRAPHIC EXAMINATION OF THE ABDOMEN**

**Urinary System**

The **urinary bladder**, trigone, and pelvic urethra presented normal thicknesses and normal tone. The ureters were not visible which is normal. No uroliths or sediment were visualized and anechoic urine was present. No evidence of inflammatory or neoplastic changes was noted. Ureteral papillae were normal.

The **kidneys** revealed normal size and structure, corticomedullary definition and ratio for this age. The cortices presented largely uniform texture with normal echogenic relationship to liver and spleen. Medullary structure differed distinctly from the cortex and no evidence of pelvic dilation was present. The capsules were acceptably uniform without significant irregularities. The right kidney measured 3.96 cm.

**Adrenal Glands**

Both **adrenal glands** were visualized and recognized as having normal shape, size, position and echogenicity for this breed. The phrenic vasculature, glandular echogenicity and detail were unremarkable. Capsule, cortex, and medullary definition were normal for this age patient.

**Spleen**

The **spleen** presented a smooth homogeneous parenchyma hyperechoic to liver and renal cortical parenchyma. The capsule was smooth without noticeable expansion or deviation from within the spleen or adjacent pathology. The splenic vasculature demonstrated normal volume without signs of congestion or thrombosis. No sonographic evidence of acute or chronic inflammatory, neoplastic, or infarctual changes was noted.

**Liver**

The **liver** images submitted revealed subjectively normal liver size, contour, and structure. Parenchymal echogenicity was naturally coarse and hypoechoic to the spleen. Vascular and biliary tracts were of normal volume with no evidence of congestion. The gallbladder presented acceptably thin walls with primarily anechoic content. The cystic and common bile ducts were normal. No pathological hepatic lymphadenopathy was evident. No overt structural evidence of inflammatory, infiltrative or regenerative pathology was evident.



## PATIENT

George Brewer  
Disarufino

## SPECIES

Canine

## BREED

Terrier Mix

## SEX

Neutered male

## AGE

10 years

## WEIGHT

14 lbs

## INTERPRETED BY

Eric Lindquist, DMV  
DABVP, Cert. IVUS

## IMAGING PERFORMED BY

Dr. McCaughan

## HOSPITAL NAME

Marina  
VillageVeterinary and  
Integrative Care

## REFERRING VET

Dr. McCaughan

## INVOICE

76261

## DATE

7/26/23

## Gastrointestinal

There was some residual chyme and gas was noted in the **stomach**, yet not pathological. This is consistent with end post prandial presentation. Transit of chyme into the small intestine was normal. Curvilinear patterns were maintained throughout the GI tract. No evidence of pathology. Small and large intestine demonstrated normal luminal chyme and stool consistency respectively. No obstructive or overt infiltrative disease was noted. No associated abnormal lymphatic activity was noted.

## Pancreas

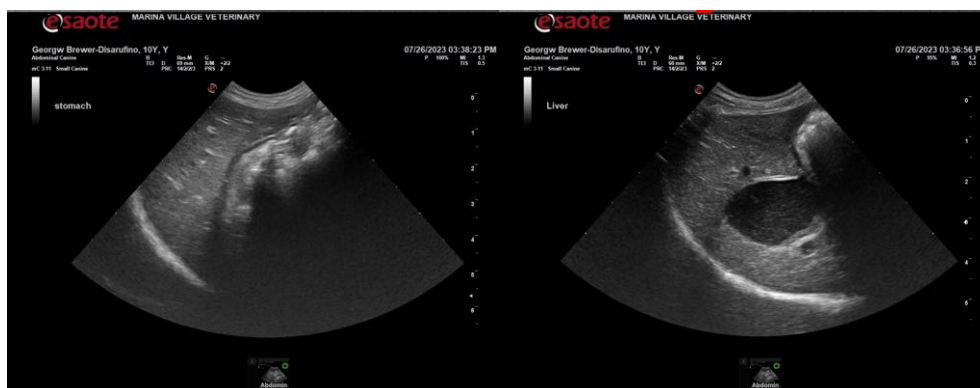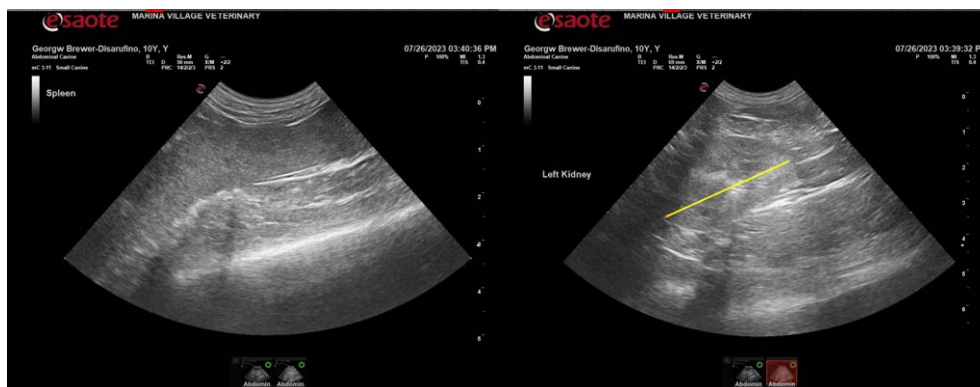The base and limbs of the **pancreas** were observed to be largely isoechoic to surrounding omental fat. Pancreatic duct and capsular contour were acceptably normal and parenchyma respected normal curvilinear patterns. No overt evidence of active inflammatory or neoplastic disease was noted.

## ULTRASONOGRAPHIC FINDINGS

Structurally unremarkable abdomen.

## INTERPRETATION OF THE FINDINGS & FURTHER RECOMMENDATIONS

There was no evidence of pathology.





**PATIENT**

George Brewer Disarufino

**SPECIES**

Canine

**BREED**

Terrier Mix

**SEX**

Neutered male

**AGE**

10 years

**WEIGHT**

14 lbs

**INTERPRETED BY**

Eric Lindquist, DMV  
DABVP, Cert. IVUSS

**IMAGING PERFORMED BY**

Dr. McCaughan

**HOSPITAL NAME**

Marina  
VillageVeterinary and  
Integrative Care

**REFERRING VET**

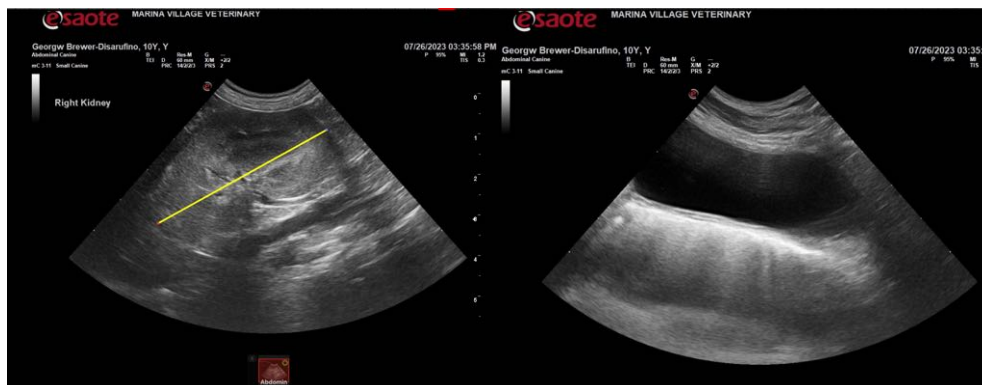
Dr. McCaughan

**INVOICE**

76261

**DATE**

7/26/23



The information and recommendations provided are based on the images presented by the referring veterinarian/sonographer. No evaluation can be communicated regarding pathology that was not visible in the image/video clips provided.

Thank you for this referral. If the clinical or image interpretation does not parallel your findings or if I can be of any further assistance please contact me.

**Eric Lindquist**, DMV, DABVP, Cert. IVUSS, CEO of SonoPath.com  
info@SonoPath.com