



**PATIENT**

Sadie Muntean

**SPECIES**

Canine

**BREED**

Border Collie

**SEX**

Female

**AGE**

10 years

**WEIGHT**

57 lbs

**INTERPRETED BY**

Eric Lindquist, DMV  
DABVP, Cert. IVUSS

**IMAGING PERFORMED BY**

Sammy Burmeister

**HOSPITAL NAME**

Faith AC

**REFERRING VET**

Dr. Faith

**INVOICE**

31968

**DATE**

7/26/22

**PRESENTING CLINICAL SIGNS**

History: One year history of urinating while sleeping. Currently on Proin and Estrogen and patient is still incontinent. Tends to happen when patient comes in from play, drinks, falls asleep and then wakes up with a urine puddle.

Abnormal PE/Chem/CBC/UA Results: Attached is patient's radiographs for reference.

**ULTRASONOGRAPHIC EXAMINATION OF THE ABDOMEN**

**Urinary System**

The **urinary bladder**, trigone, and pelvic urethra presented normal thicknesses and normal tone. The ureters were not visible which is normal. No uroliths or sediment were visualized and anechoic urine was present. No evidence of inflammatory or neoplastic changes was noted. Ureteral papillae were normal.

The **kidneys** revealed normal size and structure, corticomedullary definition and ratio for this age. The cortices presented largely uniform texture with normal echogenic relationship to liver and spleen. Medullary structure differed distinctly from the cortex and no evidence of pelvic dilation was present. The capsules were acceptably uniform without significant irregularities. The left kidney measured 6.0 cm. The right kidney measured 6.0 cm.

**Adrenal Glands**

The left **adrenal gland** was visualized and recognized as having normal shape, size, position and echogenicity for this breed. The phrenic vasculature, glandular echogenicity and detail were unremarkable. Capsule, cortex, and medullary definition were normal for this age patient. The right adrenal gland was not visualized.

**Spleen**

The **spleen** in this patient was mildly enlarged with uniform parenchyma and was folded upon itself cranially. This is a positional variant and is not pathological. There was no evidence of significant disease.

**Liver**

The **liver** was uniformly swollen with minor, excessive gallbladder debris and over distension with dependent and suspended bile without evidence of overt mucocele formation. However, excessive sludge was present. The liver presented coarse architecture with mildly increased portal markings and subtle, mixed echogenic changes. This is consistent with vacuolar hepatopathy and some level of remodeling and history of inflammatory component. There was no overt suspicion of neoplasia.

**Gastrointestinal**

Examination of the **gastrointestinal tract** revealed a stomach and intestine free of stasis, of normal wall thickness, acceptable curvilinear mural detail, and peristaltic activity. Small and large intestine



**PATIENT**

Sadie Muntean

demonstrated normal luminal chyme and stool consistency respectively. No obstructive or overt infiltrative disease was noted. No associated abnormal lymphatic activity was noted.

**SPECIES**

Canine

**Pancreas**

The base and limbs of the **pancreas** were observed to be largely isoechoic to surrounding omental fat. Pancreatic duct and capsular contour were acceptably normal and parenchyma respected normal curvilinear patterns. No overt evidence of active inflammatory or neoplastic disease was noted.

**BREED**

Border Collie

**Free Abdomen**

**SEX**

Female

The iliac trifurcation was unremarkable.

**ULTRASONOGRAPHIC FINDINGS**

**AGE**

10 years

Structurally unremarkable abdomen.  
Largely age related renal and hepatic changes.

**WEIGHT**

57 lbs

**INTERPRETATION OF THE FINDINGS & FURTHER RECOMMENDATIONS**

There is no evidence of significant disease. Examination of the vaginal vestibule as well as lumbosacral or thoracolumbar orthopedic issues that may be playing a role.

**INTERPRETED BY**

Eric Lindquist, DMV  
DABVP, Cert. IVUS

**IMAGING PERFORMED BY**

Sammy Burmeister

**HOSPITAL NAME**

Faith AC

**REFERRING VET**

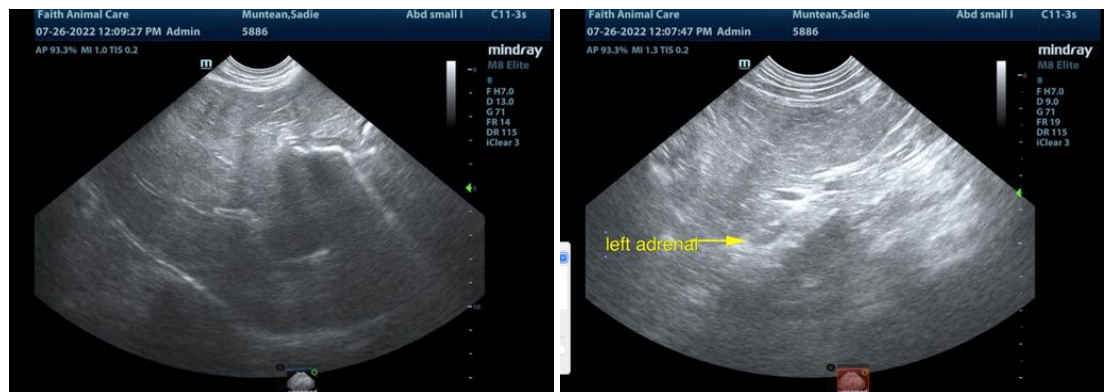
Dr. Faith

**INVOICE**

31968

**DATE**

7/26/22





**PATIENT**

Sadie Muntean

**SPECIES**

Canine

**BREED**

Border Collie

**SEX**

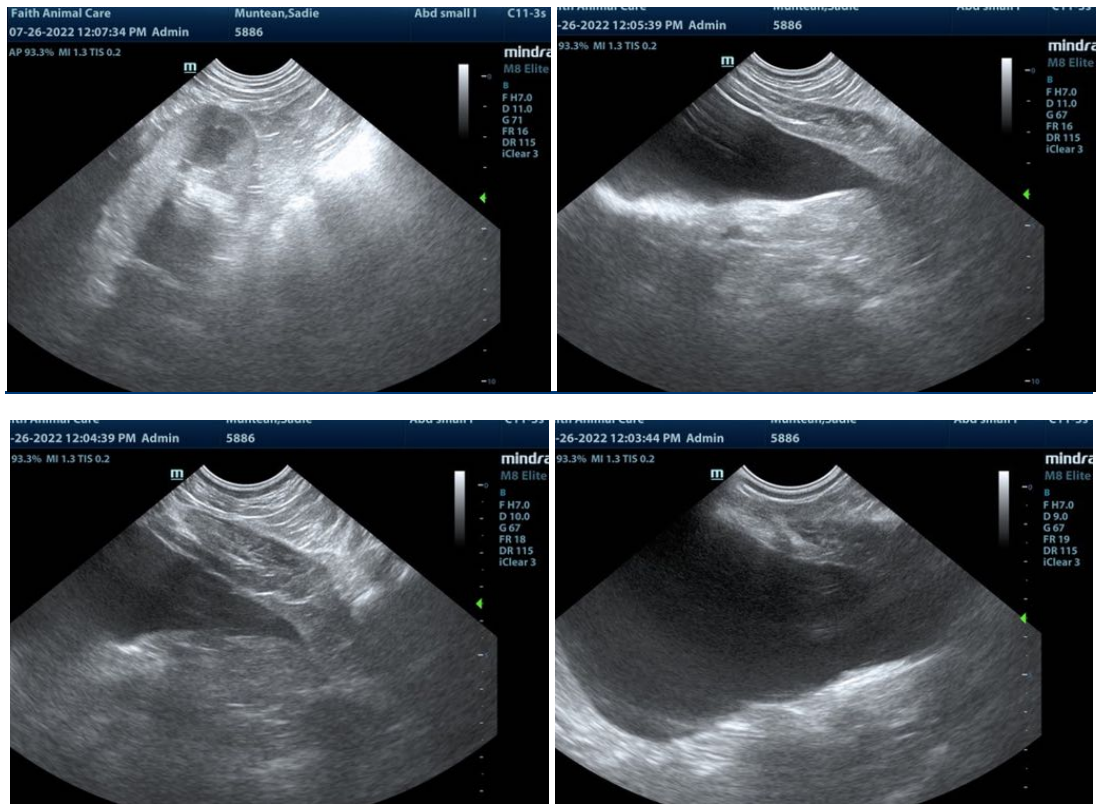
Female

**AGE**

10 years

**WEIGHT**

57 lbs



**INTERPRETED BY**

Eric Lindquist, DMV  
DABVP, Cert. IVUSS

**IMAGING PERFORMED BY**

Sammy Burmeister

**HOSPITAL NAME**

Faith AC

**REFERRING VET**

Dr. Faith

**INVOICE**

31968

**DATE**

7/26/22

The information and recommendations provided are based on the images presented by the referring veterinarian/sonographer. No evaluation can be communicated regarding pathology that was not visible in the image/video clips provided.

Thank you for this referral. If the clinical or image interpretation does not parallel your findings or if I can be of any further assistance please contact me.

Eric Lindquist, DMV, DABVP, Cert. IVUSS, CEO of SonoPath.com  
info@SonoPath.com