

**PATIENT**

Moose Plake

**SPECIES**

Canine

**BREED**

Labrador

**SEX**

Intact Male

**AGE**

3 years

**WEIGHT**

82.6 lbs

**INTERPRETED BY**

Eric Lindquist, DMV  
DABVP, Cert. IVUSS

**IMAGING PERFORMED BY**

Rachel Runnells, RVT

**HOSPITAL NAME**

SVS Imaging Kansas  
City

**REFERRING VET**

Dr. Servos

**INVOICE**

31917

**DATE**

7/26/22

**PRESENTING CLINICAL SIGNS**

History: Patient presented with firm swelling on rear left leg in early July. The area that is swollen now, was firm, but the rest of leg had pitting edema. Treated with doxycycline and carprofen. Swelling went down everywhere except the firm swelling where it is now. Now, proximal caudomedial thigh moderately swollen & firm, nonpainful to palpation. Wound opened on caudal surface last week, unable to express material but does release blood occasionally when moving from sitting to standing. Swelling and wound is worse today since last Thursday. Drips blood-tinged fluid from wound. On prednisone now.

Abnormal PE/Chem/CBC/UA Results: Radiographs when swelling first happened showed edema, but no foreign body or broken bone, or any other reason for edema noted.

**ULTRASONOGRAPHIC EXAMINATION**

A 12+ cm largely parenchymal, yet cavitated mass was noted in this patient and was deriving from the muscle belly under interrogation. The mass extended to the subcutaneous space and periosteum. The margins of the mass were poorly defined with regional inflammation and infiltrative peripheral pattern. The mass does not appear cleanly resectable without amputation. This is strongly suggestive for sarcoma.

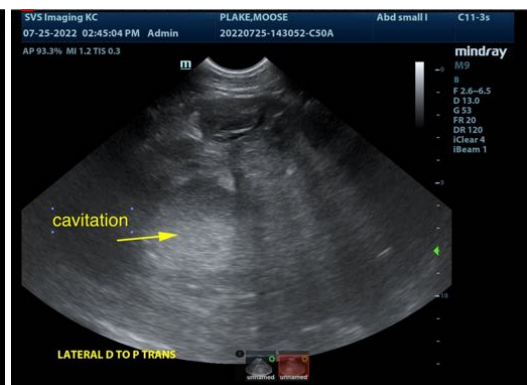
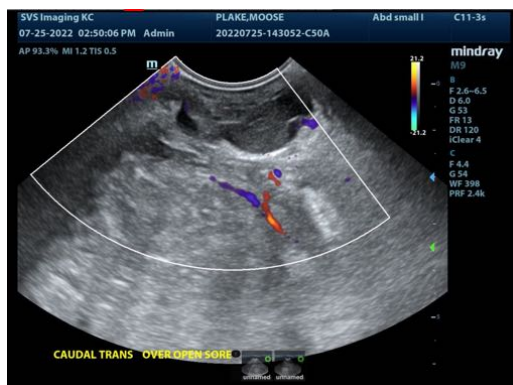The testicles were imaged with no evidence of pathology. However, one testicle was larger than the other.

**ULTRASONOGRAPHIC FINDINGS**

Cavitated sarcoma type mass extending throughout the muscle belly and fascia.

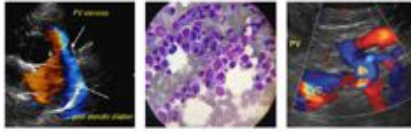
**INTERPRETATION OF THE FINDINGS & FURTHER RECOMMENDATIONS**

CT evaluation is warranted for further definition. FNA of the parenchymal portions of the mass is recommended for further definition. Abdominal sonogram is warranted as well as chest radiographs to assess for related pathology.



**IMAGING PERFORMED BY**

SVS Mobile Imaging KC 816-401-5010  
svsimagingkc@gmail.com



Clinical Sonography & Telectology

EDUCATIONAL TELECONSULTATION SERVICES™

1-800-838-4268 info@sonopath.com SonoPath.com

**PATIENT**

Moose Plake

**SPECIES**

Canine

**BREED**

Labrador

**SEX**

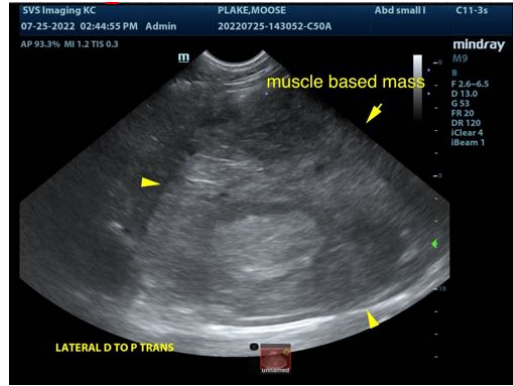
Intact Male

**AGE**

3 years

**WEIGHT**

82.6 lbs



The information and recommendations provided are based on the images presented by the referring veterinarian/sonographer. No evaluation can be communicated regarding pathology that was not visible in the image/video clips provided.

Thank you for this referral. If the clinical or image interpretation does not parallel your findings or if I can be of any further assistance please contact me.

**Eric Lindquist**, DMV, DABVP, Cert. IVUSS, CEO of SonoPath.com  
Eric.Lindquist@SonoPath.com

**INTERPRETED BY**

Eric Lindquist, DMV  
DABVP, Cert. IVUSS

**IMAGING PERFORMED BY**

Rachel Runnells, RVT

**HOSPITAL NAME**

SVS Imaging Kansas  
City

**REFERRING VET**

Dr. Servos

**INVOICE**

31917

**DATE**

7/26/22