



PATIENT

Aphrodite DeMartino

SPECIES

Feline

BREED

DSH

SEX

Spayed Female

AGE

13 Years 8 Months

WEIGHT

7.3 Pounds

INTERPRETED BY

Eric Lindquist, DMV
DABVP, Cert. IVUSS

IMAGING PERFORMED BY

Eric Lindquist, DMV
DABVP, Cert. IVUSS

HOSPITAL NAME

Greenwood Lake AH

REFERRING VET

Dr. Streng

INVOICE

16551

DATE

7/26/22

PRESENTING CLINICAL SIGNS

History: Mass effect palp abd + 4/6 systolic heart murmur (echo/abd)

ULTRASONOGRAPHIC EXAMINATION OF THE HEART & ABDOMEN

FELINE CARDIAC PARAMETERS	BODY WEIGHT (kg)	HR (BPM)	IVSd (cm)	LVIDd (cm)	LVWd (cm)	FS (%)	EF (%)
NORMAL PARAMETER	-----	150-240	0.3-0.6	1.0-2.1	0.25-0.6	35-67	80-100
PATIENT	--	214	0.35	1.41	0.45	65	94
FELINE CARDIAC PARAMETERS	LA/AO (Boon)	LA/AO HEART BASE (Sisson)	LA 2D 4-chamber long axis AS to FW (Sisson) (cm)	LVOT VEL. (m/s)	RVOT VEL. (m/s)	IVRT (m/)	
NORMAL PARAMETER	<1.5	0.88-1.79	0.7-1.7	<1.6	<1.3	40-60	
PATIENT	1.2	1.1	1.2	1.30	.92	NM	
Adapted from June Boon, Veterinary Echocardiography, 1998							
Sisson D et al. JVIM 1991; 5: 232, Jacobs et al. Am J Vet Res 1985; 46:1705							

Cardiac Presentation

The echocardiogram in this patient demonstrated normal **left atrial** size based on 3 separate LA measurements. The cranial and caudal **mitral** valve leaflets presented normal linear structure and kinetics. The **left ventricle** presented normal thicknesses with linear contour and was not dilated nor restricted. The **myocardium** presented normal echogenicity without subjective evidence of significant fibrotic or ischemic disease. **Contractility** of the ventricular walls was adequate and in normal range for this patient evidenced by the fractional shortening measurement and subjective evaluation of the different regions and angles of the myocardium. The **left ventricular outflow** tract demonstrated normal laminar flow and subjective structural integrity. The **right atrium** and auricle revealed normal size, structure and content. No evidence of masses was noted or chamber overload. **Tricuspid** valvular assessment demonstrated adequate linear morphology and kinetics. The **right ventricle** was of normal size (1/3 diameter of LV), chordae structure, myocardial echogenicity and thickness. **Pulmonic** tract assessment revealed normal valve structure, laminar flow, and diameter (approx. 1:1 pa/ao ratio). No visible **pericardial** or free pleura fluid was noted or extra cardiac pathology in the visible planes. The cranial **mediastinum and pericardial regions** were free of masses in the visible window.

Urinary System

The **urinary bladder**, trigone, and pelvic urethra presented normal thicknesses and normal tone. The ureters were not visible which is normal. No uroliths or sediment were visualized and anechoic urine was present. No evidence of inflammatory or neoplastic changes were noted. Ureteral papillae were normal.

The **left kidney** revealed significant dystrophic changes, cortical collapse at the caudal pole, pelvic mineralization and infarct. The left kidney measured 2.3 cm.



PATIENT

The **right kidney** revealed a 0.7 cm pelvic calculus, cortical remodeling and infarct. The right kidney measured 4.4 cm.

Aphrodite DeMartino

Adrenal Glands

SPECIES

Both **adrenal glands** were visualized and recognized as having normal shape, size, position and echogenicity for this breed. The phrenic vasculature, glandular echogenicity and detail were unremarkable. Capsule, cortex, and medullary definition were normal for this age patient.

Feline

BREED

Spleen

DSH

The **spleen** in this patient was uniform, yet volume contracted. Hydration status should be assessed.

SEX

Liver

Spayed Female

The **liver** images submitted revealed subjectively normal liver size, contour, and structure. Parenchymal echogenicity was naturally coarse and hypoechoic to the spleen. Vascular and biliary tracts were of normal volume with no evidence of congestion. The gallbladder presented acceptably thin walls with primarily anechoic content. The cystic and common bile ducts were normal. No pathological hepatic lymphadenopathy was evident. No overt structural evidence of inflammatory, infiltrative or regenerative pathology was evident.

AGE

13 Years 8 Months

Gastrointestinal

WEIGHT

The **stomach** was filled with progressively shadowing material, suspect hairball accumulation. The colon presented hard stool.

7.3 Pounds

Pancreas

INTERPRETED BY

The base and limbs of the **pancreas** were observed to be largely isoechoic to surrounding omental fat. Some moderate parenchymal remodeling, however, with mild deviation from curvilinear normalcy was observed. Pancreatic duct and capsular irregularities were present consistent with age related changes. If pain upon imaging (+ Murphy sign) was present or if the patient is focally painful in subxyphoid palpation then low-grade smoldering chronic pancreatitis should be suspected.

Eric Lindquist, DMV
DABVP, Cert. IVUSS

IMAGING PERFORMED BY

ULTRASONOGRAPHIC FINDINGS

Eric Lindquist, DMV
DABVP, Cert. IVUSS

- Normal echocardiogram, likely physiological flow murmur
- Hairball density in the stomach
- Hard stool in the colon
- No evident masses
- Dystrophic left kidney
- Chronic pancreatic changes, history of pancreas is likely
- Volume contracted spleen

HOSPITAL NAME

Greenwood Lake AH

REFERRING VET

Dr. Streng

INTERPRETATION OF THE FINDINGS & FURTHER RECOMMENDATIONS

INVOICE

16551

Flow murmurs can be caused by volume shifts, anemia, excitable/tachycardic state, DRVOTO (Dynamic Right Ventricular Outflow Obstruction), or even simple stethoscope pressure upon clinical exam. These flow murmurs are typically benign and may develop often later in life theoretically owing to age related clinically insignificant changes of the heart. If the patient is recently clinical for anorexia, weight loss or metabolic disturbances, an abdominal sonogram and full workup may be appropriate to assess underlying clinical systemic causes of a newly developed flow murmur.

DATE

7/26/22



PATIENT

Aphrodite DeMartino

No contraindication to anesthetic procedure. Torbutrol (premed), propofol (induction), isoflurane (maintenance) suggested. Hairball therapy is warranted over the next month and recheck sonogram at that time.

SPECIES

Feline

BREED

DSH

SEX

Spayed Female

AGE

13 Years 8 Months

WEIGHT

7.3 Pounds

INTERPRETED BY

Eric Lindquist, DMV
DABVP, Cert. IVUSS

IMAGING PERFORMED BY

Eric Lindquist, DMV
DABVP, Cert. IVUSS

HOSPITAL NAME

Greenwood Lake AH

REFERRING VET

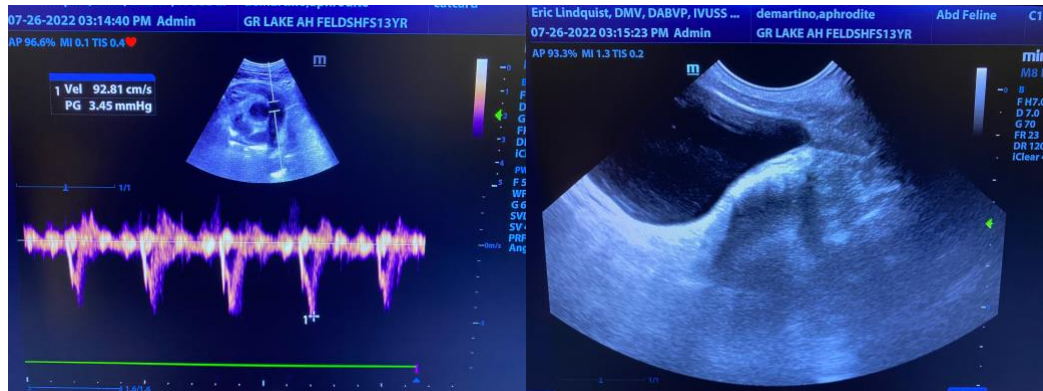
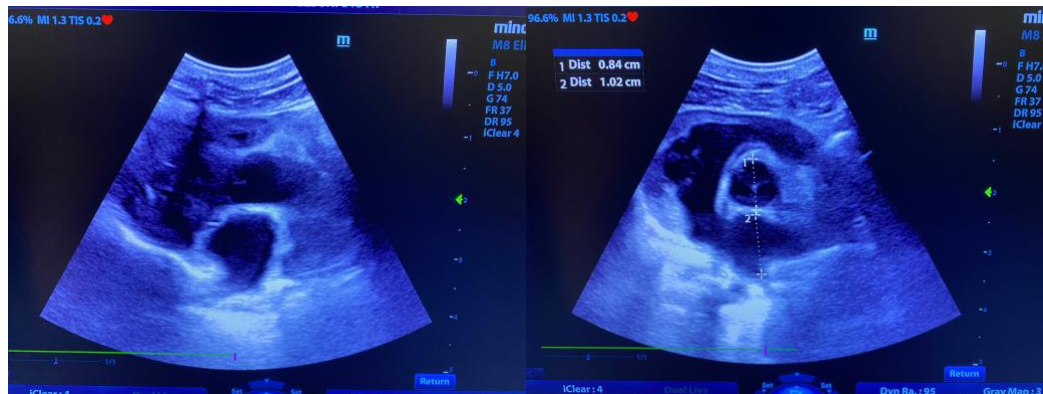
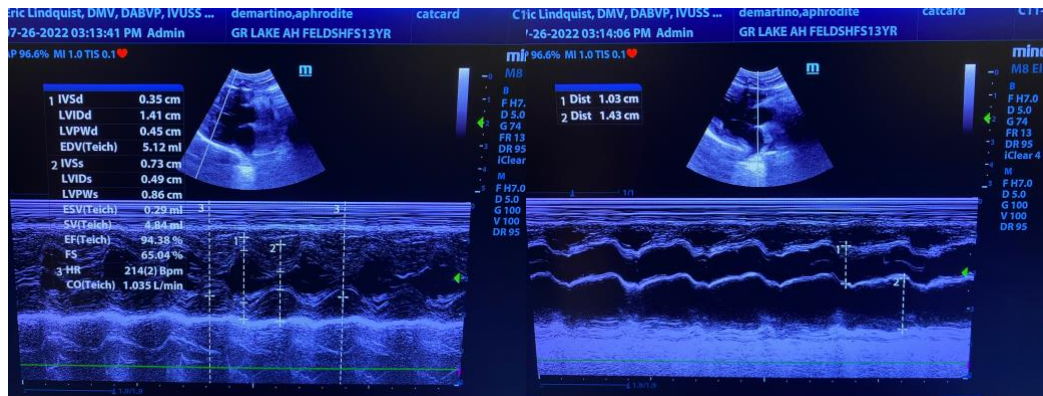
Dr. Streng

INVOICE

16551

DATE

7/26/22





PATIENT

Aphrodite DeMartino

SPECIES

Feline

BREED

DSH

SEX

Spayed Female

AGE

13 Years 8 Months

WEIGHT

7.3 Pounds

INTERPRETED BY

Eric Lindquist, DMV
DABVP, Cert. IVUSS

IMAGING PERFORMED BY

Eric Lindquist, DMV
DABVP, Cert. IVUSS

HOSPITAL NAME

Greenwood Lake AH

REFERRING VET

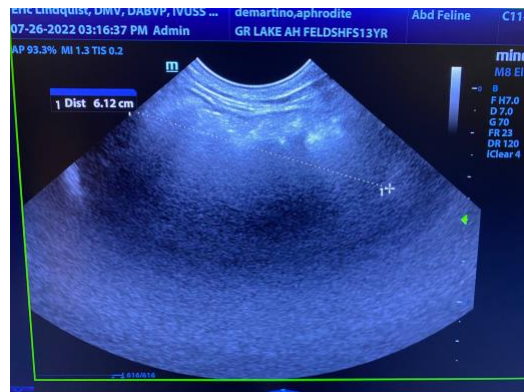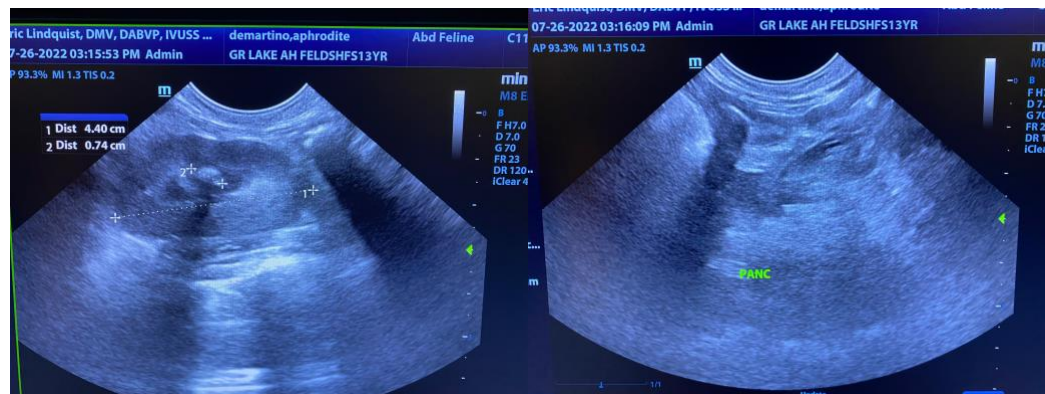
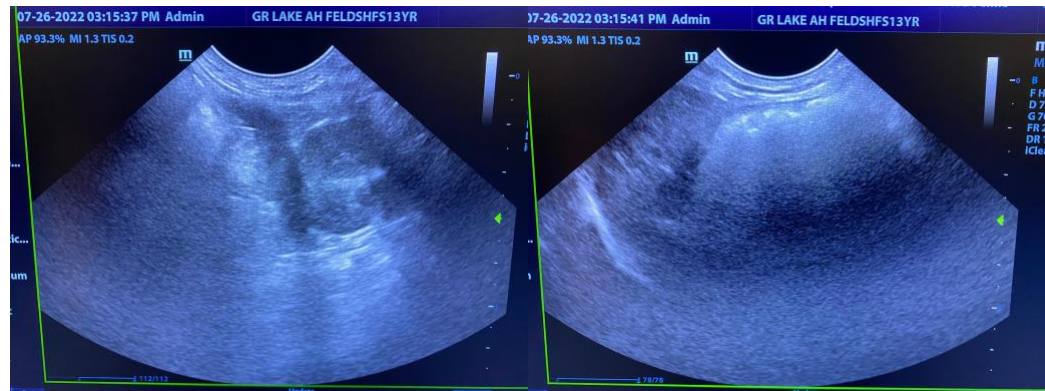
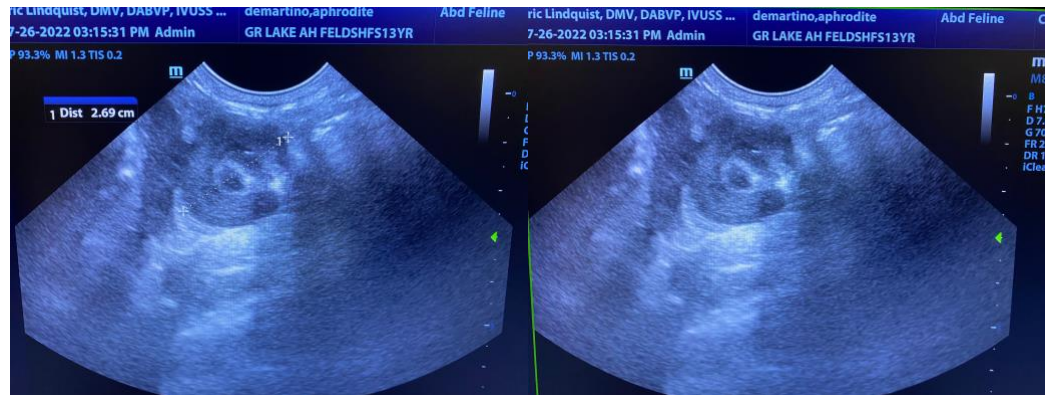
Dr. Streng

INVOICE

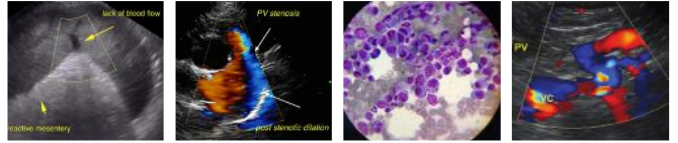
16551

DATE

7/26/22



The information and recommendations provided are based on the images presented by the



PATIENT

Aphrodite DeMartino

SPECIES

Feline

BREED

DSH

SEX

Spayed Female

AGE

13 Years 8 Months

WEIGHT

7.3 Pounds

INTERPRETED BY

Eric Lindquist, DMV
DABVP, Cert. IVUSS

**IMAGING
PERFORMED BY**

Eric Lindquist, DMV
DABVP, Cert. IVUSS

HOSPITAL NAME

Greenwood Lake AH

REFERRING VET

Dr. Streng

INVOICE

16551

DATE

7/26/22

referring veterinarian. No evaluation can be communicated regarding pathology that was not visible in the image/video clips provided.

Thank you for this referral. If the clinical or image interpretation does not parallel your findings or if I can be of any further assistance please contact me.

Eric Lindquist, DMV, DABVP, Cert. IVUSS, CEO of SonoPath.com

info@SonoPath.com