



**PATIENT**

Jake Feldman

**SPECIES**

Canine

**BREED**

German Shepherd

**SEX**

Neutered male

**AGE**

12 ½ years

**WEIGHT**

89 lbs

**INTERPRETED BY**

Eric Lindquist, DMV  
DABVP, Cert. IVUSS

**IMAGING PERFORMED BY**

Dr. Todd

**HOSPITAL NAME**

Lambs Gap AH

**REFERRING VET**

Dr. Todd

**INVOICE**

31906

**DATE**

7/25/22

**PRESENTING CLINICAL SIGNS**

History: Jake is a twelve year old, MN, German Shepherd with a recent history (2 weeks) of large volumes of urine-accidents in house. This is very unlike Jake. Normal thirst, normal appetite, no vomiting or diarrhea. No salt based water softeners in house. Current meds are dasuquin joint supplement and gabapentin on bad days. CBC, Chemistry, T4, cPL are all normal on 7/19/22. UA on 7/18/22 showed USG=1.020, pH=6.5 and no evidence of UTI. Amoxicillin trial has not shown an improvement in symptoms.

**ULTRASONOGRAPHIC EXAMINATION OF THE ABDOMEN**

**Urinary System**

The **urinary bladder**, trigone, and pelvic urethra presented normal thicknesses and normal tone. The ureters were not visible which is normal. No uroliths or sediment were visualized and anechoic urine was present. No evidence of inflammatory or neoplastic changes was noted. Ureteral papillae were normal.

The residual prostate measured 1.3 cm. Minor pre prostatic and prostatic urethral dilation was noted. There is no evidence of masses or obstructive disease.

The **kidneys** revealed normal size and structure, corticomedullary definition and ratio for this age. The cortices presented largely uniform texture with normal echogenic relationship to liver and spleen. Medullary structure differed distinctly from the cortex and no evidence of pelvic dilation was present. The capsules were acceptably uniform without significant irregularities. The right kidney measured 7.8 cm. The left kidney measured 7.08 cm.

**Adrenal Glands**

Both **adrenal glands** were visualized and recognized as having normal shape, size, position and echogenicity for this breed. The phrenic vasculature, glandular echogenicity and detail were unremarkable. Capsule, cortex, and medullary definition were normal for this age patient. The left adrenal gland measured 1.6 x 0.44 cm at the cranial pole and 0.56 cm at the caudal pole. The right adrenal gland measured 2.0 x 0.6 cm.

**Spleen**

The **spleen** in this patient was mildly enlarged with uniform parenchyma and was folded upon itself cranially. This is a positional variant and is not pathological. There was no evidence of significant disease.

**Liver**

The **liver** images submitted revealed subjectively normal liver size, contour, and structure. Parenchymal echogenicity was naturally coarse and hypoechoic to the spleen. Vascular and biliary tracts were of normal volume with no evidence of congestion. The gallbladder presented acceptably thin walls with primarily anechoic content. The cystic and common bile ducts were normal. No pathological hepatic lymphadenopathy was evident. No overt structural evidence of inflammatory, infiltrative or regenerative pathology was evident.



**PATIENT**

Jake Feldman

**SPECIES**

Canine

**BREED**

German Shepherd

**SEX**

Neutered male

**AGE**

12 ½ years

**WEIGHT**

89 lbs

**INTERPRETED BY**

Eric Lindquist, DMV  
DABVP, Cert. IVUS

**IMAGING PERFORMED BY**

Dr. Todd

**HOSPITAL NAME**

Lambs Gap AH

**REFERRING VET**

Dr. Todd

**INVOICE**

31906

**DATE**

7/25/22

**Gastrointestinal**

Examination of the **gastrointestinal tract** revealed a stomach and intestine free of stasis, of normal wall thickness, acceptable curvilinear mural detail, and peristaltic activity. Small and large intestine demonstrated normal luminal chyme and stool consistency respectively. No obstructive or overt infiltrative disease was noted. No associated abnormal lymphatic activity was noted.

**Pancreas**

The base and limbs of the **pancreas** were observed to be largely isoechoic to surrounding omental fat. Pancreatic duct and capsular contour were acceptably normal and parenchyma respected normal curvilinear patterns. No overt evidence of active inflammatory or neoplastic disease was noted.

**Free Abdomen**

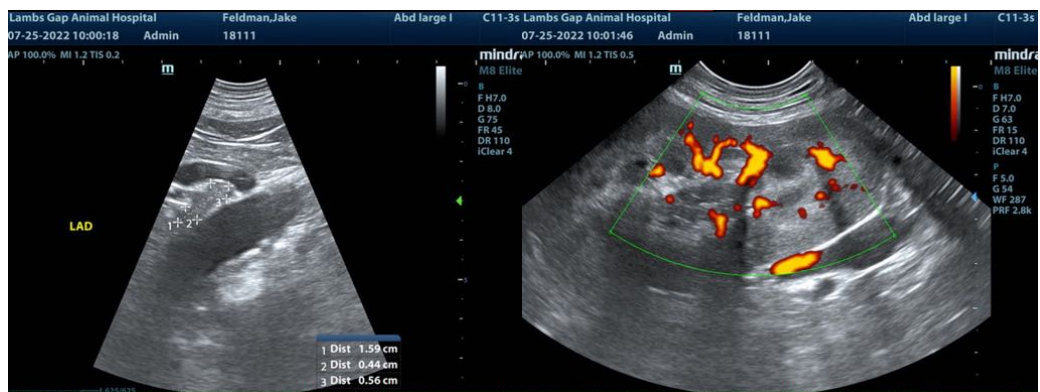
The iliac trifurcation was unremarkable.

**ULTRASONOGRAPHIC FINDINGS**

Unremarkable abdomen.

**INTERPRETATION OF THE FINDINGS & FURTHER RECOMMENDATIONS**

Underlying occult incontinence or occult UTI is possible, yet structurally unremarkable. Orthopedic issues in the lumbosacral or thoracolumbar region may be playing a role regarding pudendal neuropathy eroding bladder control. However, viscerally the abdomen was unremarkable.





**PATIENT**

Jake Feldman

**SPECIES**

Canine

**BREED**

German Shepherd

**SEX**

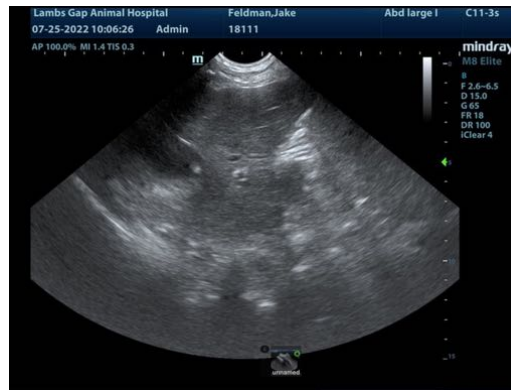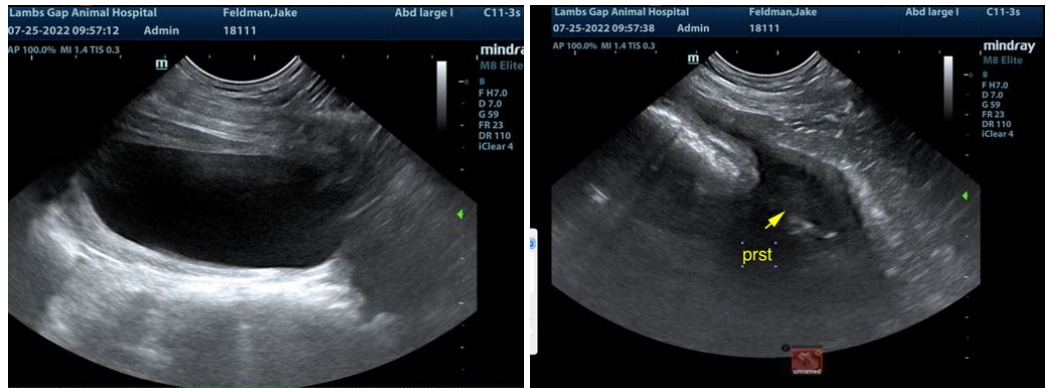
Neutered male

**AGE**

12 ½ years

**WEIGHT**

89 lbs



**INTERPRETED BY**

Eric Lindquist, DMV  
DABVP, Cert. IVUSS

**IMAGING PERFORMED BY**

Dr. Todd

**HOSPITAL NAME**

Lambs Gap AH

**REFERRING VET**

Dr. Todd

**INVOICE**

31906

**DATE**

7/25/22

The information and recommendations provided are based on the images presented by the referring veterinarian/sonographer. No evaluation can be communicated regarding pathology that was not visible in the image/video clips provided.

Thank you for this referral. If the clinical or image interpretation does not parallel your findings or if I can be of any further assistance please contact me.

Eric Lindquist, DMV, DABVP, Cert. IVUSS, CEO of SonoPath.com  
info@SonoPath.com