



**PATIENT**

Alice Crawford

**SPECIES**

Canine

**BREED**

Kuvasz

**SEX**

Spayed Female

**AGE**

12 Years

**WEIGHT**

84.5 Pounds

**INTERPRETED BY**

Eric Lindquist, DMV

DABVP, Cert. IVUSS

**IMAGING PERFORMED BY**

Dr. Harmon

**HOSPITAL NAME**

Willamette VH

**REFERRING VET**

Dr. Harmon

**INVOICE**

39792

**DATE**

7/23/22

**PRESENTING CLINICAL SIGNS**

Diarrhea, peripheral lymphadenopathy, poor appetite Presented 7/22. Not eat 48 hr. Vomit Thursday. Recent camping in the lake. No specific raw fish ingestion. Lives on large property. Has brought several dead fawns home in the last week. T102.3 at presentation.

Abnormal PE/Chem/CBC/UA Results: Fecal direct: no flukes observed CBC: HCT 41.1%, MCV 61.5, Lym 1.03, mpv 15 Chem 17: nsf EPOC: HCT 45%, Bicarb 14.6, Crea 1.57, lac 3.14, pcO2 26.1, pH 7.355, TCO2 14.8, BE -10.9 FAST scan: numerous hypoechoic enlarged lymph nodes, one measured 6.78 cm from caudal to cranial pole, fluid filled colon, spleen/kidneys/liver/gallbladder appear wnl, no free fluid

**ULTRASONOGRAPHIC EXAMINATION OF THE ABDOMEN**

**Urinary System**

The **urinary bladder**, trigone, and pelvic urethra presented normal thicknesses and normal tone. The ureters were not visible which is normal. No uroliths or sediment were visualized and anechoic urine was present. No evidence of inflammatory or neoplastic changes were noted. Ureteral papillae were normal.

The **kidneys** revealed normal size and structure, corticomedullary definition and ratio for this age. The cortices presented largely uniform texture with normal echogenic relationship to liver and spleen. Medullary structure differed distinctly from the cortex and no evidence of pelvic dilation was present. The capsules were acceptably uniform without significant irregularities. The left kidney measured 5.0 cm. The right kidney measured 5.0 cm.

**Adrenal Glands**

The region of the **left adrenal gland** was imaged, no evident pathology.

The **right adrenal gland** was not visualized.

**Spleen**

The **spleen** presented a smooth homogeneous parenchyma hyperechoic to liver and renal cortical parenchyma. The capsule was smooth without noticeable expansion or deviation from within the spleen or adjacent pathology. The splenic vasculature demonstrated normal volume without signs of congestion or thrombosis. No sonographic evidence of acute or chronic inflammatory, neoplastic, or infarctual changes were noted.

**Liver**

The **liver** images submitted revealed subjectively normal liver size, contour, and structure. Parenchymal echogenicity was naturally coarse and hypoechoic to the spleen. Vascular and biliary tracts were of normal volume with no evidence of congestion. The gallbladder presented acceptably thin walls with primarily anechoic content. The cystic and common bile ducts were normal. No pathological hepatic lymphadenopathy was evident. No overt structural evidence of inflammatory, infiltrative or regenerative pathology was evident.

**Gastrointestinal**

Examination of the **gastrointestinal tract** revealed a stomach and intestine free of stasis, of normal wall thickness, acceptable curvilinear mural detail, and peristaltic activity. Small and large intestine demonstrated normal luminal chyme and stool consistency respectively. No obstructive or overt infiltrative disease was noted. No associated abnormal lymphatic activity was noted.



**PATIENT**

Alice Crawford

**Pancreas**

The base and limbs of the **pancreas** were observed to be largely isoechoic to surrounding omental fat. Pancreatic duct and capsular contour were acceptably normal and parenchyma respected normal curvilinear patterns. No overt evidence of active inflammatory or neoplastic disease was noted.

**SPECIES**

Canine

**ULTRASONOGRAPHIC FINDINGS**

- Structurally unremarkable abdomen

**BREED**

Kuvasz

**INTERPRETATION OF THE FINDINGS & FURTHER RECOMMENDATIONS**

No evidence of visceral disease. Given the vague clinical signs, screening for Addison's warranted, especially given that the adrenal glands were not overtly visualized. No evidence of abdominal lymphadenopathy present. Supportive care should prove effective.

**SEX**

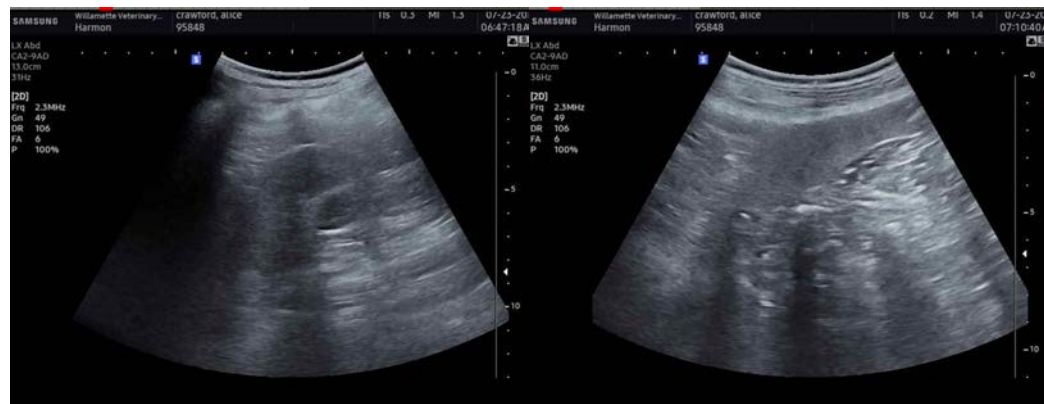Spayed Female

**AGE**

12 Years

**WEIGHT**

84.5 Pounds



**INTERPRETED BY**

Eric Lindquist, DMV

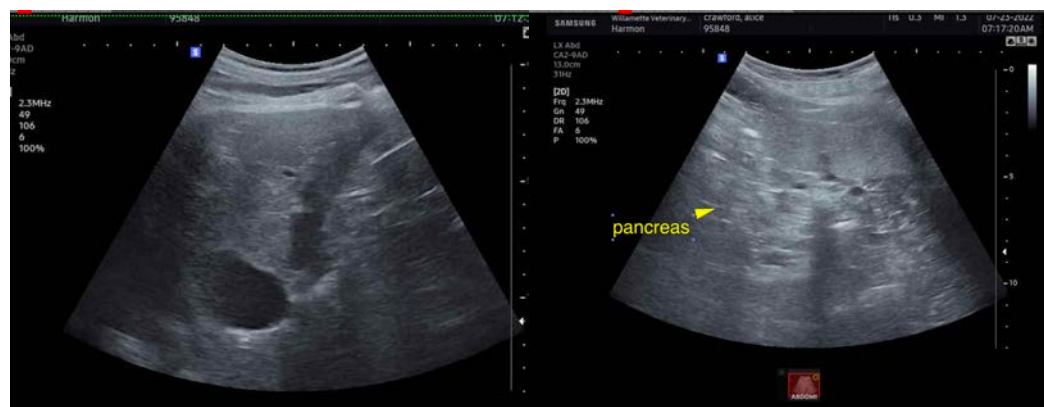
DABVP, Cert. IVUSS

**IMAGING PERFORMED BY**

Dr. Harmon

**HOSPITAL NAME**

Willamette VH



**REFERRING VET**

Dr. Harmon

**INVOICE**

39792

**DATE**

7/23/22



**PATIENT**

Alice Crawford

**SPECIES**

Canine

**BREED**

Kuvasz

**SEX**

Spayed Female

**AGE**

12 Years

**WEIGHT**

84.5 Pounds

**INTERPRETED BY**

Eric Lindquist, DMV

DABVP, Cert. IVUSS

**IMAGING PERFORMED BY**

Dr. Harmon

**HOSPITAL NAME**

Willamette VH

**REFERRING VET**

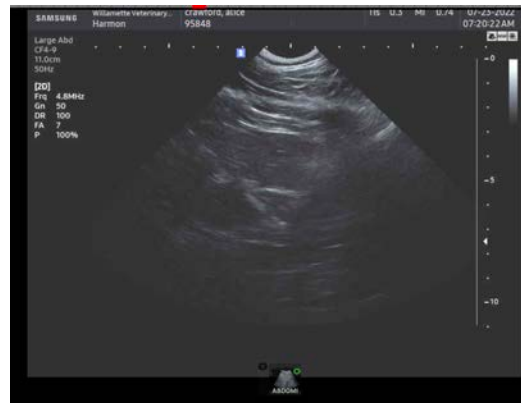Dr. Harmon

**INVOICE**

39792

**DATE**

7/23/22



The information and recommendations provided are based on the images presented by the referring veterinarian/sonographer. No evaluation can be communicated regarding pathology that was not visible in the image/video clips provided.

Thank you for this referral. If the clinical or image interpretation does not parallel your findings or if I can be of any further assistance please contact me.

Eric Lindquist, DMV, DABVP, Cert. IVUSS, CEO of SonoPath.com

[info@SonoPath.com](mailto:info@SonoPath.com)