



PATIENT

Sunny Nafresh

SPECIES

Canine

BREED

Pekingese

SEX

Neutered Male

AGE

13 Years

WEIGHT

18

PRESENTING CLINICAL SIGNS

History: HM first noted in 2020. Echo 2021-mild MV regurg. no LA enlargement. Coughing started over last few weeks along with lethargy and some mild exercise intolerance. Grade 4-5/6 HM, no crackles. HX of seizures /OA (on pheno, deramaxx, gabapentin). Sent home with RX for hydrocodone.

ULTRASONOGRAPHIC EXAMINATION OF THE HEART

CANINE CARDIAC PARAMETERS	MR VMAX (m/s)	TR VMAX (m/s)	LA/AO (Boon method)	LA/AO (Heart Base; Swe)	FS (%)	EF (%)	EPSS (cm)
NORMAL PARAMETER	4.5-5.5	<2.7	1.3	<1.6	28-40	40-100	<0.6
PATIENT	5.8	3.0	NM	1.4	35	--	0.1
CANINE CARDIAC PARAMETERS	HR (BPM)	AV VMAX (m/s)	PV MAX (m/s)	BODY WEIGHT (kg)	LA 2D short axis Base view (cm)	LVIDd Avg; 2D and m-mode short axis (cm)	LVIDs Avg; 2D and m-mode short axis (cm)
NORMAL PARAMETER	50-100	0.7-1.7	0.7-1.6				
PATIENT	--	--	.90	--	3.2	2.3	--

INTERPRETED BY

Eric Lindquist, DMV
DABVP, Cert. IVUSS

IMAGING PERFORMED BY

Dr. Elaina Petrone

HOSPITAL NAME

Long Branch AH

REFERRING VET

Dr. Griffin

INVOICE

23606

DATE

7/22/23

Cardiac Presentation

The echocardiogram in this patient demonstrated normal **left atrial** size based on 3 different LA measurement methods. Chamber volumes and echogenicity were normal. The cranial and caudal **mitral** valve leaflets presented vegetative thickening consistent with endocardiosis. Doppler indicated measurable insufficiency. The **left ventricle** presented thicknesses with linear contour and was not dilated nor restricted. The **myocardium** presented normal echogenicity without subjective evidence of significant fibrotic or ischemic disease. **Contractility** of the ventricular walls was adequate and in normal range for this patient evidenced by the fractional shortening measurement and subjective evaluation of the different regions of the myocardium. The **left ventricular outflow tract** demonstrated normal laminar flow and subjective structural integrity. The **right atrium** and auricle revealed normal size, structure and content. No evidence of masses was noted or chamber overload. Tricuspid insufficiency was noted. The **right ventricle** was of normal size (1/3 diameter of LV), chordae structure, myocardial echogenicity and thickness. **Pulmonic** tract assessment revealed normal valve structure, laminar flow, and diameter (approx.1:1 pa/ao ratio). No visible **pericardial** or free pleura fluid was noted. No echographically detectable evidence of infiltrative disease was visible. The cranial **mediastinum and pericardial regions** were free of masses in the visible window.

ULTRASONOGRAPHIC FINDINGS

- Stage B-1 valvular disease
- Mitral and tricuspid insufficiency



PATIENT

Sunny Nafresh

SPECIES

Canine

BREED

Pekingese

SEX

Neutered Male

AGE

13 Years

WEIGHT

18

INTERPRETED BY

Eric Lindquist, DMV
DABVP, Cert. IVUSS

IMAGING PERFORMED BY

Dr. Elaina Petrone

HOSPITAL NAME

Long Branch AH

REFERRING VET

Dr. Griffin

INVOICE

23606

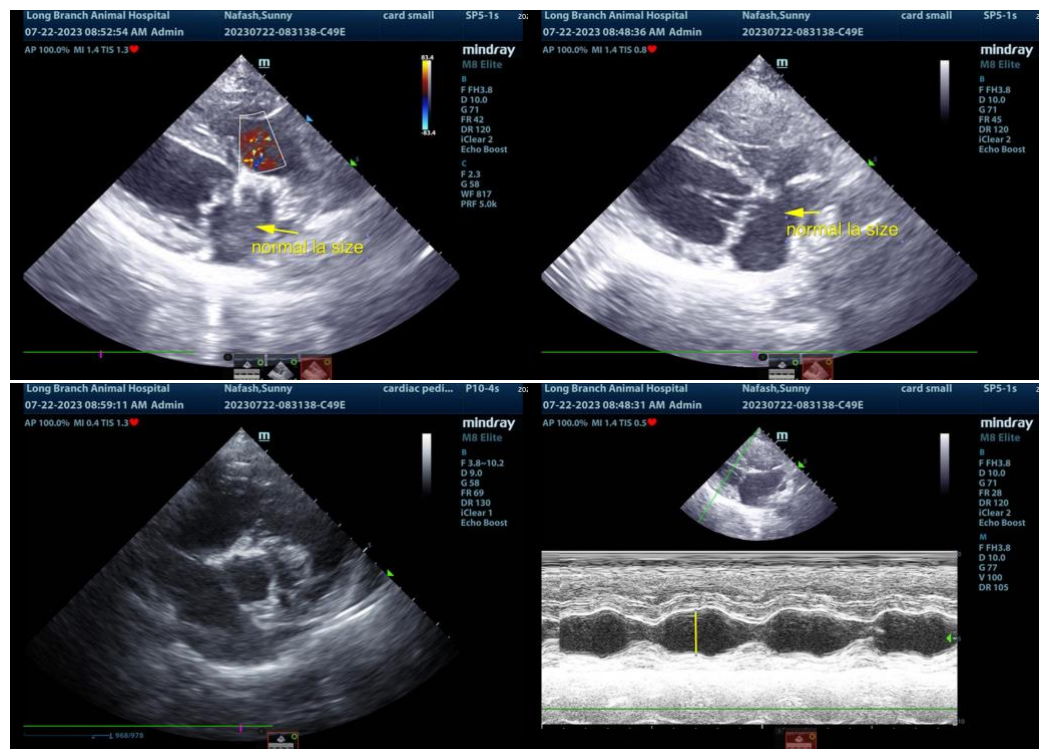
DATE

7/22/23

INTERPRETATION OF THE FINDINGS & FURTHER RECOMMENDATIONS

No evidence of left sided volume overload. The cough is noncardiogenic in this patient. Given the seizure activity, skull CT with contrast is indicated in this patient to rule out underlying primary CNS disease.

The heart is stable without clinical disease. No overt contraindication for anesthesia of brief to moderate duration. I suggest Torbutrol premed, Propofol induction, Isoflor maintenance or similar protocol if anesthesia is desired. Blood pressure recommended if not already performed and target white coat negative systolic pressure of < 160 mmHg. If higher than this ACE-inhibitor is suggested to reach this level. Recheck echocardiogram is recommended in 6 months, earlier if murmur grade increases or clinical signs initiate.





PATIENT

Sunny Nafresh

SPECIES

Canine

BREED

Pekingese

SEX

Neutered Male

AGE

13 Years

WEIGHT

18

INTERPRETED BY

Eric Lindquist, DMV
DABVP, Cert. IVUSS

IMAGING PERFORMED BY

Dr. Elaina Petrone

HOSPITAL NAME

Long Branch AH

REFERRING VET

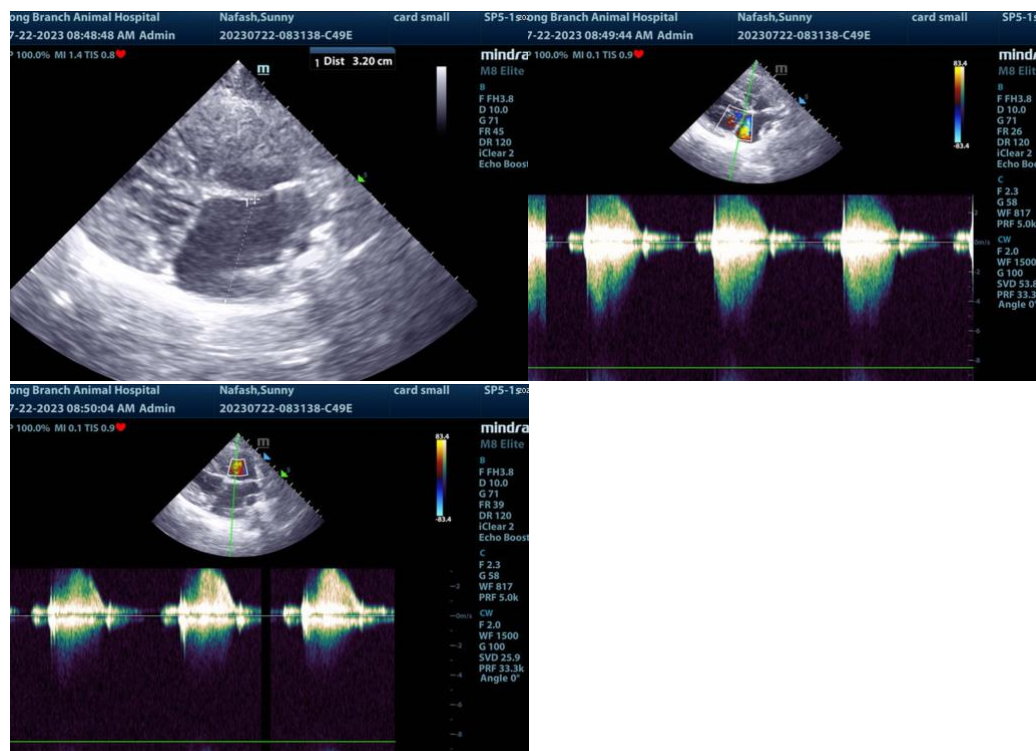
Dr. Griffin

INVOICE

23606

DATE

7/22/23



The information and recommendations provided are based on the images presented by the referring veterinarian. No evaluation can be communicated regarding pathology that was not visible in the image/video clips provided.

Thank you for this referral. If the clinical or image interpretation does not parallel your findings or if I can be of any further assistance please contact me.

Eric Lindquist, DMV, DABVP, Cert. IVUSS, CEO of SonoPath.com
info@SonoPath.com