

PATIENT PRESENTING CLINICAL SIGNS

Ralph Stevens

On June 20, had a few days of vomiting, inappetence and diarrhea. Radiographs unremarkable, bloodwork unremarkable. Was hospitalized on IV fluids for suspected gastroenteritis and resolved within 1-2 days with medical management. Did well at home until July 18 where he started to become inappetent. By July 20th unable to keep anything including water down. 10% dehydration, no diarrhea at this time but anorexic. Cerenia, mirtazipine, buprenorphine, sulcrate

SPECIES

Feline

ULTRASONOGRAPHIC EXAMINATION OF THE ABDOMEN

BREED

DSH

Urinary System

The **urinary bladder**, trigone, and pelvic urethra presented normal thicknesses and normal tone. The ureters were not visible which is normal. No uroliths or sediment were visualized and anechoic urine was present. No evidence of inflammatory or neoplastic changes were noted. Ureteral papillae were normal.

SEX

Neutered Male

The **kidneys** revealed largely normal size and structure, corticomedullary definition and ratio (cortex 1/3 of medulla) were essentially maintained with some age-related loss of curvilinear patterns regarding the capsule and C/M junction. The cortices presented largely uniform texture with some increased echogenicity expected for his age patient. Medullary structure differed distinctly from that of the cortex and no evidence of pelvic dilation was present. The right kidney measured 4.04 cm. The left kidney measured 4.02 cm.

AGE

8 Years

WEIGHT

8 kg

Adrenal Glands

Both **adrenal glands** were visualized and recognized as having normal shape, size, position and echogenicity for this breed. The phrenic vasculature, glandular echogenicity and detail were unremarkable. Capsule, cortex, and medullary definition were normal for this age patient. The left adrenal gland measured 0.35 cm. The right adrenal gland measured 0.40 cm.

INTERPRETED BY

Eric Lindquist, DMV

DABVP, Cert. IVUSS

Spleen

The **spleen** presented a smooth homogeneous parenchyma hyperechoic to liver and renal cortical parenchyma. The capsule was smooth without noticeable expansion or deviation from within the spleen or adjacent pathology. The splenic vasculature demonstrated normal volume without signs of congestion or thrombosis. No sonographic evidence of acute or chronic inflammatory, neoplastic, or infarctual changes were noted.

IMAGING PERFORMED BY

Crystal Hill

HOSPITAL NAME

Dundas AH

Liver

The **liver** images submitted revealed subjectively normal liver size, contour, and structure. Parenchymal echogenicity was naturally coarse and hypoechoic to the spleen. Vascular and biliary tracts were of normal volume with no evidence of congestion. The gallbladder presented acceptably thin walls with primarily anechoic content. The cystic and common bile ducts were normal. No pathological hepatic lymphadenopathy was evident. No overt structural evidence of inflammatory, infiltrative or regenerative pathology was evident.

REFERRING VET

Dr. Kashevska-Gozdek

INVOICE

39776

Gastrointestinal

Examination of the **gastrointestinal tract** revealed a stomach and intestine free of stasis, of normal wall thickness, acceptable curvilinear mural detail, and peristaltic activity. Small and large intestine demonstrated normal luminal chyme and stool consistency respectively. No obstructive or overt infiltrative disease was noted. No associated abnormal lymphatic activity was noted.

DATE

7/22/22



PATIENT *Pancreas*

Ralph Stevens The base and limbs of the **pancreas** were observed to be largely isoechoic to surrounding omental fat. Pancreatic duct and capsular contour were acceptably normal and parenchyma respected normal curvilinear patterns. No overt evidence of active inflammatory or neoplastic disease was noted.

SPECIES
Feline
Free Abdomen

Large amount of abdominal fat noted.

BREED **PRIMARY FINDINGS**

- Age related renal changes
- Large amount of abdominal fat

SEX **INTERPRETATION OF THE FINDINGS & FURTHER RECOMMENDATIONS**

Neutered Male No evidence of significant visceral disease. Dietary indiscretion, food intolerance, structurally insignificant inflammatory bowel or occult parasitism are potentials.

AGE

8 Years

WEIGHT

8 kg

INTERPRETED BY

Eric Lindquist, DMV
DABVP, Cert. IVUSS

IMAGING PERFORMED BY

Crystal Hill

HOSPITAL NAME

Dundas AH

REFERRING VET

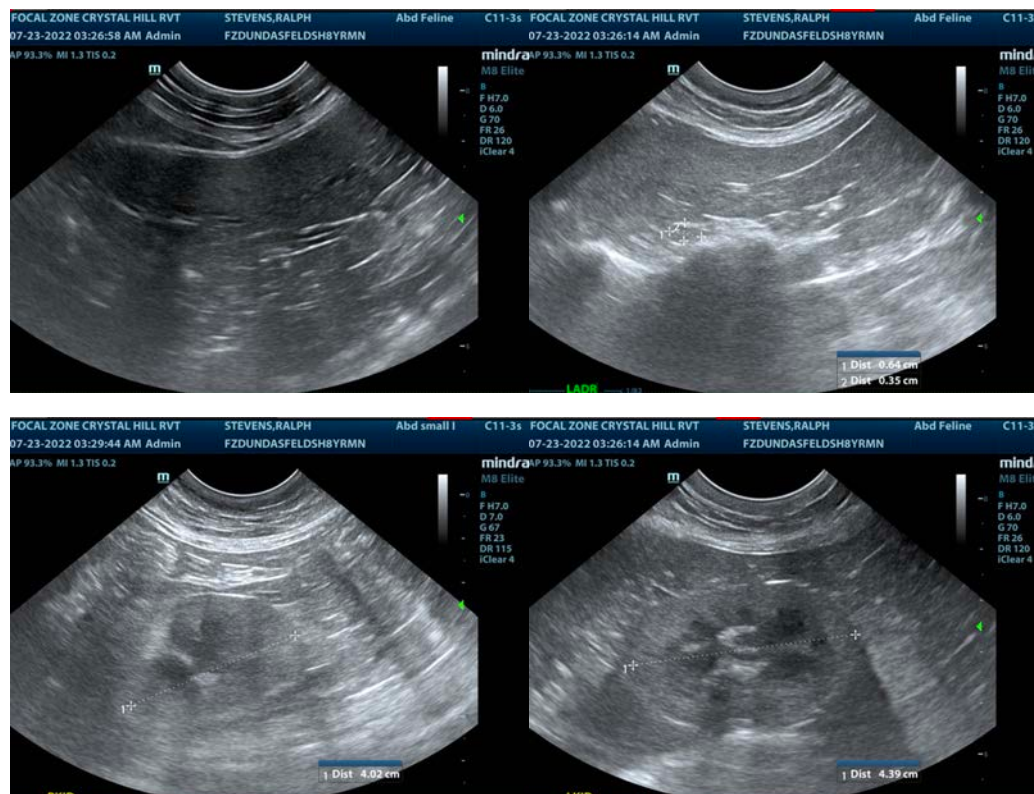
Dr. Kashevsk-Gozdek

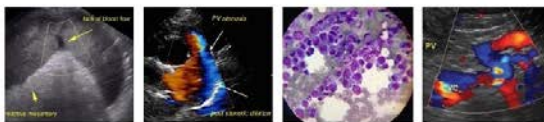
INVOICE

39776

DATE

7/22/22





PATIENT

Ralph Stevens

SPECIES

Feline

BREED

DSH

SEX

Neutered Male

AGE

8 Years

WEIGHT

8 kg

INTERPRETED BY

Eric Lindquist, DMV
DABVP, Cert. IVUSS

**IMAGING
PERFORMED BY**

Crystal Hill

HOSPITAL NAME

Dundas AH

REFERRING VET

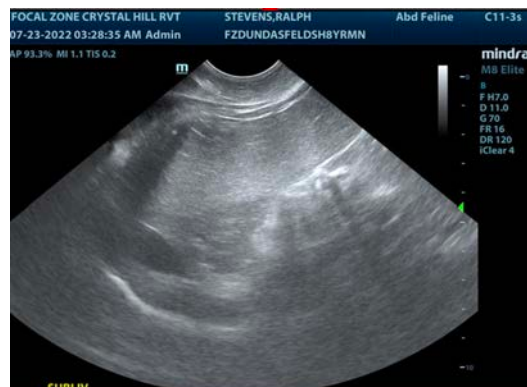Dr. Kashevska-Gozdek

INVOICE

39776

DATE

7/22/22



The information and recommendations provided are based on the images presented by the referring veterinarian/sonographer. No evaluation can be communicated regarding pathology that was not visible in the image/video clips provided.

Thank you for this referral. If the clinical or image interpretation does not parallel your findings or if I can be of any further assistance please contact me.

Eric Lindquist, DMV, DABVP, Cert. IVUSS, CEO of SonoPath.com

info@SonoPath.com